Haryana Vet. (September, 2023) **62(SI-2),** 34-37 ISSN 0033-4359 (P)

Research Article

HISTOLOGICAL INVESTIGATION ON TEAT OF HARIANA CATTLE

ANSHU CHAUHAN[1], BALJINDER BANSAL[1] and NEELAM BANSAL[2]*
[1]Department of Veterinary Medicine, [2]Department of Veterinary Anatomy
Guru Angad Dev Veterinary and Animal Sciences University, Ludhiana-141004, India
Received: 12.09.2022; Accepted: 07.11.2022

ABSTRACT

The present work was undertaken to explore histomorphological and histochemical details of teat in indigenous cattle of Hariana breed. The results revealed that the epidermis projected into the dermis forming the epidermal papillae and rete pegs, which were blunt and flattened at base of teat but elongated and pointed at mid region and tip of teat. The skin at tip region was found to be the thickest followed by mid region and base regions of the teat. The teat skin and teat canal epithelium were lined by stratified squamous keratinized epithelium. The teat skin contained greater number of melanocytes than Langerhans cells, but the teat canal epithelium had Marksaulchen cells which decreased in size and number towards the lumen. The epidermis showed weak to moderate PAS reaction, whereas the dermis showed moderate PAS reaction but a weak PAS-AB and basic protein reactions in both the layers. The teat cistern was made up of double layered cuboidal epithelium and the sub-epithelial stroma consisted of loose connective tissue with smooth muscle fibres, nerve fibres and blood vessels along with accessory lactiferous glands. The lining epithelium of teat cistern and lactiferous glands showed moderate PAS and weak to moderate PAS-AB reactions. However, the reaction of basic protein was strong. The teat sphincter had circular and longitudinally oriented smooth muscle fibres along with large amount of collagen and few elastic and reticular fibres.

Keywords: Histochemistry, Histomorphology, Hariana cattle, Micrometry

How to cite: Chauhan, A., Bansal, B. and Bansal, N. (2023). Histological investigation on teat of Hariana cattle. *Haryana Vet.* **62(SI-2)**: 34-37.

Cattle are extremely important in India's animal husbandry sector, providing livelihood to millions of rural people. Indigenous cattle, which make up roughly 79% of the overall cow population according to the 19th Livestock Census, have 43 recognised breeds dispersed across the country. Hariana is one of the most prominent dual-purpose cow breeds in India, having been bred and raised in the northwest region. With an average milk yield of 997 kg and the maximum recorded milk yield of 1,745 kg, Hariana is the most important cattle breed in Haryana known for their amazing endurance in hot tropical climates, tolerance to tropical diseases, and inexpensive maintenance costs. Hariana breed has recently gained popularity because of presence of the A2 allele in milk, which is thought to be beneficial to human health (Mishra *et al.*, 2009). The present study was conducted in order to observe the basic histoarchitecture of teat in Hariana cattle in order to establish a baseline to detect intramammary infections in them.

MATERIALS AND METHODS

Tissue samples were collected from base, mid and tip of teat from the indigenous Hariana cattle immediately after death. After fixation and routine processing, the paraffin sections of 5-6 µm thickness were stained with haematoxylin and eosin to observe histomorphological details (Luna, 1968). Special stains were used to observe collagen fibres (Masson's trichrome), elastic fibres (Verhoeff's method) and reticular fibres (Gridley's method). Different histochemical moieties were demonstrated by using Periodic Acid Schiff (PAS) and Alcian blue (AB) for neutral mucopolysaccharides and acid mucopolysaccharides, respectively (Sheehan and Hrapchak, 1973), and Bromophenol blue for basic proteins (Chayen *et al.*, 1969). The photomicrographs were taken with digital microscope, and Image J software was used to measure the thickness of teat canal epithelium and teat skin epidermis.

RESULTS AND DISCUSSION

The outer wall of teat was made up skin and the internal duct system was formed from proximal to distal aspect by annular folds, teat cistern, Furstenberg's rosette and teat canal.

Teat skin: The epidermis was consisted of different layers *viz*; stratum corneum, granulosum, spinosum and basale. The epidermis projected into the dermis forming the epidermal pegs which were blunt and flattened at base of teat but elongated and pointed at mid region and tip of teat (Fig. 1A). The dermal papillae projected into the epidermal pegs and which contained connective tissue, blood vessels and nerves in order to provide nutrition and innervation to the epidermis as also reported by Debbarma *et al.* (2017) in the buffalo skin. The epidermal pegs were divided by rete pegs into primary and secondary papillae and were present more at the tip region to provide strength and firmness to teat tip as noticed by Sumena *et al.* (2010) in pigs. Similar findings were observed in the skin of cattle, goat and spotted deer by Nagaraju *et al.* (2012).

The stratum corneum, outermost layer (Fig. 1A), was thickestat tip followed by mid and base of the teat skin

*Corresponding author: bansal.neelam@rediffmail.com

and was strongly eosinophilic with flattened, non-nucleated, keratinized cells as described by Bhattacharya *et al.* (2003) in non-descript buffalo. The stratum granulosum layer was thicker at tip of teat region and contained 1-2 layers of squamous cells which had flat nucleus (Fig. 1A). Keratohyaline granules were present in these cells which produce keratin at the tip and teat canal. These findings are in accordance with Nararaju *et al.* (2012) and Sumena *et al.* (2010) who reported similar observations in buffalo skin. The stratum spinosum had 2-3 layers at base, 4 layers at mid and 6 layers at tip region of teat consisting of polyhedral cells with spherical nucleus which had melanin granules that prevented the ultraviolet rays from penetrating the skin (Fig. 1A). The stratum basale contained large number of brown staining pigmented cells as melanocytes which were more at the tip region (Fig. 1A). Similar findings were reported by Debbarma *et al.* (2017) according to them these cells helped to tolerate high heat, photosensitization and sunburns. Non-pigmented cells in the stratum basale were Langerhans cells with clear cytoplasm and reniform nucleus which were more at tip region and were responsible for the uptake of exogenous antigens that caused teat infections. These cells played role in defence mechanism of teat by acting as antigen detectors.

The micrometrical data revealed that the thickness at tip of teat skin was 453 ± 9.38 µm while at the mid and base was 397.59 µm ± 7.53 and 283.67 ± 5.98 µm, respectively. The tip region was found to be the thickest followed by mid and base regions of the teat. The thickness of teat canal epithelium was 342.53 ± 8.97 µm, while diameter of lumen of teat canal was 976.01± 15.19 µm. Similarly, Kumar (1990) observed the thickness of teat canal in cattle as 327.25 ± 5.91 µm and in buffalo 357.19 ± 4.80 µm.

The dermis was consisted of smooth muscle fibres, blood vessels, nerves and dense irregular connective tissue in the teat skin, however hair follicles, sebaceous and sweat glands were found in base part of teat (Fig. 1A). The epidermis layer showed weak to moderate PAS reaction while PAS-AB and Basic proteins showed weak reaction. The dermis showed moderate PAS but a weak PAS-AB and basic protein reactions.

Internal Duct system: It was comprised of annular fold, teat cistern, Furstenberg's rosette and teat canal.

Annular fold: It was very thick and located at the junction of teat and gland cistern making a clear-cut demarcation between them. The cranial portion of the annular fold was gland cistern lined by single layer of cuboidal epithelium which became double layer at places where as, teat cistern was present caudal to the annular fold and was lined by double layered cuboidal to columnar epithelium. The lining epithelium of annular fold was stratified cuboidal type in present study (Fig. 1B).

Teat cistern: The teat cistern was lined by stratified cuboidal to columnar epithelium. The cistern showed keratinized epithelium along with numerous longitudinal and circular mucosal folding at the base of teat. Double layer stratified squamous epithelium lined the teat cistern in mid part of teat and had more mucosal folding. Similar findings were observed by Paul *et al.* (2013) in teat cistern of desi and crossbred cattle. The greater number of mucosal folds in the teat cistern may be responsible to hold less amount of milk in the teat cistern (Paul *et al.*, 2013). The sub epithelial stroma of teat cistern consisted of loose connective tissue with muscle fibres and blood vessels along with coiled tubular glands called accessory lactiferous glands (Fig. 1B, C, D) which were located in the mid, base and Furstenberg's rosette region of teat cistern. The lining epithelium of teat cistern and lactiferous glands showed moderate PAS and weak to moderate PAS-AB reaction however, the activity of basic protein reaction was strong in teat stroma and weak to moderate in lactiferous glands and teat sinus epithelium (Fig. 1E, F).

Furstenberg's rosette: The Furstenberg's rosette (FR) was present between the junction of teat cistern and teat canal and had 10-14 mucosal folds (Fig. 1C). Similar findings were reported by Patel *et al.* (2007) and Nickerson and Pankey (1983) in FR of bovines. The subepithelial connective tissue contained abundant of collagen fibres with few reticular and elastic fibres , smooth muscle fibres and nerve fibres along with, polymorphonuclear cells (PMN), monocytes, mast cells and plasma cells. The FR region also contained aggregations of lympho-reticular tissue which played an important role in the antibody production by forming a barrier between bacteria and epithelium (Nickerson and Pankey, 1983).

Teat canal: The teat canal was lined by stratified squamous keratinized epithelium which continued proximally as double layered stratified non keratinized type in the FR and teat epidermis distally. The teat canal epithelium consisted of single layer stratum basale, 2-4 layers of stratum spinosum and 7-8 layers of stratus granulosum. Outermost layer was stratum corneum which was keratinized and more prominent in the non lactating animals as it was responsible for the keratin formation (Fig. 2A). Rete ridges (not shown in the figures) were finger like projections arising from teat canal epithelium, which were longer and pointed in non lactating animals but blunt and wider in lactating animals. Vesicular components known as Marksaulchen cells (not shown in

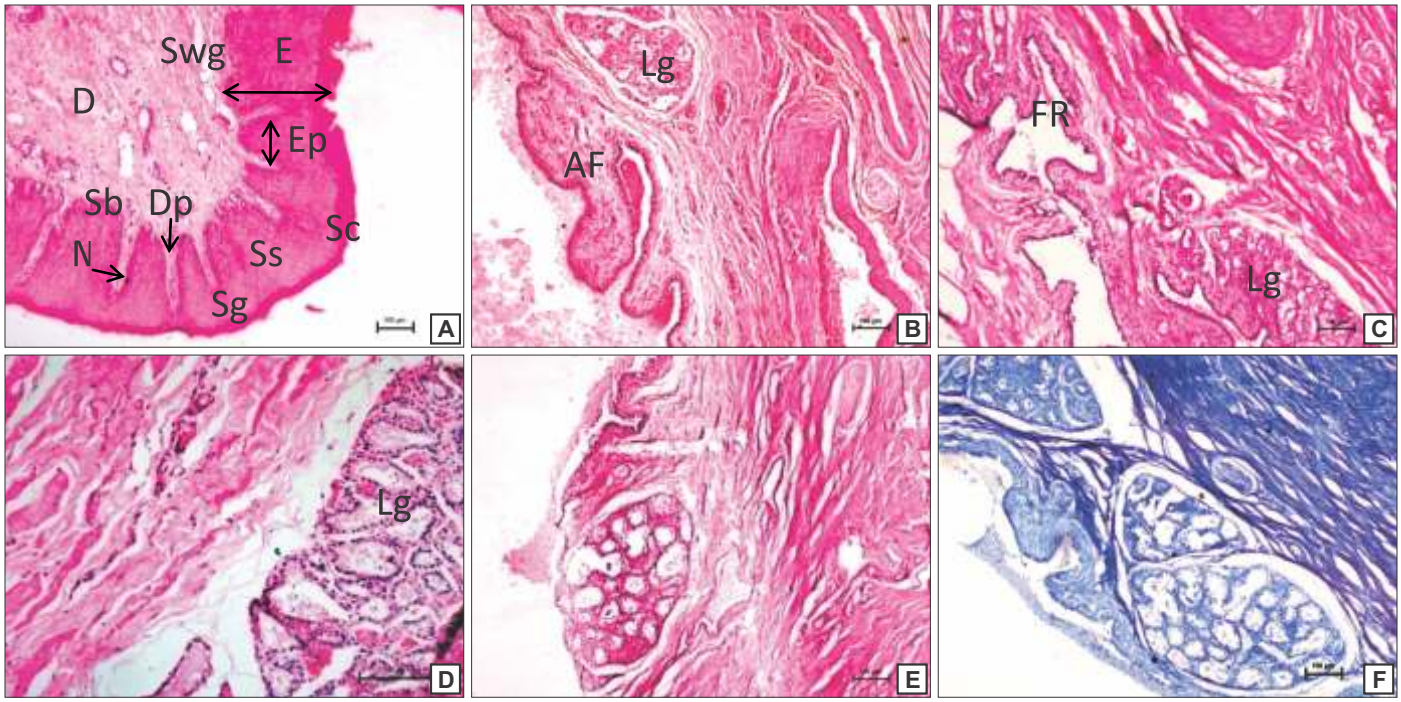

Fig. 1. **(A)** Epidermis (E), Dermis (D), sweat glands (Swg), Epidermal pegs (Ep), Dermal pegs (Dp), Melanocytes (M), Stratum basale (Sb), Stratum spinosum (Ss), Stratum granulosum (Sg), Stratum corneum (Sc) of mid teat skin of Hairana (HR) . Hematoxylin and Eosin X 100: **(B)** Cross-sectional view of base of teat showing thick annular fold (AF) and lactiferous glands (Lg) in HR. Hematoxylin and Eosin X 100; **(C)** Furstenberg's rosette (FR) and lactiferous glands (Lg) in HR. Hematoxylin and Eosin X 100; **(D)** Lactiferous glands (Lg) of HR. Hematoxylin and Eosin X 200; **(E)** Neutral mucopolysaccharides in Lactiferous glands in HR. Periodic acid Schiff X 100; **(F)** Basic protein in lactiferous glands of HR. Bromophenol blue X 100

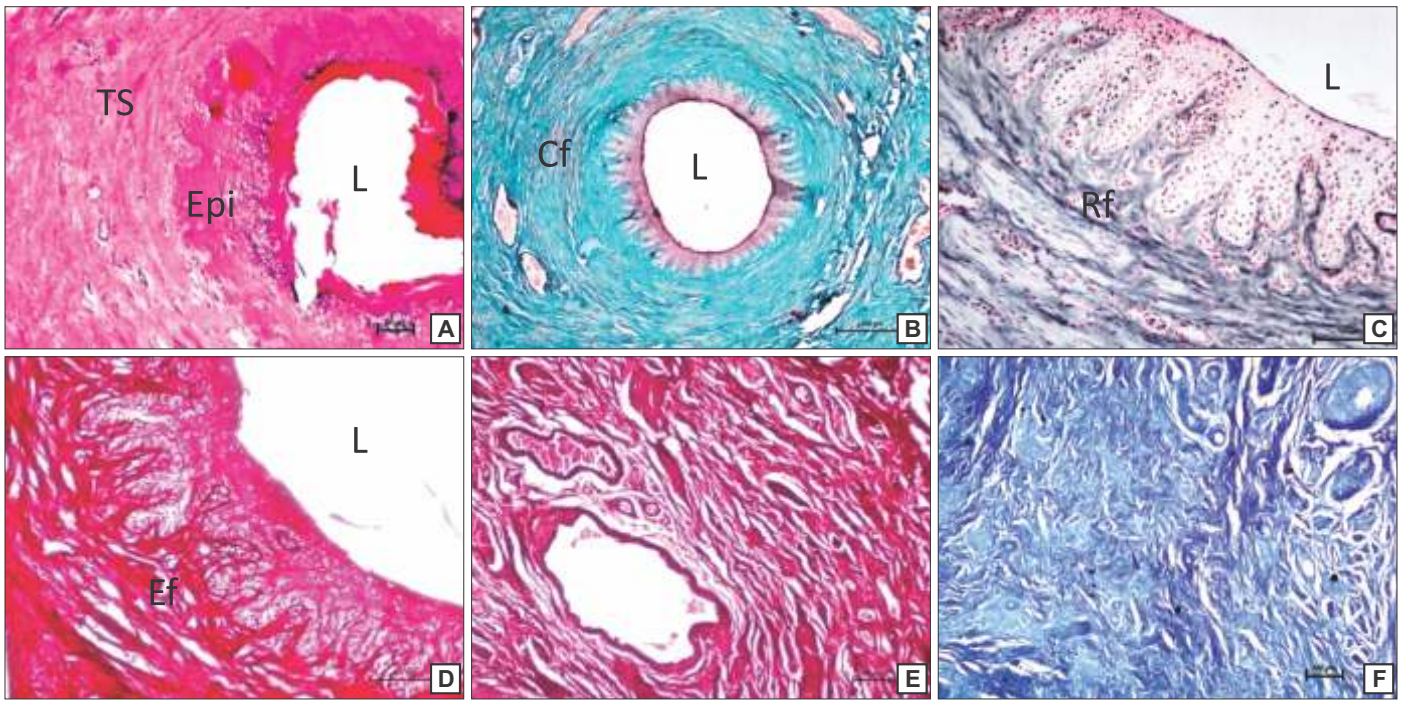

Fig. 2. **(A)** Teat canal of HR showing teat canal lumen (L), epithelium (Epi), teat sphincter(TS). Hematoxylin and Eosin X 100; **(B)** Teat canal (L), Collagen fibers (Cf) in HR.Masson's trichrome X 40; **(C)** Reticular fibers in teat canal epithelium and sphincter of HR. Gridley's X 200; **(D)** Elastic fibers (Ef) in teat canal epithelium and sphincter of HR. Verhoeff"s X 100; **(E)** Elastic fibers in blood vessels of teat stroma of HR. Verhoeff"s X 200; **(F)** Basic protein in teat stroma of HR. Bromophenol blue X 100

figures) were present in teat canal epithelium whose size and number decreased towards the lumen of teat canal and were more in the lactating cows than non-lactating ones. The teat canal epithelium showed weak to moderate PAS and Basic protein activity while the PAS AB reaction was negligible to weak. The basement membrane showed strong reaction for PAS AB. The thickness of the teat canal epithelium was 342.53 ± 8.97 µm in Hariana cows.

Alsodany *et al.* (2019) had reported that the cross bred cows had thicker teat canal epithelium than the Jenubi cows and this could be responsible for the improved milk production and quality in crossbred cows. The luminal diameter of teat canal was 976.01± 15.19 µm.

The sub epithelial portion was fibromuscular type contained smooth muscle fibres, abundant collagen fibres with few reticular and elastic fibres (Fig. 2B, C, D). Large number of blood vessel and nerves helped in tight closure of teat canal thereby lowering risk of intra mammary infections. The nerve bundles in increased number at the mid and tip regions was responsible for hormonal-nerve stimulation during suckling and milking of the animal (Ferdowsi *et al.*, 2017). The teat sphincter had circular and longitudinally oriented smooth muscle fibres along with more elastic fibres compared to collagen and reticular fibres (Fig. 2D, 2E), indicated its musculo-elastic nature. Van der Merwe, (1985) explained that the elastic fibres caused passive closure of teat canal while smooth muscle fibres were responsible for contractile action. The teat stroma showed moderate PAS, PAS-AB and Bronophenol bene reaction but the reactions were stronger in teat sphincter (Fig. 2F).

It was concluded that maximum thickness of epidermis at tip of teat plays an important role in defence mechanism of teat. The highly keratinized stratum corneum of teat canal in the non-lactating animals may be responsible for the formation of keratin plug.

REFERENCES

Alsodany, A., Alderawi, K. and Mraisel, A. (2019). Comparative histological study of skin in Jenubi and its crossbreed cow. *J. Physics: Conf. Series.* **1234(1)**: 12067.

Bhattacharya, M., Sheikh, I.U. and Rajkhowa J. (2003). Epidermal thickness in the skin of Yak (*Poephagus poephagus*). *Indian J. Vet. Anat.* **15**: 73-76.

Chayen, J., Bitensky, L., Butcher, R.G. and Poulter, L.W. (1969). A guide to practical histochemistry. Oliver and Boyd, Edinburgh, England, pp. 83-174.

Debbarma, D., Uppal, V., Bansal, N. and Gupta, A. (2017). Regional variation in architecture of epidermis and dermis of buffalo skin. *Ruminant Sci.* **6(1)**: 31-37.

Ferdowsi, H., AdibMoradi, M. and Asadi, M. (2017). Histological study on the sensory receptors of the teat skin in Sarabi cattle. *Medbiotech J.* **1(04)**: 172-174.

Kumar, S. (1990). Studies on mastitis in buffaloes with emphasis on resistance, chemotherapy and control. M.V.Sc. thesis submitted to Punjab Agricultural University, Ludhiana, India.

Luna, L.G. (1968). Manual of histological staining methods of armed forces institute of pathology. (3rd Edn.), McGraw Hill Book Company, New York, USA, pp. 38-196.

Mishra, B.P., Mukesh, M., Prakash, B., Monika, S., Kapila, R. and Kishore, A. (2009). Status of milk protein, b-casein variants among Indian milch animals. *Indian J. Anim. Sci.* **79**: 72-75.

Nagaraju, G.N., Prasad, R.V., Jamuna, K.V. and Ramkrishna, V. (2012). Histomorphological features in the differentiation of skin of Spotted Deer (*Axis axis*), Cattle (*Bos indicus*) and Goat (*Capra hircus*). *Indian J. Vet. Anat.* **24**: 10-12.

Nickerson, S.C. and Pankey, J.W. (1983). Cytologic observations on the bovine teat end. *American J. Vet. Res.* **44**: 1433-1441.

Patel, A.K., Koringa, P.G., Nandasana, K.N., Ramani, U.V. and Panchal, K.M. (2007). Comparative histology of mammary gland in heifer, pregnant, lactating and dry buffaloes. *Indian J. Vet. Anat.* **19**: 71-78.

Paul, S., Das, P. and Ghosh, R.K. (2013). Comparative cellular structure of udder and teat of desi and crossbred cows in reference to mammary gland immunity. *Indian J. Vet. Anat.* **25(1)**: 71-73.

Sheehan, D.C. and Hrapchak, B.B. (1973). Theory and practice of histochemistry. The C V Mosby Co., Saint Louis. pp. 79-115.

Sumena, K.B., Lucy, K.M., Chungath, J.J., Ashok, N. and Harshan, K.R. (2010). Morphology of the skin in Large White Yorkshire pigs. *Indian J. Anim. Res.* **44(1)**: 55-57.

Van der Merwe, N.J. (1985). Some observations on the morphology of the bovine teat canal (*Ductus papillaris mammae*). *J.S. Afr. Vet. Assoc.* **56(1)**: 13-16.