

INTERMITTENT HEMODIALYSIS FOR THE MANAGEMENT OF STAGE IV CHRONIC KIDNEY DISEASE IN A DOG

RANDHIR SINGH*, DHEERAJ KUMAR GUPTA¹, CHARANJIT SINGH¹ and SANJEEV KUMAR UPPAL²

Department of Teaching Veterinary Clinical Complex, ¹Department of Veterinary Medicine,

²Dean Post Graduate Studies, Guru Angad Dev Veterinary and Animal Sciences University, Ludhiana-141 004, Punjab, INDIA

Received: 08.12.2022; Accepted: 12.04.2023

SUMMARY

A five years old Akita breed dog with history of anorexia, emesis, lethargy and halitosis was presented in Medicine Emergency Unit of Multispecialty Veterinary Hospital, Guru Angad Dev Veterinary and Animal Sciences University, Ludhiana, Punjab. The hemato-biochemical profile of dog revealed stage IV chronic kidney disease (CKD). As the dog had been treated at a local clinic from last four days without any improvement, intermittent hemodialysis (IHD) was selected as treatment of choice. After three sessions of IHD, the dog showed marked improvement in general condition with reduction in uremia and correction of electrolyte imbalance.

How to cite: Singh, R., Gupta, D.K., Singh, C. and Uppal, S.K. (2023). Intermittent hemodialysis for the management of stage IV chronic kidney disease in a dog. *The Haryana Veterinarian* 62(SI-2): 171-173.

Chronic kidney disease, describes the gradual loss of kidney function. Generally, kidneys filter the wastes and excess fluids from the dogs' blood, which are then excreted in urine. When CKD reaches an advanced stage, dangerous levels of fluid, electrolytes and wastes can build up in the body. Being a progressive disease that causes functional alterations in the renal parenchyma, CKD can further progress to renal failure (Polzin, 2011). CKD is now a days widely diagnosed disease in small animal internal medicine practice with high comorbidity and mortality rates. The prevalence is reported to be 0.5-1.0 per cent in the canines and 1.0-3.0 per cent in the felines (Roura, 2018). Canine patients with CKD in stage III have moderate azotemia with serum creatinine of 2.1-5.0 mg/dl, and its clinical manifestations at this stage are more pronounced, requiring round the clock monitoring and patient care (Polzin, 2011). The dogs in stage IV with serum creatinine >5.0 mg/dl are at increasing risk of systemic clinical signs and severe uremic crisis.

Intermittent hemodialysis is an extracorporeal renal replacement therapy that involves repeated short hemodialysis sessions over a period of time (Bloom & Labato, 2011) with the aims to strike balance between the patient metabolic profile and homeostasis that otherwise would likely succumb due to the pansystemic ramifications of severe uremia (Cowgill and Francey, 2012; Fischer et al., 2004). The primary goal of IHD in dogs with CKD is to improve the chronic progressive azotemia, correct the acid-base, fluid, and electrolyte imbalances along with removal of nitrogenous compounds and other toxins (Cowgill and Francey, 2012; Cowgill, 2011; Bloom and Labato, 2011). The prognosis and

therapy time for IHD in Veterinary practice differ for each patient depending upon the severity of underlying cause, degree of renal injury, and presence of comorbidities (Fischer et al., 2004). The aim of present study was to evaluate the usefulness of intermittent hemodialysis in the management of stage IV CKD in a dog refractory to standard treatment.

A 5 years old male Akita breed dog weighing 42 Kg was presented at Medicine Emergency Unit of Multispecialty Veterinary Hospital, Guru Angad Dev Veterinary and Animal Sciences University, Ludhiana, Punjab with history of anorexia, vomiting (10-12 episodes/day), dark yellow urine and bleeding intermittently from mouth from past six days. Previously, from past four days the dog had been on prescription medicine from a private veterinary practitioner which included normal saline solution, dextrose normal saline, furosemide and ondansetron at the standard doses. On clinical evaluation, the dog was dull having congested mucous membranes and normal sized external lymph nodes. The vital parameters (rectal temperature 102 °F, heart rate- 120 bpm, respiration rate-32 breaths/minute) and blood pressure (165 mmHg) were altered. Oral examination revealed few bleeding ulcers with halitosis. Previous biochemical profile of dog (4 days before presentation) revealed severe azotemia (BUN- 312 mg/ dl, creatinine- 24.46 mg/dl) and hyperphosphotemia (16.9 mg/dl) and normal ALT levels (38 u/L). On the day of presentation, blood, urine and serum samples were again taken from the dog for evaluation of complete blood count, urine specific gravity and biochemical profile including alanine transaminase (ALT), gamma-glutamyl transferase (GGT), total protein (TP), albumin, blood urea nitrogen

*Corresponding author: dr.randhirlo@gmail.com

Table 1. Hemato-biochemical profile of the dog undergoing intermittent Hemodialysis (IHD)

Parameter	IHD Session I (session time: 40 minutes)		IHD Session II (session time: 3 Hours)		IHD Session III (session time: 3 Hours)	
	Pre-Session	Post-Session	Pre-Session	Post-Session	Pre-Session	Post-Session
Hb (g/dL)	10	9.0	9.1	10.90	10.1	11
TLC	14,450	12,960	15,720	15,430	8,930	13,400
ALT(U/L)	62	91	110	114	112	102
GGT(U/L)	29	41	44	34	84	46
T. Protein (g/dL)	5	6.0	5.9	5.30	6.2	7.2
Albumin (g/dL)	2.4	2.6	2.7	1.80	2.7	4.06
BUN (mg/dL)	200	132	155	71.87	85	24
Creatinine (mg/dL)	24.5	18	19	10.61	10.1	1.24
Phosphorus (mg/dL)	24	16.6	19.6	8.20	13.4	4.6
Sodium (mEq/L)	132	130	127	146	129	137
Potassium (mEq/L)	7.6	6.5	5.8	3.96	5.8	4.5
Chloride (mEq/dL)	108	106	102	106.40	101	95
Calcium (mg/dL)	8.7	9.2	8.2	8.70	9.1	8.2
Glucose (mg/dL)	100	64	88	61	80	68

Ultrafiltration Goal (UF Goal):- Session I: 100ml; Session II: 500 ml & Session III: 700 ml

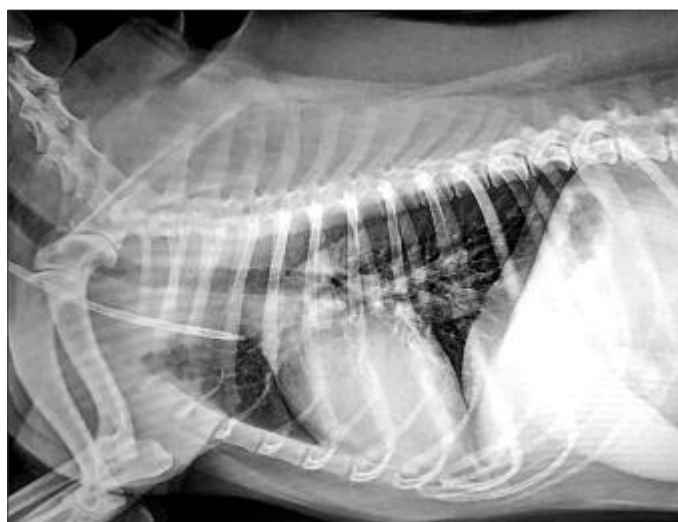


Fig. 1. Correct placement of double lumen catheter tip at the junction of cranial vena cava and right atrium

(BUN), sodium (Na), potassium (K), chloride (Cl) and calcium (Ca). Radiograph of the chest (lateral and ventrodorsal views) and ultrasonography of abdomen was also carried out.

The hemato-biochemical results are presented in first column of table 1. The main findings were absolute neutrophilia with majority being mature neutrophils, severe azotemia, hyperphosphotemia, hyperkalemia and hypoproteinemia. Urine specific gravity was 1.010. The radiograph of chest revealed heart in about three intercostal spaces with severe intestinal pattern in both the lungs. Abdominal ultrasound showed enlarged and congested liver with uniform echotexture, enlarged and congested spleen, hyperechoic renal cortex with moderate loss of cortico-medullary differentiation of the kidneys, lot

of sludge in the urinary bladder, normal pancreas and adrenal glands and lot of free fluid in abdomen. Based on the above findings the case was diagnosed and treated as CKD stage IV (IRIS, 2019). As the health of dog was progressively deteriorating even when on prescription medicine from last four days, IHD was considered as treatment of choice. Three IHD sessions were performed on alternate days with Fresenius 4008S machine, using jugular catheterization with 11.5 French, 19 cms double lumen catheter so that the tip of catheter could be placed at the junction of cranial vena cava and right atrium (Fig. 1). Fresenius Fx 8 dialyzer having surface area of 1.4 m², the dialysate K concentration was adjusted to 3.5 mEq/L whereas base and prescribed Na levels were kept at 142 mEq/L. The hemato-biochemical profile was carried out before (Pre-session) and after end (Post-session) of each IHD session. Table 1 reveals significant reduction in BUN, creatinine, phosphorus and proteins along with correction of electrolyte imbalance after end of each IHD session. There was also marked clinical improvement in general condition of the dog with return of normal appetite, complete cessation of emesis and normal physical activity.

In veterinary medicine, canine renal failure due to acute kidney injury or CKD occurs relatively frequently, with majority of causes similar to those in man. Being a widely used renal replacement therapy, IHD provides a link to achieve desired metabolic stability to both human and veterinary patients who would otherwise succumb to pansystemic ramifications of severe uremia (Fischer et al., 2004). The present case was selected for IHD due to severe refractory uremia. Initially, the first IHD session

was deliberately kept less intense owing to severe uremia to avoid sudden hemodynamic changes leading to major fluid shift. The dialyzer was selected on the basis of dogs' body weight (Cowgill, 2011) keeping a balance between effective surface area and priming volume. With each session there was significant improvement with reduction in levels of BUN, creatinine, phosphorus along with correction of electrolyte imbalances. At the end of third IHD session all the biochemical parameters returned to normal physiological levels. The dog was hypertensive on the day of presentation which may be related to increased production of angiotensin II, reduced prostaglandins and impaired nitric oxide synthesis (Cowgill & Francey, 2012). Antihypertensive treatment with ACEI (@ 0.25mg/kg once a day orally) was initiated and proved beneficial in lowering the hypertension (post session I: 165 mmHg; post session II: 155 mmHg; post session III: 155 mmHg). Anemia is a common complication in dogs suffering from CKD due to erythropoietin and iron deficiency (Falco *et al.*, 2013). Although, in present study the Hb level ranged from 9-11gm/dL but still the levels were below the normal reference range of 12-19g/dL (The Merck Veterinary Manual, 10th Edition). After end of first IHD session the dog appeared duller and fatigued with no inclination to stand or move. It may be due to the fact that the dialysate used during IHD was dextrose free and due to which the circulating glucose levels also declined by > 20g/dL after end of 1st and 2nd session. Apart from this, various other factors may also contribute towards development of post dialysis fatigue which may include uremia, anemia and oxidative stress (Jhamb *et al.*, 2008). This post dialysis fatigue due to hypoglycemia was managed with intra venous infusion of 500 ml of 5 per cent dextrose. After three IHD sessions the dog recovered with clearance of uremic toxins and correction of electrolyte imbalance manifested by improved physical activity and cessation of emesis. Lot of free fluid was present in abdomen which may be contributed to concurrent hepatic insufficiency as depicted by elevated hepatic enzymes and ultrasound findings. Further, reduced levels of total protein and albumin in present study may be attributed to the reduced synthesis and an increased degradation of albumin along with malnutrition owing to anorexia from past six days. The dog was kept on oral medications like L-carnitine @ 2gm (total dose) once a day as serum-free carnitine is removed from body during hemodialysis

treatment due to small molecular weight of carnitine (161 Da) and its protein binding rates are very low, enalapril @ 0.25mg/kg once a day for the management of hypertension, furosemide @ 2mg/kg twice a day as a loop diuretic for managing uremia, ranitidine @ 0.5 mg/kg once a day for controlling uremic gastritis and B-complex supplementation for next one week. As per the telephonic feedback from the owner, there was improvement in overall condition of the dog but had reduced appetite. The owner was prescribed appetite stimulating syrup containing buclizine hydrochloride which improved the appetite of dog after five days of supplementation.

Although, IHD involves more risks due to invasive procedures than standard treatment with medicines and fluid therapy, a well-trained veterinarian can reduce these associated risks. No major complication was encountered during IHD sessions indicating safety of IHD for dogs with CKD.

REFERENCES

- Polzin, D.J. (2011). Chronic kidney disease in small animals. *Vet. Clin. Small Anim.* **41**: 15-30.
- Roura, X. (2018). Risk factors in dogs and cats for development of chronic kidney disease. Disponível em: http://www.iris-kidney.com/education/risk_factors.html. Acesso em 8 de Fevereiro de.
- Cowgill, L.D. (2011). Urea kinetics and intermittent dialysis prescription in small animals. *Vet. Clin. Small Anim.* **41**: 193-225.
- Fischer, J.R., Pantaleo, V., Francey, T. and Cowgill, L.D. (2004). Veterinary hemodialysis: advances in management and technology. *Vet. Clin. Small Anim.* **34**: 935-967.
- Cowgill, L.D. and Francey, T. (2012). Hemodialysis and extracorporeal blood purification. In: DiBartola SP, editor. *Fluid, Electrolyte, and Acid-Base Disorders in Small Animal Practice*, (4th Edn.), Philadelphia: Elsevier; pp. 680-713.
- Bloom, C.A. and Labato, M.A. (2011). Intermittent hemodialysis for small animals. *Vet. Clin. Small Anim.* **41**: 115-133.
- IRIS staging of CKD (modified 2019), International Renal Interest Society (IRIS) Ltd.
- Falco, S. (2013). Thromboelasto-metry used for evaluation of blood coagulability in dogs with kidney diseases. *Acta. Veter. Brno.* **82**: 209-214.
- Jhamb, M., Weisbord, S.D., Steel, J.L. and Unruh, M. (2008). Fatigue in patients receiving maintenance dialysis: a review of definitions, measures, and contributing factors. *Am. J. Kidney Dis.* **52**(2): 353-65.
- The Merck Veterinary Manual, (10th Edn.) (2010). Hematological reference ranges. Merck & Co., Inc., N.J., U.S.A. pp. 2824-25.