

SUCCESSFUL SURGICAL MANAGEMENT OF TRACHEAL RUPTURE DUE TO DOG BITE IN A NON-DESCRIPT DOG

POTHANA VARSHINI*, P. SANKAR, BODASAIKUMAR, S. KATHIRVEL, S. DHARMACEELAN and A. KUMARESAN
Department of Veterinary Surgery and Radiology, Veterinary College and Research Institute, Namakkal-637 002
TANUVAS, Tamil Nadu-637 002, India

Received: 27.09.2022; Accepted: 25.02.2023

SUMMARY

A seven-year-old, non-descript male dog was presented with progressive subcutaneous emphysema and dyspnoea following a dog bite. On clinical examination, punctured wound was noticed at the ventral aspect of neck with escape of air from it. Radiography revealed discontinuity in the tracheal ring. The condition was diagnosed as tracheal rupture and was subjected to surgical intervention. The ruptured trachea was successfully reconstructed after endotracheal intubation. The dog recovered uneventfully without any evidence of stenosis or collapse of trachea.

Keywords: Dog, Subcutaneous emphysema, Trachea rupture

How to cite: Varshini, P., Sankar, P., Saikumar, B., Kathirvel, S., Dharmaceelan, S. and Kumaresan, A. (2023). Successful surgical management of tracheal rupture due to dog bite in a non-descript dog. *The Haryana Veterinarian* 62(SI-2): 155-156.

Tracheal injuries are from bites, choke chain, gunshot injuries (Kellagher and White, 1987) and as a complication of endotracheal intubation (Kastner *et al.*, 2004; Roach and Krahwinkel, 2009) in dogs. Due to the proximity of vital structures, cervical bite wounds are associated with significant injury to them (Jordan *et al.*, 2013) and can lead to laryngeal paralysis, laryngeal avulsion, tracheal tear, oesophageal tear, and other conditions, which may be life-threatening (Picavet *et al.*, 2022). The purpose of this study was to report the etiology, clinical presentation, surgical findings and follow-up outcome of a dog treated for trachea rupture due to dog bite.

A seven-year-old non-descript male dog, weighing 15.3 kg was presented to Veterinary Clinical Complex, Veterinary College and Research Institute, Namakkal. Anamnesis revealed that the dog had progressive subcutaneous emphysema and dyspnoea following a dog bite before two days. The dog was mostly standing with abducted hind limbs and lowered neck with unsatisfactory food and water intake (Fig. 1).

The dog had congested mucous membrane and rectal temperature of 39.3 °C. The heart rate and respiratory rate were 100 and 60 per minute, respectively. On clinical examination, a puncture wound was noticed on ventral aspect of neck with escape of air from it. The crepitus was palpated all over the dorsal body (Fig. 2). Auscultation revealed respiratory stridor. The radiographic examination revealed a rupture in the cervical region of the trachea and free air in subcutaneous space (Fig. 3). Based on the clinical findings and radiographic evaluation the case was diagnosed as traumatic rupture of trachea and was opined for tracheal reconstruction.

Prior to the surgical intervention, three stab incisions were given over the body in the subcutaneous space for the emergency exit of air. The dog was stabilized with intravenous administration of Ringer's lactate solution, inj. Ceftriaxone Sodium @ 20 mg/kg body weight im. and inj. Tramadol @ 2 mg/kg b wt. im. The ventral aspect of neck was aseptically prepared for surgery.

The dog was pre-anaesthetized with inj. Atropine sulphate @ 0.04 mg/kg subcutaneously followed by inj. Xylazine @ 1 mg/kg intramuscularly at a gap of 15 minutes. Endotracheal tube was intubated (Fig. 4) after inducing with inj. Ketamine @ 5 mg/kg and inj. Diazepam @ 0.05 mg/kg intravenously. The anaesthesia was maintained by half the dose of ketamine and diazepam used for induction.

The dog was placed in dorsal recumbency with the neck extended. The skin was incised on ventral aspect of neck on the wound area followed by subcutaneous tissue and muscles to expose ruptured trachea. Soft-tissue debridement was performed and then the ruptured tracheal rings were sutured together by simple interrupted suture pattern with synthetic absorbable suture material (1/0, Polyglycolic acid) (Fig. 5). The muscles, subcutaneous tissue, and skin were closed routinely. Postoperatively, the animal was treated with Inj. Ceftriaxone @ 20 mg/kg SID for 5 days, Inj. Tramadol @ 2 mg/kg SID for 2 days and the cutaneous wound was dressed with 5% povidone iodine solution until suture removal. The dog had completely recovered after 10 days of surgery without any recurrence (Fig. 6) or necrosis. Gradual reduction in generalized subcutaneous oedema was noticed by postoperative day 5. The case was further followed for 5 months and did not report any evidence of tracheal stenosis or collapse.

Bite wounds are common injuries in dogs

*Corresponding author: varshinipothana56@gmail.com

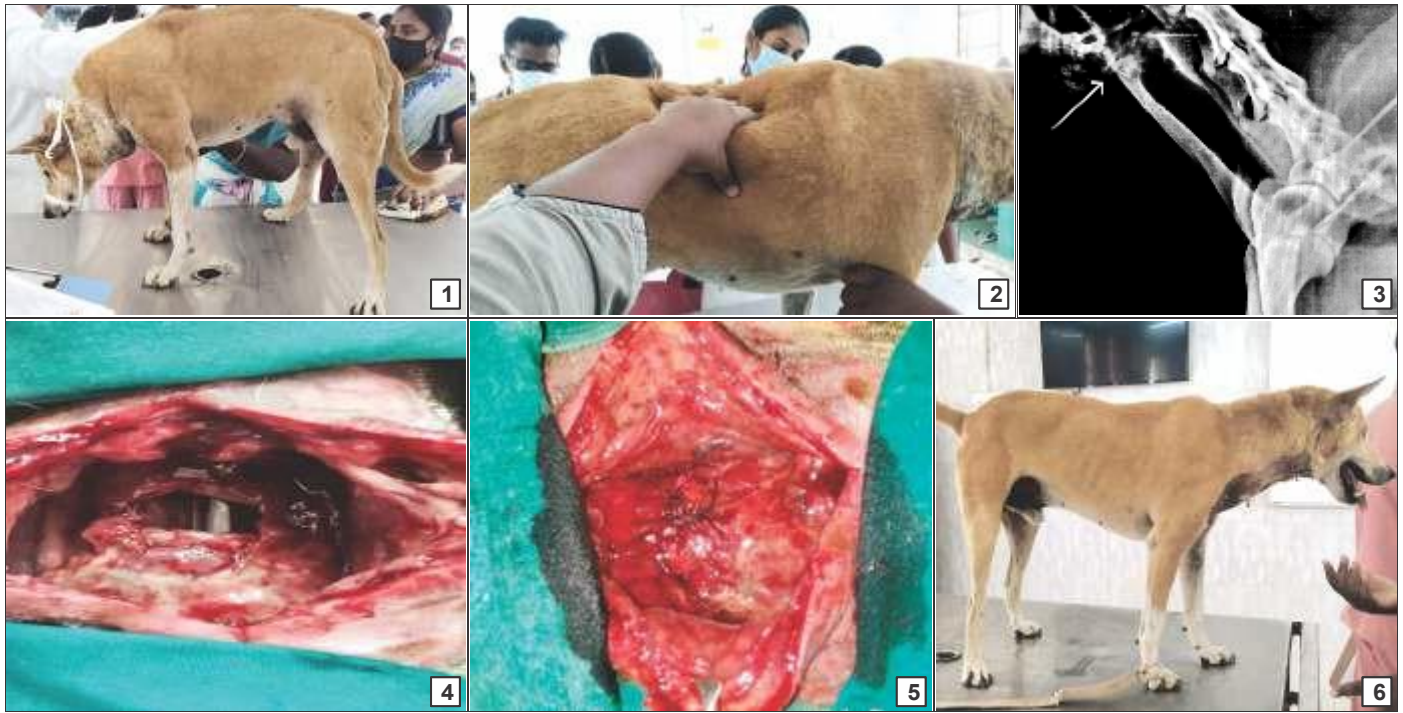


Fig. 1-6. (1) Abducted hind limbs and lowered neck; (2) Subcutaneous emphysema with crepitus; (3) Radiograph showing the rent; (4) Endotracheal tube seen at the site of rupture; (5) Tracheal reconstruction; (6) Complete recovery on 7th post-operative day

representing 11% of cases (Kolata *et al.*, 1974). The cervical region has been reported to be the third most common site of dog bite (Cowel *et al.*, 1989) in dogs. Generalized subcutaneous emphysema can emerge by tears in the tracheobronchial region due to traumatic, iatrogenic, or spontaneous reasons (Gorucu *et al.*, 2021).

The case study concludes that trachea rupture due to dog bite can be successfully repaired surgically.

REFERENCES

- Cowell, A.K. and Penwick, R.C. (1989). Dog bite wounds - A study of 93 cases. *Compend. Contin. Educ. Pract. Vet.* **11**: 313-318.
- Gorucu, F. and Demirkan, I. (2021). The treatment of tracheal rupture and generalized subcutaneous emphysema in a dog. *Kocatepe Vet. J.* **14**(3): 376-381.
- Jordan, C.J., Halfacree, Z.J. and Tivers, M.S. (2013). Airway injury associated with cervical bite wounds in dogs and cats: 56 cases. *Vet. Comp. Orthop. Traumatol.* **26**: 89-93.
- Kastner, S.B.R., Grundmann, S. and Wolfensberger R.B. (2004). Unstable endobronchial intubation in a cat undergoing tracheal laceration repair. *Vet. Anaesth. Analg.* **31**(3): 227-230.
- Kellagher, R.E.B. and White, R.A.S. (1987). Tracheal rupture in a dog. *J. Small Anim. Pract.* **28**: 29-38.
- Kolata, R.J., Kraut, N.H. and Johnston, D.E. (1974). Patterns of trauma in urban dogs and cats: a study of 1,000 cases. *J. Am. Vet. Med. Assoc.* **164**: 499-502.
- Picavet, P.P., Hamon, M., Etienne, A.L., Guieu, L.V., Claeys, S., Billen, F. and Noel, S. (2022). Laryngeal paralysis secondary to cervical bite injuries in five dogs. *New Zealand Vet. J.* **70**(2): 109-118.
- Roach, W. and Krahwinkel, D.J. (2009). Obstructive lesions and traumatic injuries of the canine and feline tracheas. *Compend. Contin. Educ. Vet.* **31**: 86-93.