

## DIAGNOSIS AND THERAPEUTIC MANAGEMENT OF CONCURRENT *MALASSEZIA* DERMATITIS AND DERMATOPHYTOSIS IN A DOMESTIC CAT

SELVI, D., KSHAMA, M.A., RAMESH, P.T., SHRIKRISHNA ISLOOR<sup>1</sup>, MAHESH, V.<sup>2</sup> and SUGUNA RAO<sup>3</sup>

Department of Veterinary Medicine, <sup>1</sup>Department of Veterinary Microbiology,

<sup>2</sup>Department of Veterinary Surgery and Radiology, <sup>3</sup>Department of Veterinary Pathology,  
Veterinary College, Bengaluru, KVAFSU

Received: 21.08.2023; Accepted: 18.11.2023

### SUMMARY

A two and half years old domestic tom cat weighing around 5 kg was presented to Teaching Veterinary Clinical Complex, Bengaluru with a history of hairfall, severe scratching and flaky skin for the past fortnight. On dermatological examination, generalized alopecia, erythema, follicular casts and epidermal collarettes were evident. Cat was subjected to Wood's lamp examination and skin scrapings were collected for direct microscopic examination using 10% KOH and culture in Sabouraud's dextrose agar supplemented with chloramphenicol and cycloheximide. Impression smear from the lesion was used for direct microscopy for yeast count and for yeast culture in Modified Dixon's agar. PCR confirmation was done for *Malassezia* by *M. pachydermatis* species specific primers targeting the ITS- 18S ribosomal RNA. The cat was treated with Syp. Itrapet @5mg/kg b.wt po SID for 21 days along with supportive treatment.

**Keywords:** Cat, Dermatophytes, Itraconazole, *Malassezia*

**How to cite:** Selvi, D., Kshama, M.A., Ramesh, P.T., Isloor, S., Mahesh, V. and Rao, S. (2024). Diagnosis and therapeutic management of concurrent *Malassezia* dermatitis and dermatophytosis in a domestic cat. *Haryana Vet.* 63(SI): 151-153.

*Malassezia* dermatitis is a very common canine but comparatively rare feline skin disease caused by the lipophilic, nonmycelial yeast, *Malassezia pachydermatis*. (Bensignor, 2010). *Malassezia* overgrowth should necessarily be evaluated for underlying systemic diseases such as, allergic dermatitis, paraneoplastic syndrome, retroviral infection, diabetes mellitus and hyperthyroidism (Ordeix *et al.*, 2007; Perrins *et al.*, 2007). Hence, *Malassezia* spp. overgrowth in cats is reported as a marker of a serious underlying disease and should necessarily be considered in every case of localised or generalised erythema associated with seborrhoea in cats. Pruritus is inconsistent in affected cats. The most common presenting signs of *Malassezia* dermatitis in cats are hair loss, chin acne, redness, and seborrhea (Tresamol *et al.*, 2012). *M. pachydermatis* is usually susceptible to azole antifungal drugs, among which itraconazole has a high affinity for the stratum corneum and good efficacy in the treatment of *Malassezia*-associated dermatitis (Ordeix *et al.*, 2007). Cats are easier to treat with oral medications, as opposed to bathing and dipping. It is always recommended to evaluate hepatic and renal function prior to and after use of these drugs and to closely monitor the animals during treatment by rechecking the chemistry panel every 2 to 4 weeks.

The other common dermatological ailment in cats is due to dermatophytes, filamentous and keratinophilic in nature belonging to the family Arthrodermataceae which uses keratin as a sole nutrient source (Neves *et al.*, 2018). Dermatophytosis, a highly contagious disease though with limited morbidity, can be problematic due to prolonged

course, potential for outbreaks, potential zoonosis with greater public health concern and cost of treatment (Indarjulianto *et al.*, 2014). Dermatophytes belong to three genera: *Microsporum*, *Trichophyton* and *Epidermophyton* (Carlotti, 1997). The predominant clinical signs include multifocal alopecia, scaling, pruritus and erythema. Wood's lamp and microscopic examination of skin scrapings are used for preliminary screening for dermatophytosis followed by cultural (macroscopic and microscopic) confirmation. A rapid and accurate diagnosis, accompanied by adequate treatment, is needed to limit the contagion potential.

A two and half years old domestic tom cat weighing around 5 kg was presented to the Teaching Veterinary Clinical Complex with a history of hairfall, severe scratching and flaky skin for the past fortnight. On dermatological examination generalized alopecia, erythema, follicular casts, greasiness and epidermal collarette were evident (Fig. 1). Physical examination was followed by Wood's lamp examination (Fig. 2) and confirmed by direct microscopy and culture. Skin scrapings and impression swabs were collected. One part of skin scraping was routinely subjected to direct microscopic examination using potassium hydroxide (10 % KOH) solution which revealed ectothrix covering the hair shaft (Fig. 3) and other part of sample was inoculated onto SDA plate containing chloramphenicol and cycloheximide (Himedia Ltd.), and then incubated at room temperature for 4 weeks which revealed cottony colony with yellowish orange reverse pigmentation. Microscopic observation of the colony after staining with

\*Corresponding author: selvidarmalingam@gmail.com

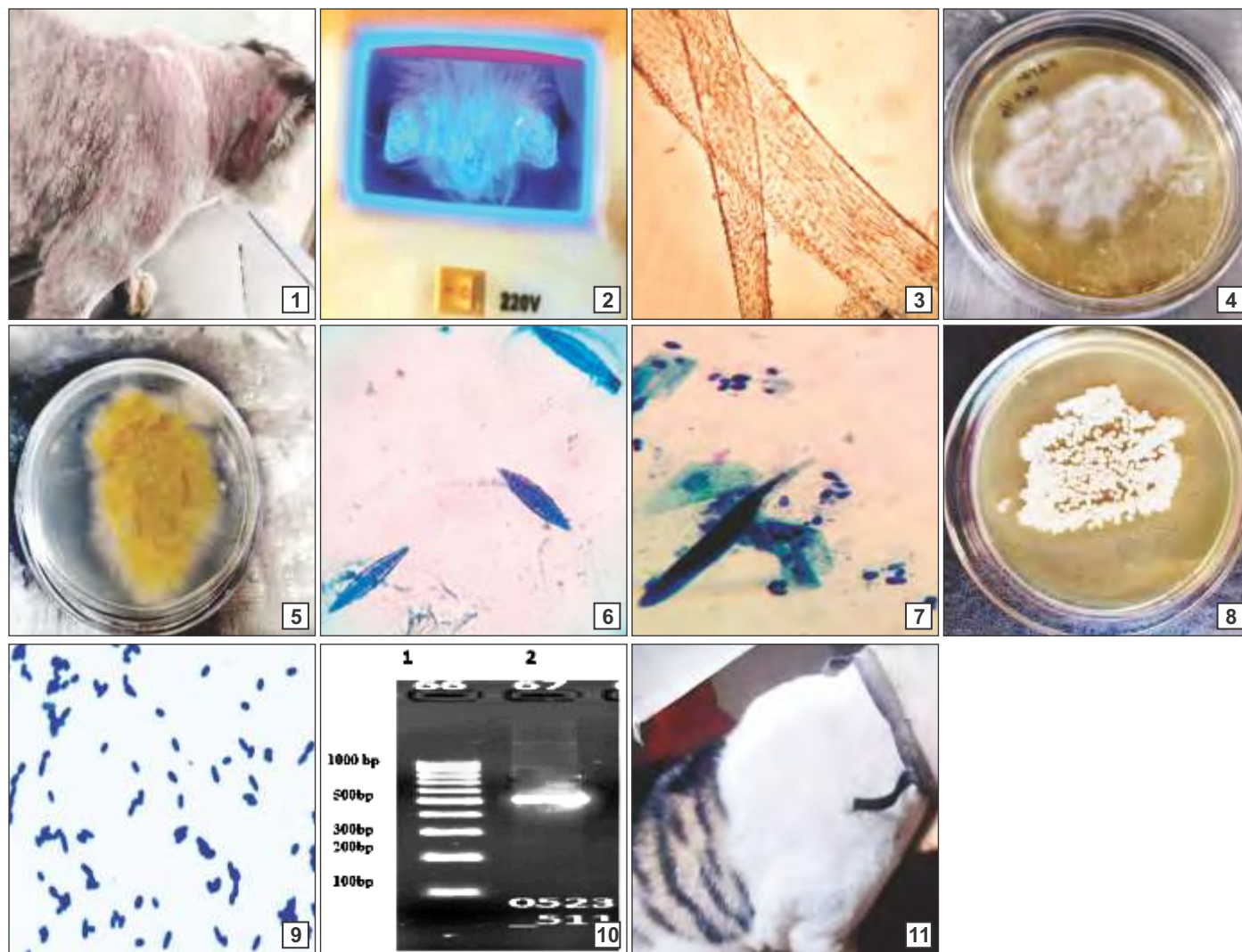


Fig. 1-11. (1) Alopecia, erythema and excessive crusts in a cat; (2) Fluorescence under Wood's lamp examination; (3) Ectothrix-Direct microscopic examination (10% KOH); (4) Macroscopic colony view of *Microsporium* spp.; (5) Cottony colony of *Microsporium* spp. with yellow orange reverse pigment; (6) Microscopic colony morphology-Macroconidia of the *Microsporium canis* in LCB staining (40 X); (7) Impression cytology stained with Loeffler's alkaline methylene blue revealing budding yeasts; (8) Macroscopic colony morphology in Modified Dixon's agar; (9) Microscopic colony morphology revealing oval and budding yeasts; (10) Molecular detection of *Malassezia* spp. (Lane 1-100 bp ladder; Lane 2-clinical Isolate of *Malassezia* spp.; Amplicon size 550 bp); (11) Cat after treatment

Lactophenol cotton blue (LCB) revealed large, spindle shaped macroconidia with thick echinulate walls containing more than six cells along with spines that appeared like a knob at terminal end (Figs. 4-6) (Markey *et al.*, 2013; Paryuni *et al.*, 2021; Sikrodia *et al.*, 2021). On the basis of Wood's lamp examination, direct microscopic examination and colony characteristics (macroscopic and microscopic) the cat was diagnosed as dermatophytosis due to *Microsporium canis*.

The smear from impression swab from the lesions was stained with Loeffler's alkaline methylene blue for 2 minutes which revealed the presence of numerous budding yeast cells (Fig. 7). Sterile swab impression collected from the site was used for fungal culture using Modified Dixon's agar supplemented with chloramphenicol and cycloheximide and incubated at 35-37° C for 5-7 days. The

colonies obtained were smooth, round, convex, friable and cream in color (Fig. 8). Microscopic examination of colonies revealed dark blue coloured oval, footprint shaped organisms on staining with methylene blue for a minute (Fig. 9).

PCR was performed for further confirmation of the species. DNA was extracted using phenol chloroform isoamyl alcohol DNA extraction method. DNA fragments were amplified using 1 µL of template DNA in 20 µL of total PCR reaction mixture using 18s F and 18s R primers (50 p mol) and 35 amplification cycles with following program: Denaturation: 95° for 45 sec, annealing: 51° for 60 sec, chain elongation: 72° for 60 sec. The amplified products were confirmed along with the 100 bp molecular size ladder by resolving at 1.5% agarose gel electrophoresis and visualized under UV transilluminator (Syngene, U.K) (Fig. 10). (Guillot *et al.*, 2000). The following primer

sequence as per Bhaswanth *et al.* (2019) was used.

Primer Sequence	5'-3' direction	sense Target
M.pa for	TCCGTAGGTGAACTGCGG	+18S rRNA gene of
M.pa rev	TCCTCCGCTTATTGATATG	- <i>M. pachydermatitis</i>

Confirmatory diagnosis was made as concurrent infection due to *Malassezia pachydermatitis* and *Microsporium canis*. As the cat had generalised *Malassezia* dermatitis and localised dermatophytic infection in the face and the reason that both the organisms respond well to azole antifungal, Syp. Itrapet was administered at 5 mg/kg PO for three weeks (Borkar *et al.*, 2014, Haimbach, 2019; Moriello, 2014) with other oral supplements. The cat had a gradual clinical cure (Fig. 11) as observed by the resolution of clinical signs.

### CONCLUSION

In cats, generalized *Malassezia* dermatitis remains extremely rare which is manifested as greasy, red, itchy skin with a rancid odour. In this case study the infected cat was diagnosed as concurrent infection due to *Malassezia pachydermatitis* and *Microsporium canis* based on dermatological examination and colony morphology (macroscopic and microscopic) for both the organisms and PCR for *Malassezia pachydermatitis*. The cat was managed successfully with systemic antifungal therapy using itraconazole.

### REFERENCES

Bensignor, V. (2010). Treatment of *Malassezia* overgrowth with itraconazole in 15 cats. *Vet. Rec.* **167**: 1011-1012.

Bhaswanth, K., Vivek Srinivas, V.M., Selvi, D., Antony, P.X. and Mukhopadhyay, H.K. (2019). Isolation and Molecular Characterization of *Malassezia pachydermatitis* from Otitis Externa of Dogs. *Vet. Res. Inter.* **7(3)**: 159-164.

Borkar, R., Roy, K., Shukla, P.C. and Gupta, D. (2014). Therapeutic management of *Malassezia* dermatitis in a dog. *Haryana Vet.* **53(2)**: 106-109.

Carlotti, D.N. (1997). Canine and feline superficial fungal skin infections. *Vet. Quarterly.* **19**: 45-46.

Guillot, J., Deville, M., Berthelemy, M., Provost, F. and Gueho, E. (2000). A single PCR restriction endonuclease analysis for rapid identification of *Malassezia* species. *Lett. Appl. Microbiol.* **31**: 400-403.

Haimbach, B. (2019). *Malassezia* Dermatitis. In: Small Animal Dermatology for Technicians and Nurses. Wiley- Blackwell. pp. 45-52.

Indarjulianto, S., Yanuartono, Purnamaningsih, H., Wikansari, P. and Sakan G.Y.I. (2014) Isolation and identification of *Microsporiumcanis* from dermatophytosis dogs in Yogyakarta. *J. Vet.* **15(2)**: 212- 216.

Markey, B., Leonard, F., Archambault, M. and Maguire, D. (2013). Clinical veterinary microbiology. *Elsevier Health Sci.* **15(2)**: 35.

Moriello, K. (2014). Feline dermatophytosis. *J. Feline Med. Surg.* **16(5)**: 419-431.

Neves, J.J.A., Paulino, A.O., Vieira, R.G., Nishida, E.K. and Coutinho, S.D.A. (2018). The presence of dermatophytes in infected pets and their household environment. *Arquivo Brasileiro de Medicina Veterinária e Zootecnia.* **70(6)**: 1747-1753.

Ordeix, L., Galeotti, F., Scarampella, F., Dedola, C., Bardagi, M., Romano, E. and Fondati, A. (2007). *Malassezia* spp. overgrowth in allergic cats. *Vet. Dermatol.* **18**: 316-323.

Paryuni, A.D., Widyarini, S., Indarjulianto, S. and Untari, T (2021). Dermatophytosis in cats: clinical signs and identification of etiological agent. *Vet. Pract.* **22(2)**: 45-47.

Perrins, N., Gaudiano, F. and Bond, R. (2007). Carriage of *Malassezia* spp. yeasts in cats with diabetes mellitus, hyperthyroidism and neoplasia. *Med. Mycol.* **45**: 541-546.

Sikrodia, R., Chhabra, D., Gangil, R., Jogi, J. and Sharda. R. (2021). Detection and identification of *Microsporiumcanis* from cats. *J. Immunol. Immunopathol.* **23(1)**: 16-20.

Tresamol, P.V., Vinodkumar, K., Saranya, M.G. and Ajithkumar, S. (2012). *Malassezia* dermatitis in a cat - A case report. *J. Vet. Ani. Scien.* **43**: 81-82.

## RETRACTION OF ARTICLE

This article earlier available at <https://www.luvas.edu.in/haryana-veterinarian/download/harvet2016-dec/1.pdf> entitled “Occurrence of some organochlorine pesticide residues in poultry feed and meat” has been retracted by the authors because of some error made during the data analysis process of the experimental observations due to counting the number of samples showing the concentration of pesticide below its corresponding Limit of Detection. All authors take full responsibility for this mistake and sincerely apologize for any inconvenience it may cause.

Editors