

## SURGICAL CORRECTION OF PHALLUS PROLAPSE IN TURTLES

K.S. ADEY\*, ADITYA V. SINGH<sup>1</sup> and B.K. BHADANE<sup>2</sup>Department of Veterinary Surgery and Radiology, <sup>1</sup>Veterinary Practitioner, Vets for Life, Nagpur,<sup>2</sup>Department of Veterinary Surgery and Radiology, Nagpur Veterinary College, Nagpur-440006, Maharashtra, India

Received: 21.06.2023, Accepted: 26.07.2023

## SUMMARY

Prolapse of phallus observed in chelonians is generally a result of some inciting factors. Six turtles were presented with chief complaint of a soft mass protruding through the vent. Of the six turtles presented four were Red eared slider (*Trachemys scripta elegans*) and two were Indian flapshell (*Lissemys punctata*) turtles. Clinical examination suggested a prolapsed phallus that was swollen, inflamed, oedematous and protruding through the cloaca. The prolapsed phallus was replaced into the cloaca followed by application of purse string sutures under general anaesthesia with Ketamine @ 25 mg/kg and Butorphanol @ 1 mg/kg intramuscularly. After surgical intervention the turtles recovered uneventfully and no recurrences were observed when followed up to six months.

**Keywords:** Cloaca, Prolapse, Turtles

**How to cite:** Adey, K.S., Singh, A.V. and Bhadane, B.K. (2024). Surgical correction of phallus prolapse in turtles. *Haryana Vet.* 63(SI): 135-137.

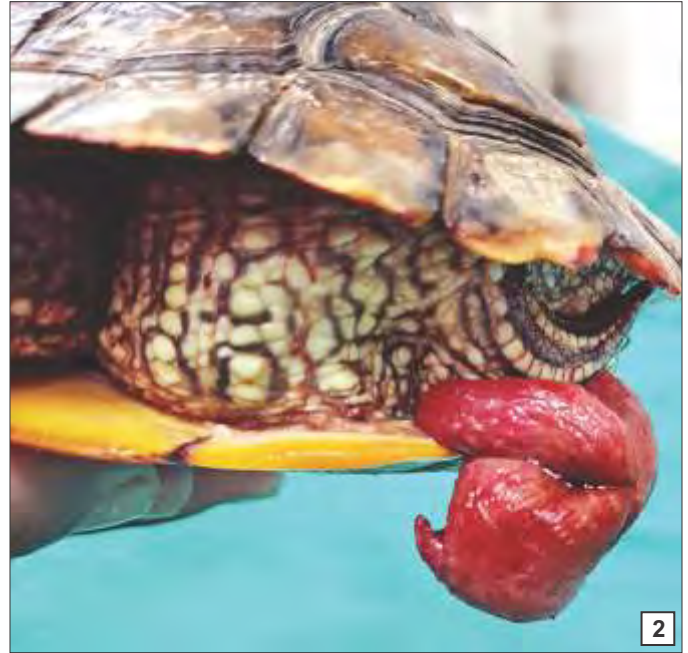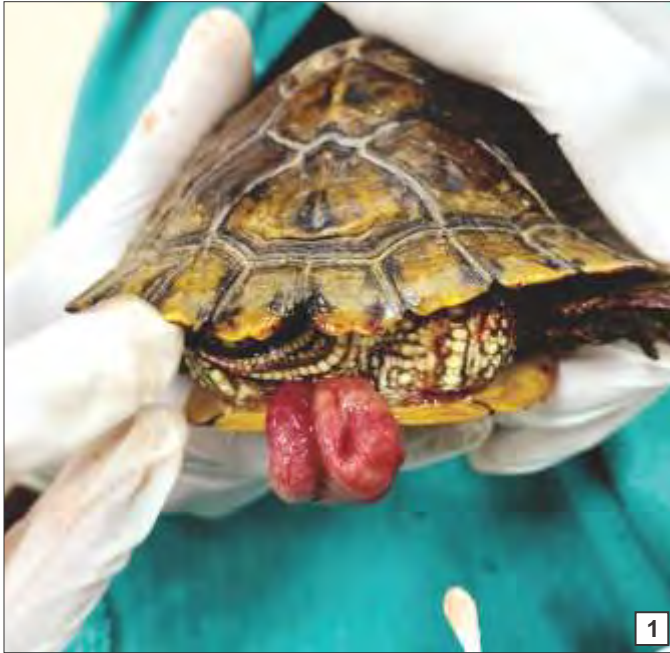Cloacal prolapses should be treated to preserve the health of the prolapsed organ (Norton, 2005). In reptiles, the urinary bladder, the distal gastrointestinal tract, the penis or hemipenis of males, and the oviduct in females may prolapse through cloaca out the vent. Cloacal prolapses typically result from excessive straining after an initiating factor, such as constipation, bacterial enteritis, parasitic enteritis, cystic calculi, egg binding, or another condition that causes straining. It's critical to identify the protruding structure and assess its viability in addition to figuring out what caused the prolapse (McArthur, 2004). The most common reason for cloacal organ prolapses is an excessive strain from an inciting factor. Penis/phallus (chelonians, crocodilians) or hemipenes (all other reptiles) is the mushroom-like copulatory organ in males (Bennett and Mader, 2006) (Martinez-Jimenez and Hernandez-Divers, 2007) which is the most commonly prolapsed organ (Innis and Boyer, 2002) (Di Girolamo and Mans, 2016).

Penile prolapse in captive-reared turtles can be brought on by nutritional secondary hyperparathyroidism, constipation (Norton, 2005). Constipation or straining brought on by gastrointestinal foreign bodies, (bladder or cloacal uroliths, gravel, or parasites) can result in penile prolapse. A spinal injury or retractor penis muscle tearing, for example, can cause neurogenic defects. Fungal, bacterial, viral infection or myiasis can irritate the penis. Coitus interruptus and excessive breeding, and grooming against rocks, and desiccation from the substrate can all injure the penis. It is challenging to identify the cause, and some cases continue to be idiopathic (Innis and Boyer, 2002).

Six turtles, four Red eared slider (*Trachemys Scripta*

*Elegans*) and two were Indian flapshell (*Lissemys punctata*) turtles were presented with the chief complaint of soft pink mass protruding from the vent. Clinical examination of the turtles revealed, swollen, inflamed oedematous prolapsed phallus (Figs. 1 & 2). The turtles were reported early hence the prolapsed phallus was in viable condition and did not show any signs of ischemia or necrosis. Urination and defecation were normal in all the turtles. All the turtles in the present study were found to be nutritionally deficient with improper diet with any supplementation. Also, the turtles were kept in poor hygienic condition. The turtles exhibited pain upon touching the protruded mass. The prolapsed mass was cleaned with sterile normal saline and povidone iodine. The volume of the swollen mass was reduced with cold fomentation. Applying cold compresses or topically hypertonic fluids reduced the severe oedema (Frye, 1991; Innis and Boyer, 2002). Surgical repositioning of the prolapsed phallus was performed in all the cases as in two cases recurrence of the prolapse was observed after 3 days. Anaesthesia was achieved by administration of ketamine @ 25 mg/kg and Butorphanol @ 1 mg/kg intramuscularly. The turtles were weighing between 650 mg to 1125 mg including shell which was considered for computing anaesthesia. The prolapsed phallus was properly lubricated with Lignocaine hydrochloride gel. With the help of moistened cotton-tipped applicators (Di Girolamo and Mans, 2016), the prolapsed phallus was repositioned into the cloaca (Fig. 3). Purse string sutures (Fig. 4) were placed with polygalactin 910 No. 3/0 leaving small opening for the passage of faecal material through the vent. Post operatively enrofloxacin @ 10 mg/kg and meloxicam @ 0.2 mg/kg was administered intramuscularly for 5 days

\*Corresponding author: khushbooadey7@gmail.com



Figs. 1-2. Prolapsed phallus

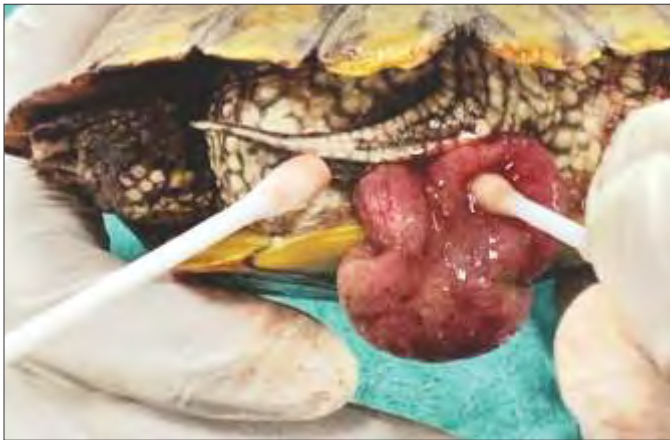

Fig. 3. Repositioning of phallus

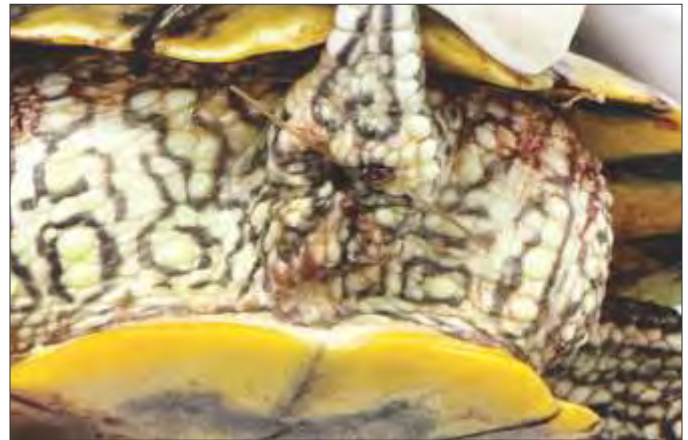


Fig. 4. After repositioning and purse-string sutures

and 3 days, respectively. No post operative complications were recorded in four cases, while on 3rd postoperative day recurrence was reported in two cases. All the turtles resumed feed intake, urination and defecation. The purse string sutures were removed on 7th post operative day.

Turtles kept in captivity have been reported with reproductive problems. The exact cause of prolapse of phallus in turtles is unknown. However, some inciting factors present may cause prolapse. In cases of prolapse, turtles may display symptoms such as anorexia, lethargy, not passing faeces, cloacal discharge, or active cloacal straining. According to Hedley and Eatwell (2014) hemipenile or cloacal infection, MBD, gastrointestinal disease, or aggressive mating behaviour are the conditions associated with true hemipenile or penile prolapse. When an animal's phallus prolapses, efforts should be made to evaluate the condition of the organ, ascertain its viability,

and determine whether it should be reduced or amputated (Kirchgessner and Mitchell, 2009). When the turtles were presented to the clinic, the phalluses were swollen and oedematous but did not show any signs of necrosis. Hence the phallus was repositioned. It is important to ascertain that which organ is prolapsed through the vent. The cloaca is where the reproductive, urinary, and gastrointestinal systems come to conclude. Therefore, prolapsed tissue needs to be carefully inspected and identified. It can be challenging to determine the origin of the tissue in cases of severe damage brought on by trauma or chronic exposure (Martinez-Jimenez and Hernandez-Divers, 2007). Some authors have suggested purse string sutures, particularly in penile prolapses (Barten, 2006), while others caution against using them, particularly if the tissue is possibly necrotic (McArthur and Hernandez-Divers, 2004). Phallus prolapse in turtles should be treated as an

emergency condition which needs to be addressed immediately. Nutritional and management practices were found to be major etiological factors for phallus prolapse in turtles.

#### REFERENCES

- Barten, S.L. (2006). Penile Prolapse. In Reptile Medicine and Surgery. Elsevier. pp. 862-864.
- Bennett, R.A. and Mader, D.R. (2006). Cloacal prolapse. In: Reptile medicine and surgery. Elsevier. pp. 751-755.
- Di Girolamo, N. and Mans, C. (2016). Reptile soft tissue surgery. *Vet. Clin. North Am. Exot. Anim. Pract.* **19(1)**: 97-131.
- Frye, F.L. (1991). Biomedical and surgical aspects of captive reptile husbandry (2<sup>nd</sup> Edn.). Krieger Pub. Co.
- Hedley, J. and Eatwell, K. (2014). Cloacal prolapses in reptiles: A retrospective study of 56 cases. *J. Small Anim. Pract.* **55(5)**: 265-268.
- Innis, C.J. and Boyer, T.H. (2002). Chelonian reproductive disorders. *Vet. Clin. North Am. Exot. Anim. Pract.* **5(3)**: 555-578.
- Kirchgessner, M. and Mitchell, M.A. (2009). Chelonians. In manual of exotic pet practice. Elsevier. pp. 207-249.
- Martinez-Jimenez, D. and Hernandez-Divers, S.J. (2007). Emergency Care of Reptiles. *Vet. Clin. North Am. Exot. Anim. Pract.* **10(2)**: 557-585.
- McArthur, S. (2004). Problem-solving approach to common diseases of terrestrial and semi-aquatic chelonians. In: S. McArthur, R. Wilkinson and J. Meyer (Eds.), Medicine and surgery of tortoises and turtles. Blackwell Publishing Ltd. (1<sup>st</sup> Edn.), pp. 309-377.
- McArthur, S. and Hernandez-Divers, S.J. (2004). Surgery. In: S. McArthur, R. Wilkinson and J. Meyer (Eds.), Medicine and surgery of tortoises and turtles. Blackwell Publishing Ltd. (1<sup>st</sup> Edn.), pp. 403-464.
- Norton, T.M. (2005). Chelonian emergency and critical care. *Sem. Avian Exot. Pet Med.* **14(2)**: 106-130.

## THE HARYANA VETERINARIAN

Editors/Editorial Board Members are highly thankful to all the distinguished referees who helped us in the evaluation of articles. We request them to continue to extend their co-operation and be prompt in future to give their valuable comments on the articles for timely publication of the journal.