

## CLINICAL MANAGEMENT OF INFECTIOUS ORCHIEPIDIDYMTIS IN A GERMAN SHEPHERD DOG

V. NEHASAMAİKYA, S. ASHWITHA, M. RAJASHRI\*, SATHISH MARTHA and E. SUNIL ANAND

Department of Veterinary Gynaecology and Obstetrics, College of Veterinary Science,  
P.V. Narsimha Rao Telangana Veterinary University, Mamnoon, Warangal, Telangana-506007, India

Received: 11.05.2023; Accepted: 08.07.2023

## SUMMARY

The present case is intended to underline the importance of the suspected diagnosis of '*E. coli*' in the presence of reproductive tract problems in male dogs.

**Keywords:** *Escherichia coli*, Nitrofurantoin, Orchiepididymitis, Scrotal swelling, Ultrasonography

**How to cite:** Nehasamaikya, V., Ashwitha, S., Rajashri, M., Martha, S. and Sunil Anand, E. (2024). Clinical management of infectious orchiepididymtis in a German Shephard dog. *Haryana Vet.* 63(SI): 133-134.

Orchiepididymitis is typically caused by bacteria, which gain access to the testes and epididymides through direct trauma (e.g. puncture wounds), retrograde passage of infected urine or prostatic secretions, bacteremia, or infected lymph. Commonly isolated organisms include *Staphylococcus*, *Streptococcus*, *Escherichia coli* and *Proteus* (Feldman *et al.*, 2014). But most cases of infectious epididymitis are caused by Gram-negative bacteria such as *Escherichia coli* and presumably by ascending infection. Acute orchiepididymitis causes acute pain, scrotal swelling, and a reluctance to stand or walk (Feldman *et al.*, 2014). The physical examination reveals variable degrees of testicular and/or epididymal swelling, hyperemia, local hyperthermia, and pain on manipulation of the testis (Feldman *et al.*, 2014). Ultrasonographically, the testicle is enlarged, hypoechoic, and possibly heterogenous. The appearance may be irregular or mass-like and mimic neoplasia (Thrall, 2017). Epididymitis caused by infection with bacteria apart from *Brucella canis* are the most common in most areas of the world. Surprisingly, little is written about them. Textbooks indicate how common these are, but there were no published articles retrieved by the electronic search engines. In this report, clinical management of a case of orchi-epididymitis with *E. coli* infection was presented.

A male German shepherd dog (aged 4 years, weighing 25 Kg) was presented with pyrexia, nervousness, panting, and scrotal swelling at Veterinary Clinical Complex, Warangal. On clinical examination, rectal temperature was 104.2° F, right testis was enlarged while left testis was normal on palpation. Both the testicles were still movable within the scrotum (Fig. 1). On ultrasonography, right testis parenchyma presented areas of anechoic structures along with enlarged epididymis while the left testicle showed echogenic parenchyma without any anechoic or hyperechoic areas (Figs. 2 and 3).

Serum biochemistry (Serum creatinine levels) were normal (0.8 mg/dl) and complete blood count indicated leukocytosis with neutrophilia and anaemia. Cross examination for *Brucella canis* was performed by Rose Bengal Plate Agglutination test (RBPT) but it was found negative. Then culture test was performed by collecting urine sample which revealed an *Escherichia coli* infection ( $10^5$  CFU/ml) thus confirming the possibility of Orchiepididymitis due to '*E. Coli*' infection.

In the present case, the urine sample culture revealed an *E. Coli* infection. As per ABST, culture was found sensitive to antibiotic ceftriaxone. As the culture confirmed *E. Coli* infection, along with antibiotic therapy (Inj. Ceftriaxone-500 mg, I/M, SID for 10 days), Tab. Nitrofurantoin was given at the rate of 5 mg per kg body weight (110 mg, SID) for 7 days orally (Weese *et al.*, 2011). Nitrofurantoin is bactericidal against most common urinary tract pathogens, including *Escherichia coli*, *Enterococci*, *Klebsiella*, *Staphylococcus saprophyticus* and *Enterobacter*. Its spectrum of susceptibility also includes *Shigella*, *Salmonella*, *Citrobacter*, *Neisseria*, *Bacteroides*, group B streptococcus, *Staphylococcus aureus* and *Staphylococcus epidermidis*. Studies have shown the effectiveness of nitrofurantoin does not differ between ESBL (Extended-Spectrum Beta-Lactamase)-producing *E. coli* and non-ESBL-producing *E. coli* strains (Gardiner *et al.*, 2019). In some dogs with recurrent lower UTIs, nitrofurantoin may be an effective antibiotic for treatment of nitrofurantoin-susceptible uropathogens (Leuin *et al.*, 2021).

A non-steroidal antinflammatory drug Inj. Meloxicam -2.2 mg (I/M, @ 0.1 mg/kg b. wt.) administered for 10 days. Tab. Fluconazole @5 mg/kg b.wt was given orally weekly once for 3 weeks to prevent any fungal infection due to long course of antibiotic therapy. Animal recovered well following treatment which was

\*Corresponding author: rsri0835@gmail.com

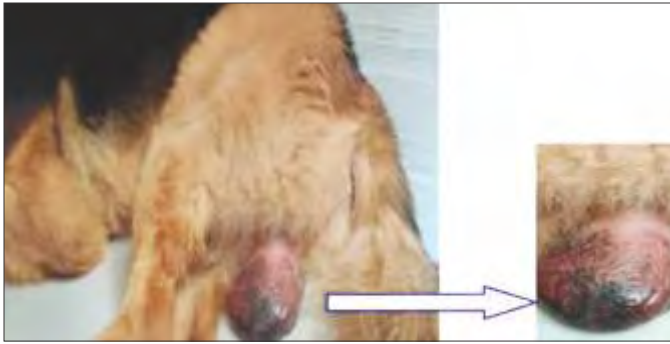

Fig. 1. German shepherd dog showing unilateral Orchi-epididymitis confirmed by complete blood picture (normal levels of neutrophil and leukocyte count) and was re-examined by ultrasonography on 15<sup>th</sup> day of antibiotic therapy where both testes showed normal testicular size and did not reveal any abnormalities.

In conclusion, orchiepididymitis with *E. Coli* infection presented in German shepherd dog was diagnosed clinically and successfully treated with antibiotics Nitrofurantoin and Ceftriaxone without any complications.

#### REFERENCES

- Feldman, E.C., Nelson, R.W., Reusch, C. and Scott-Moncrieff, J.C. (2014). Canine and feline endocrinology-e-book. *Elsevier Health Sci.* p. 971.
- Gardiner, B.J., Stewardson, A.J., Abbott, I.J. and Peleg, A.Y. (2019). Nitrofurantoin and fosfomycin for resistant urinary tract infections: old drugs for emerging problems. *Austral. Prescrib.* **42(1)**: 14-19.
- Kustritz, M.V.R. (2006). The dog breeder's guide to successful breeding and health management e-book. *Elsevier Health Sciences.* p. 346.
- Leuin, A.S., Hartmann, F. and Viviano, K. (2021). Administration of nitrofurantoin in dogs with lower urinary tract infections: 14 cases (2013-2019). *J. Small Anim. Pract.* **62(1)**: 42-48.
- Noakes, D.E., Parkinson, T.J. and England, G.C. (2018). Arthur's veterinary reproduction and obstetrics-e-book. *Elsevier Health Sciences.* p. 653.
- Thrall, D.E. (2017). Textbook of veterinary diagnostic radiology-e-book. *Elsevier Health Sciences.* p. 891.
- Weese, J.S., Blondeau, J.M., Boothe, D., Breitschwerdt, E.B., Guardabassi, L., Hillier, A., Lloyd, D.H., Papich, M.G., Rankin, S.C., John D

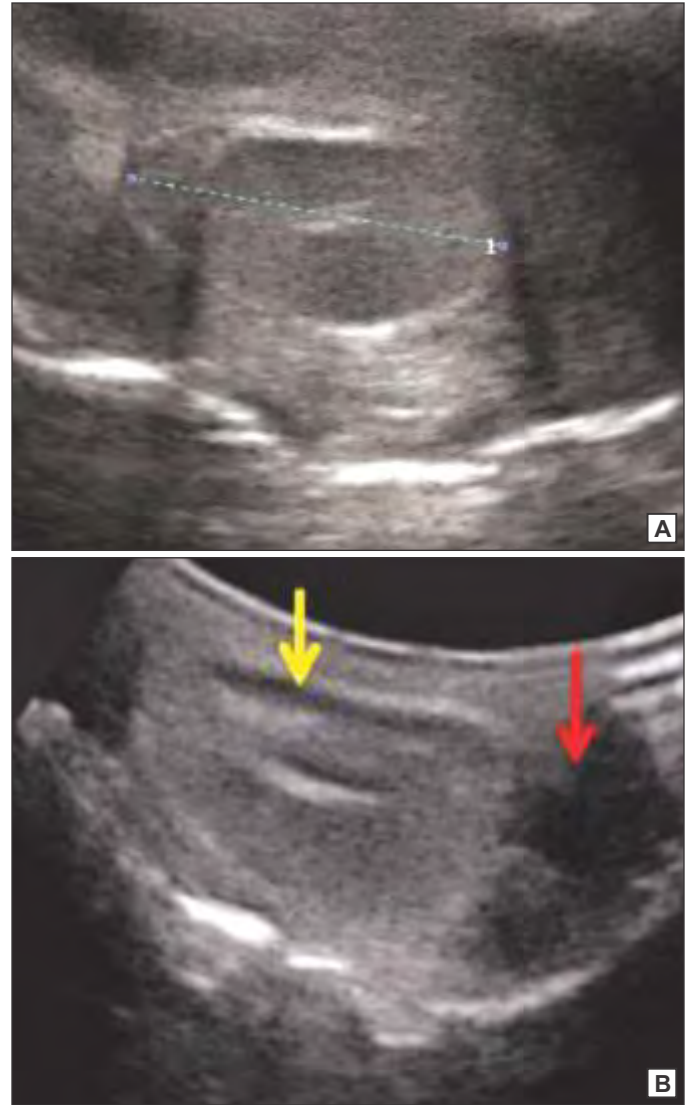


Fig. 2. (A and B). Ultrasonographic image of (A) Left testicle - length - 3.49 cm, (B) Right testicle showing enlargement with anechoic areas (Yellow arrow) with enlarged epididymis (Red arrow)

Turnidge, J.D. and Sykes, J.E. (2011). Antimicrobial use guidelines for treatment of urinary tract disease in dogs and cats: Antimicrobial guidelines working group of the international society for companion animal infectious diseases. *Vet. Med. Intern.* 263768; 1-9. doi: 10.4061/2011/263768.