

SURGICAL REPAIR OF FEMORAL FRACTURES IN DOGS

DEEPAK KAUSHIK, SANDEEP SAHARAN¹, DEEPAK KUMAR TIWARI, NEERAJ ARORA
and GAURAV KUMAR*¹

Department of Veterinary Surgery and Radiology, ¹Department of Veterinary Clinical Complex,
College of Veterinary Sciences, Lala Lajpat Rai University of Veterinary and Animal Sciences, Hisar-125004, Haryana

Received: 22.06.2023; Accepted: 11.08.2023

SUMMARY

The present clinical study was conducted on four dogs presented to the department with history of road accident and non-weight bearing lameness. Among four animals, three were males and one female having different age groups (ranging from 6 -12 months). Clinical examination revealed severe pain and crepitus in all the animals. The haemato-biochemical parameters were within the normal limits. Plain radiography of the affected bone was performed in lateral and cranio-caudal views for confirmatory diagnosis, implant selection and surgical approach. Open reduction and internal fixation (ORIF) were performed in all the animals. The surgical site was aseptically prepared and cranio-lateral approach was used to expose the fractured fragments. All the animals were pre-anaesthetised using atropine sulphate while induction was achieved with a mixture of Xylazine HCl and Ketamine HCl and maintained under Isoflurane anaesthesia. Retrograde technique followed for pin placement was quite satisfactory. Orthopaedic wire (hemi-cerclage or full cerclage) provides inter fragmentary compression between oblique, spiral and comminuted fracture fragments. All the dogs show uneventful recovery and starts bearing partial weight after two weeks as the principle of fracture repair were followed strictly which results in the success of fixation method used in present study.

Keywords: Bone plates, C-arm, Dog, Femur, Fracture, Orthopaedic wire

How to cite: Kaushik, D., Saharan, S., Tiwari, D.K., Arora, N. and Kumar, G. (2024). Surgical repair of femoral fractures in dogs. *Haryana Vet.* 63(SI): 107-109.

Bone fractures constitute a major problem in small animal practice particularly in dogs (Gadallah *et al.*, 2009). Femoral fractures in dogs and cats include 20%-25% of all fractures. It is represented 45% of all long bone fractures, the percentage is doubled regarding all other bones individually (DeCamp *et al.*, 2016). While metaphyseal and diaphyseal fractures were more common in mature dogs, proximal or distal physeal fractures were more common in young dogs (Simon *et al.*, 2011). Most of the femur fractures are unstable and their evaluation for type of the fracture, direction of fragments, location of the fracture, whether open or closed and joint involvement are important points for proper planning of treatment (Beale, 2004).

In contrast to other implants like bone plates and external skeletal fixators, intramedullary pins have unique biomechanical advantage of resisting bending forces applied from any direction because of their round structure (McLaughlin, 1999). Harasen (2003) reported that simple oblique femoral fracture could be well managed with an intramedullary pinning and full Cerclage wire. The Intramedullary pinning is a simple and economic method of immobilization of the diaphyseal fracture (Kumar and Gahlot, 2013).

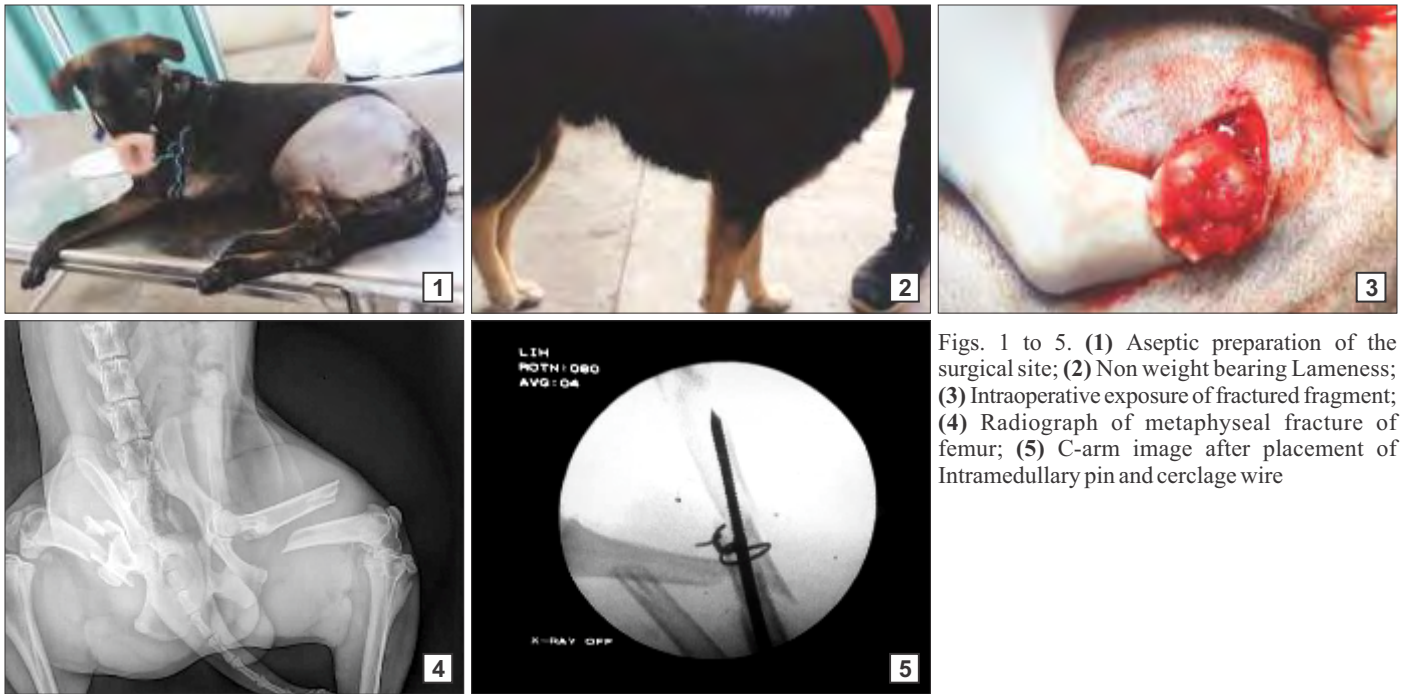
The present study was conducted on clinical cases presented with the Department of Veterinary Clinical Complex, LUVAS, Hisar with history of non-weight bearing lameness (Fig. 2) and clinical symptoms suggestive of femur fracture. Palpation of affected limb region indicated

pain, swelling and crepitus. Confirmative diagnosis of femur fracture was made by radiographic evaluation (Fig. 4) of the affected limb which revealed the presence of mid diaphyseal oblique fracture. Haematological parameters were within normal range. The main aim of fracture repair is to achieve a healed fracture with normal bone alignment and promote immediate function of the affected limb. Open reduction and internal fixation (ORIF) method was decided for these cases.

After a routine pre-operative fasting the dogs were premedicated with Atropine Sulphate at the dose rate of 0.04 mg/kg body weight intramuscularly followed by induction with Xylazine HCl (@ 1 mg/Kg body weight) + Ketamine HCl (@ 5 mg/Kg body weight) via Ringers Lactate using intravenous canula and maintenance with 3-5% Isoflurane anaesthesia. Preoperative antibiotics and analgesics were administered intramuscularly. Trocar pointed Steinmann pins made of surgical grade stainless steel and cerclage wire of appropriate size were used for ORIF procedure. The operative site was shaved and scrubbed using povidone-iodine surgical scrub, followed by application of surgical spirit (Fig. 1).

The animal was placed in lateral recumbency with the affected limb placed uppermost on operating table. A skin incision was made on the cranio-lateral aspect of the thigh extending from the trochanter major to the lateral condyle of the femur (Rani *et al.*, 2012). All fractures were treated with standard surgical procedure of the femur under complete aseptic technique (Fossum, 2013). Blood

*Corresponding author: gauravkumar@gadvasu.in



Figs. 1 to 5. (1) Aseptic preparation of the surgical site; (2) Non weight bearing Lameness; (3) Intraoperative exposure of fractured fragment; (4) Radiograph of metaphyseal fracture of femur; (5) C-arm image after placement of Intramedullary pin and cerclage wire

clots, fibrin mass and sequestered bones (Fig. 3) if any were removed and site was cleaned with normal saline solution. The proximal fracture fragment was held with bone holding forceps. A Steinmann pin of appropriate length was inserted proximally in the medullary canal in a retrograde manner with the help of Jacobson's chuck by quarter turns and constantly applying pressure. Two to three full Cerclage wires were placed to hold the bony fragments around the intramedullary pin (Fig. 5). Proximal part of the pin was left protruding out from the skin for a length of 4 to 5 cm.

The tensor fascia lata was sutured with 2-0 PGA (Polyglactin) in a continuous pattern followed by subcuticular sutures with 2-0 PGA. The skin was sutured in horizontal mattress pattern by using silk. Post-operatively the dogs were administered. Ceftriaxone and Tazobactam @ 562 mg and Meloxicam @ 0.5 mg/kg body weight intramuscularly for 5-7 days. Post-operative radiographs were taken to assess placement of intramedullary pins.

Among the reported cases all the femur fracture were closed and as per location of the fracture site one was proximal femur fracture, two were diaphyseal fracture and one was distal femur fracture. The intramedullary pin was placed by retrograde technique in all the cases because it is simple and usually successful. Orthopaedic wire hemi-cerclage or full cerclage wires provide interfragmentary compression between oblique, spirals or comminuted fracture fragments. Cerclages are widely used as primary fixation device for fracture in small animal surgery (Siffler, 2004), but as a stand-alone implant for human long

bones, they are too weak to fulfil the requirements of functional aftercare (Perren *et al.*, 2011). In research by Inas *et al.*, 2012 they argue that the intramedullary pinning offers high-quality balance for long bones, so it offers great biomechanical surroundings for fracture recovery. The positive profile end threaded intramedullary pin provide rigid fixation and early weight bearing and satisfactory healing as per Yadav *et al.*, 2023. Lateral and cranio-lateral radiographs are proved to be useful in identifying the type and location of fracture along with the appropriate fixation technique. The radiographs also help to assess the post-surgery evaluation of the fixation technique and post recovery finding.

CONCLUSION

To conclude intramedullary pinning with cerclage wire was an easy, most economic, less time consuming and least traumatic technique for the stabilization of femur fractures in dogs with good outcome. The intramedullary pinning offers a perfect alignment and rigid fixation of the fractured bone.

REFERENCES

- Beale, B. (2004). Orthopaedic clinical techniques femur fracture repair. *Clin. Tech. Small. Anim. Pract.* **19**(3): 134-150.
- DeCamp, C.E., Johnston, S.A., Déjardin, L.M. and Schaefer, S.L. (2016). Brinker, Piermattei, and Flo's Handbook of Small Animal Orthopedics and Fracture Repair. (5th Edn.) St. Louis: Saunders Elsevier, pp. 518-596.
- Fossum, T.W., Dewey, C.W., Horn, C.V., Johnson, A.L., MacPhail, C.M., Radlinsky, M.G., Schulz, K.S. and Willard, M.D. (2013). Small Animal Surgery (4th Edn.), Elsevier Mosby, pp. 1033-1199.
- Gadallah, S., Marzok, M. and El-Husseiny, I. (2009). Fractures repairs

- in dogs. *Kafrelsheikh. Vet. Med. J.* **7(1)**: 314-336.
- Harasen, G. (2003). Common long bone fracture in small animal practice Part 2. *Can. Vet. J.* **44(6)**: 503.
- Inas, N.M., Mostafa, A., Habak and Harb, H. (2012) Biomechanical studies on femoral fracture repair fixed by different fixation methods in dogs. *J. Am. Sci.* **8**: 216-222.
- Kumar, P. and Gahlot, T.K. (2013). Clinical evaluation of intramedullary pinning and interlocking nailing technique for stabilization of femoral fractures in dogs. *J. Anim. Sci. Adv.* **3(6)**: 310-313.
- McLaughlin, R. (1999). Internal fixation: intramedullary pins, cerclage wires, and interlocking nails. *Vet. Clin. North. Am. Small. Anim. Pract.* **29(5)**: 1097-1116.
- Perren, S.M., Fernandez, D.A., Lenz, M. and Windolf, M. (2011). Cerclage, evolution and potential of a Cinderella technology. An overview with reference to periprosthetic fractures. *Acta. Chir. Orthop. Traumatol. Cech.* **78(3)**: 190-199.
- Rani, R.U., Rajendran, N. and Vairavasamy, K. (2012). Immobilisation and treatment of femoral diaphyseal oblique fractures in dogs using double intramedullary pinning and cerclage wiring- A study in twelve patients. *Intas Polivet.* **13(2)**: 411-415.
- Simon, M.S., Ganesh, R., Ayyappan, S. and Kumar, R.S. (2011). Incidence of pectoral limb fractures in dogs: a survey of 331 cases. *Tamil Nadu J. Vet. Anim. Sci.* **7(2)**: 94-96.
- Stiffler, K.S. (2004). Internal fracture fixation. *Clin. Tech. Small. Anim. Pract.* **19**: 105-113.
- Yadav B., Parashar, M.C. Singh, Y.P. and Singh, S. (2023). Evaluation of positive profile end threaded intramedullary pins for the repair of femur fractures in dogs. *Haryana Vet.* **62(SI)**: 61-64.

CONTRIBUTORS MAY NOTE

- Research/Clinical articles are invited for next issue from the Scientists/Veterinarians engaged in Veterinary Profession.
- Please follow strictly the format of 'The Haryana Veterinarian' for manuscript writing/submission.
- Please pay processing fee of Rs. 1200/- online in the account of Dean, College of Veterinary Sciences, along with each article.
- After revision, please return the revised manuscript and rebuttal at the earliest.
- Please mention your article reference number in all correspondence for a quick response.
- We solicit your co-operation.
- All correspondence should be addressed to 'The Editor', Haryana Veterinarian, Department of Veterinary Parasitology, College of Veterinary Sciences, LUVAS, Hisar-125004.

Editors