

SURGICAL MANAGEMENT OF OESOPHAGEAL OBSTRUCTION IN COW- A CASE REPORT

V. LALZAWMLIANA*, SHONGSIR WARSON MONSANG and APURBA DEBBARMA¹

Department of Veterinary Surgery & Radiology, ¹Department of Veterinary Parasitology,
College of Veterinary Sciences and Animal Husbandry, R.K. Nagar, West Tripura-799008

Received: 22.07.2024, Accepted: 08.09.2024

SUMMARY

The present communication reports a clinical case of emergency oesophagotomy for cervical oesophageal obstruction caused due to fresh guava under sedation and local analgesia with successful clinical outcome in a four years old non-descript free ranging cow.

Keywords: Choke, Oesophagotomy, Sedation, Analgesia

How to cite: Lalzawmliana, V., Monsang, S.W. and Debbarma, A. (2024). Surgical management of oesophageal obstruction in cow- A case report. *Haryana Vet.* 63(SI): 142-144.

Oesophageal obstruction or choke is considered as one of the most important disorder or disease of cattle and horses (Haven, 1990) and is attributable to their feeding habits (Harikrishna *et al.*, 2011). There are several causes of obstruction and most common cause includes foreign bodies (Patel and Brace, 1995). The affected animal appears to be anxious, extends its head and neck, and shows excessive drooling of saliva associated with variable degrees of bloat and forceful attempts to swallow the obstructing object may be observed (Haven, 1990). Esophageal obstruction is usually located at the cervical esophagus, at the thoracic inlet or at the base of the heart. External palpation may be used to confirm those located in the cervical esophagus (Haven, 1990). In cattle, acute and complete oesophageal obstruction is always an emergency because it prohibits the eructation of ruminal gases, and long standing cases of bloat can be life threatening (Prakash *et al.*, 2014), due to increase in the intra-abdominal pressure. The present communication reports a case of cervical oesophageal obstruction due to fresh guava and its surgical management in a cow.

A four years old non-descript free ranging cow of approximately 300 kg was presented to Department of Veterinary Surgery & Radiology, C.V.Sc & A.H., R.K. Nagar, West Tripura with history of drooling salivation, respiratory distress, dysphagia along with slight abdominal distention for the past one day. On clinical examination, the animal looked anxious with extended neck [Fig. 1(A)]. A prominent swelling was noticed at the mid cervical oesophageal region and manual palpation revealed a solid round movable mass obstructing oesophagus at mid cervical region [Fig. 1(B)]. An attempt was made to remove the foreign body manually with unfruitful outcome. Hence, surgical intervention was decided for emergency oesophagotomy.

Preoperatively, the animal was rehydrated with 5% DNS to maintain fluid and electrolyte balance. Xylazine (@ 0.1mg/Kg BW, IM), was administered for mild sedation and the animal was restrained in right lateral recumbent position. The surgical site was prepared aseptically as per standard protocol and local analgesia was achieved by infiltrating 2% Lignocaine HCl. Approximately 8 cm skin incision was made over the swelling on the left side of the neck along the dorsal aspect of the jugular furrow. The muscles were separated by blunt dissection and oesophagus was exposed between the sterno-cephalicus muscle and trachea. The site of obstruction was identified and 5 cm longitudinal incision was made through the lateral wall of the esophagus [Fig. 2 (A)], and the foreign body (raw guava) was retrieved carefully by gentle squeezing [Fig. 2(B)]. Since the oesophageal mucous membrane appeared healthy [Fig. 2(C)], the mucosal layer was sutured with simple interrupted sutures using absorbable suture material (Vicryl No. 1-0) [Fig. 2(D)]. The submucosa and muscularis were closed in one layer using a simple continuous suture pattern using Vicryl No. 1 followed by muscle and skin closure in routine manner [Fig. 3(A)]. Postoperative treatment included broad spectrum antibiotics (Inj. Intacef 3 gm, IM) and anti-inflammatory (Inj. Melonex 15ml, IM) for 5 days and 3 days, respectively, along with fluid therapy and local dressing using betadine and fly repellent application twice daily [Fig. 3(B)]. Skin sutures were removed on the 14th day of postoperatively and the animal made an uneventful recovery.

Hofmeyr (1974) reported that 80% of oesophageal obstruction occurs in the cervical region in cattle. The prognosis is considered good if treated within 24 to 36 hr from the onset of clinical signs (Ravikumar *et al.*, 2003). Oesophageal obstruction due to a mango and its surgical management in a heifer was reported by Veena *et al.*,

*Corresponding author: zawma01@gmail.com

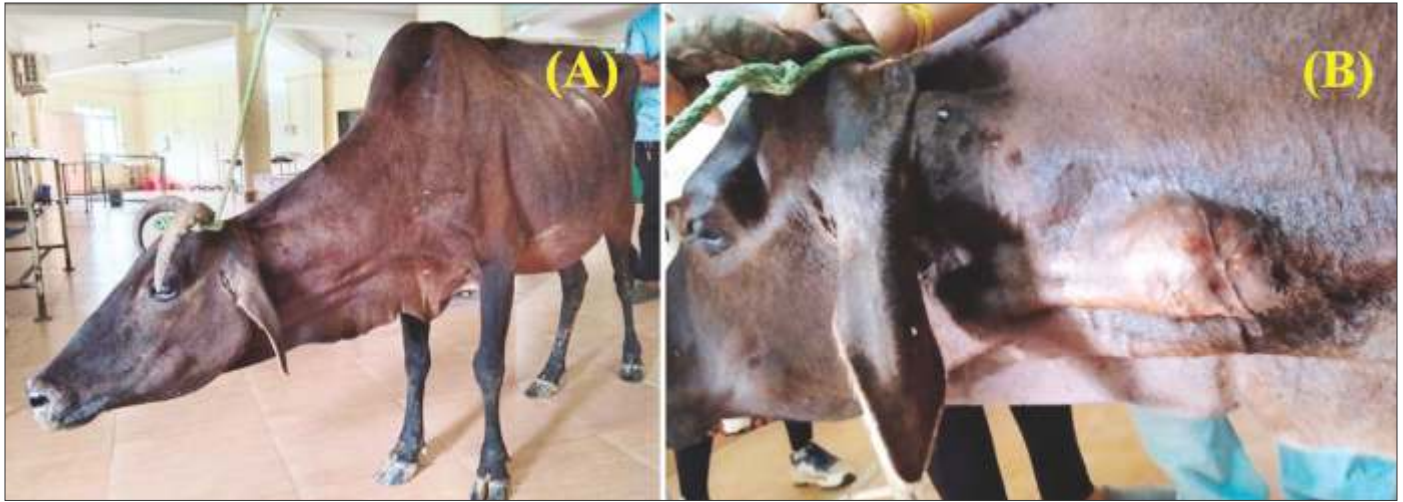

Fig. 1. (A) Animal showing sign of discomfort with extended neck and (B) Solid round movable mass at mid cervical oesophageal region

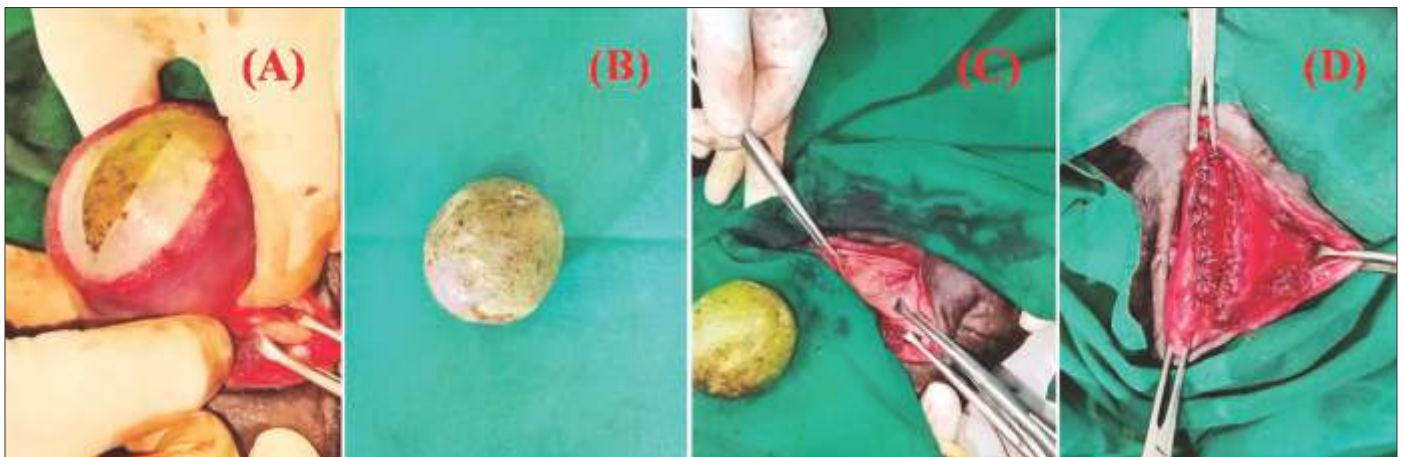


Fig. 2. (A) Longitudinal incision on oesophageal wall, (B) Retrieved foreign body, (C) Oesophageal mucous membrane and (D) Closure of mucosal layer using absorbable suture material



Fig. 3. (A) Skin suture and (B) Post-operative antiseptic dressing

(2000) and stated that the obstruction could be relieved easily if the obstruction is in the cervical region. Sreenu and Sureshkumar (2001) also reported successful surgical management of oesophageal obstruction by tarpaulin cloth in a buffalo calf which corresponded with the present case

of oesophageal obstruction. Ruben (1997) reported the risk of post-operative complications associated with an oesophagotomy like incisional dehiscence and fistula formation which were not observed in our clinical situation.

REFERENCES

- Harikrishna, N.V.V., Sreenu, M. and Bose, V.S.C. (2011). An unusual case of oesophageal obstruction in a female buffalo. *Buffalo Bull.* **30**: 4-5.
- Haven, M.L. (1990). Bovine esophageal surgery. *Vet. Clin. North Am. FoodAnim. Pract.* **6**: 359-369.
- Holfmeyr, C.F.B. (1974). Obstruction of oesophagus by tarpaulin cloth in a buffalo calf. *Indian Vet. J.* **78**: 243-244.
- Patel, J.H. and Brace, D.M. (1995). Esophageal obstruction due to a trichobezoar in a cow. *Can. Vet. J.* **36**: 774-775.
- Prakash, S., Jevakumar, K., Kumaresan, A., Selvaraju, M., Ravikumar, K. and Sivaraman, S. (2014). Management of cervical choke due to Beetroot- A Review of two cases. *Shanlax Int. J. Vet. Sci.* **1(3)**: 37-38
- Ravikumar, S.B., Arunkumar, P. and Madhusudan, A. (2003). Oesophageal obstruction in a buffalo- A case report. *Intas Polivet.* **4**: 48-49.
- Ruben., J.M. (1997). Surgical removal of a foreign body from the bovine oesophagus. *Vet. Rec.* **100**: 220.
- Sreenu, M. and Sureshkumar, R.V. (2001). Obstruction of oesophagus by tarpaulin cloth in a buffalo calf. *Indian Vet. J.* **78**: 243-244.
- Veena, P., Ravikumar, A. and Ramakrishna, O. (2000). Oesophageal obstruction by mango in a heifer. *Indian Vet. J.* **77**: 794.

CONTRIBUTORS MAY NOTE

- Research/Clinical articles are invited for next issue from the Scientists/Veterinarians engaged in Veterinary Profession.
- Please follow strictly the format of 'The Haryana Veterinarian' for manuscript writing/submission.
- Please pay processing fee of Rs. 1200/- online in the account of Dean, College of Veterinary Sciences, along with each article.
- After revision, please return the revised manuscript and rebuttal at the earliest.
- Please mention your article reference number in all correspondence for a quick response.
- We solicit your co-operation.
- All correspondence should be addressed to 'The Editor', Haryana Veterinarian, Department of Veterinary Parasitology, College of Veterinary Sciences, LUVAS, Hisar-125004.

Editors