

COMPARATIVE EFFICACY OF ZINC OXIDE NANOPARTICLE CONJUGATED DOCETAXEL AND DOCETAXEL ALONE FOR MAMMARY TUMOUR IN DOG

GUNJAN DHOTE, B.K. BHADANE*, S.B. AKHARE, M.V. KAMBLE., G.A. FISKE and M.P. KAORE¹

Department of Veterinary Surgery and Radiology, ¹Department of Veterinary Pathology,
Nagpur Veterinary College, Nagpur-440001 (Maharashtra), India

Received: 12.06.2023; Accepted: 29.08.2023

ABSTRACT

The present investigation was undertaken to ascertain the efficacy of surgico-chemotherapeutic treatment for the management of mammary tumors in bitches. The study was conducted on 18 clinical cases of different breeds irrespective of age and divided into three groups. Depending upon the size of the mammary tumor, these cases were subjected to either partial mastectomy, chemotherapy with Docetaxel alone at a dose rate of 30 mg/m² over a period of one hour at weekly intervals in three cycles on days 0, 7 and 14 and Zinc oxide nanoparticle conjugated Docetaxel intratumorally at a dose rate of 15 mg/m² at weekly intervals in three cycles on day 0, 7 and 14. Blood samples were estimated after each course of chemotherapy to monitor the changes in some principal haematological and biochemical parameters.

Keywords: Canine, Conjugated Docetaxel, Docetaxel, Mammary tumor, Zinc Oxide nanoparticles

How to cite: Dhote, G., Bhadane, B.K., Akhare, S.B., Kamble, M.V., Fiske, G.A. and Kaore, M.P. (2024). Comparative efficacy of zinc oxide nanoparticle conjugated docetaxel and docetaxel alone for mammary tumour in dog. *Haryana Vet.* 63(SI): 57-60.

Canine cancer is a leading cause of morbidity and mortality among companion animals and represents one of the major causes of purebred dogs (V.J. Adams *et al.*, 2010). Classically treatment cancer includes surgical excision, chemotherapy and radiation therapy. Surgery is the mainstay of treatment in canine mammary tumours and can be curative in patients with benign tumours, low-grade histology or early-stage disease (Sorenmo *et al.*, 2011). Taxoids such as Paclitaxel and Docetaxel share a similar mechanism of action which includes promotion of microtubule assembly and inhibition of microtubule disassembly for destruction of cancerous cells. Docetaxel, at a lower dose, has registered only limited side effects. Docetaxel was twice as active in depolymerization inhibition (Simon *et al.*, 2006). Zinc oxide nanoparticles (ZnO NPs) showed cancer cell-specific toxicity via the generation of reactive oxygen species and destruction of mitochondrial membrane potential, which leads to the activation of cascades followed by apoptosis of cancerous cells. Intratumoral administration is a promising strategy for treating various tumours with limited systemic toxic effects (Kate *et al.*, 2020). It focuses the medication in the intended area for a long time while diverting it away from non-target tissues to boost toxicity and efficacy.

MATERIALS AND METHODS

In the present study, various canine mammary tumors presented at the Veterinary Clinical Complex of Nagpur Veterinary College were reported from the period of May 2022 to January 2023. The selected dogs were subjected to detailed clinical and haemato-biochemical examinations on the first day of treatment and subsequently

as per the plan. Dogs with tumour sizes over 5 cm were subjected to surgical excision in group-III, and smaller-sized tumours were subjected to chemotherapy in groups-I, dogs were given Chemotherapy with Docetaxel @ 30 mg/m² intravenously and in group-II dogs were treated with nanoparticulate Zinc oxide conjugated Docetaxel for intratumoral administration of Docetaxel @ 15 mg/m² at weekly intervals in three cycles on day 0, 7 and 14. Table 1 describes the groups and respective treatment protocols which were followed in this research work. Haematological and biochemical parameters were tested at intervals of 0, 3rd, 5th day during each chemotherapeutic cycle. Radiograph was taken to examine metastasis on day 0 and subsequently as required.

Treatment groups and protocol followed :

	Treatment	No. of Animals
Group-I	Chemotherapy with Docetaxel @ 30 mg/m ² over a period of one hour at weekly intervals in three cycles on day 0, 7 and 14.	6
Group-II	Nanoparticulate Zinc oxide conjugated Docetaxel for intratumoral administration of Docetaxel @ 15 mg/m ² at weekly intervals in three cycles on day 0, 7 and 14.	6
Group-III	Surgical excision	6

RESULTS AND DISCUSSION

This study measured haematological and biochemical levels in all animals on the 0, 3rd and 5th day of respective cycles.

Haematological parameters: Group-I showed a consistent drop in red blood cells (x10⁶/uL) on day three after intravenous administration of the drug followed by a

*Corresponding author: drbhagyashreebhadane@gmail.com

Table 1. Mean±SE RBCs obtained in selected study groups

Treatment Cycle	Interval	Group - I	Group - II	Group - III	Pooled for Cycle
1	0	6.88±0.29	6.93±0.32	7.07±0.20	6.71±0.07 ^a
	3	6.25±0.15	6.63±0.24	6.68±0.19	
	5	6.52±0.15	6.72±0.19	6.73±0.10	
2	0	6.58±0.15	6.92±0.28	6.65±0.12	6.59±0.07 ^a
	3	6.30±0.14	6.73±0.26	6.78±0.19	
	5	6.00±0.26	6.55±0.23	6.83±0.18	
3	0	6.37±0.20	6.72±0.20	6.72±0.13	6.64±0.06 ^a
	3	6.57±0.16	6.68±0.22	6.80±0.12	
	5	6.37±0.10	6.67±0.25	6.83±0.13	
Pooled for Group		6.43±0.07 ^A	6.73±0.08 ^B	6.79±0.05 ^C	CD = 0.01714

Table 2. Mean±SE Alkaline Phosphatase (IU/L) obtained in selected study groups

Treatment Cycle	Interval	Group - I	Group - II	Group - III	Pooled for Cycle
1	0	367.88±64.26	223.83±23.16	251.50±24.41	318.62±18.57 ^a
	3	527.00±79.03	277.00±25.49	260.83±26.77	
	5	431.33±37.54	275.67±29.88	252.50±32.34	
2	0	404.50±34.35	279.33±23.77	214.83±23.61	358.76±51.42 ^a
	3	815.83±393.60	304.83±27.21	214.33±18.92	
	5	500.50±174.93	291.33±29.04	203.33±18.35	
3	0	391.17±52.77	302.17±32.40	206.67±21.77	299.73±16.02 ^a
	3	442.56±32.05	301.50±24.32	187.17±17.99	
	5	394.17±53.44	290.1±722.81	182.00±16.13	
Pooled for Group		474.99±49.70 ^A	282.87±8.79 ^B	219.24±7.94 ^C	CD=7.704401

gradual increase on day 5 in each chemotherapeutic cycle, and there was an overall decrease in the RBC count at the end of three cycles of chemotherapy. The drop in RBC count was more in Group-I, followed by Groups-II and III, respectively as shown in Table 1. There has been a significant drop in Hb concentration following the chemotherapeutic cycle in Group-I. Similarly, a slight reduction in Hb values was observed in Group-II on day 3. In Group-III, lower Hb was observed on the third day postoperatively due to blood loss during the surgical procedure. In all three groups, the Hb values were within the normal range even after the postoperative and post-chemotherapeutic reduction in values.

The mean Total Leucocyte Count ($\times 10^3/\mu\text{L}$) (TLC) of groups-I, II and III was 7.93 ± 0.42 , 9.40 ± 0.14 and 10.01 ± 0.37 , respectively. In Group-I, a significant drop in TLC was observed after every cycle on day three following chemotherapy which increased linearly on day five and day 0 of the subsequent chemotherapeutic cycle. There was a drastic drop in TLC values in the two animals of Group-I, whereas it was moderate in the remaining 4 cases due to individual variation. The changes after each treatment were comparatively very minute in Group-II and insignificant in Group-III. The drop in the total leucocyte was primarily due to febrile neutropenia caused by the intravenous administration of Docetaxel (Kintzel *et al.*, 2006). Febrile neutropenia was observed on the third day after intravenous administration of a chemotherapeutic

agent in 3 cases of Group-I. However, the drop in neutrophils was nearer to physiological values, and an increase in TLC count was observed by day 7. In Group-II, no significant drop in the neutrophil count was observed as the drug was administered intratumorally.

In Group-I, a fall in platelet count was observed after each cycle on the third day. However, the values were within the normal physiologic range, and recovery was observed by the fifth day of each cycle. Amat *et al.* (2003) observed myelosuppression after Docetaxel in breast cancer in their study. They did not report any case of severe cardiac toxicity but thrombocytopenia which was within normal physiological limits. A slight depression in the value of RBC, TLC, neutrophils and platelets was observed following chemotherapy which could be attributed to myelosuppression.

Biochemical parameters: Statistically significant variation in Alanine Aminotransferase (ALT) (IU/L) values was observed between the three groups, in which the alterations were maximum in Group-I, followed by Group-II and III, respectively. The fluctuations in serum Aspartate Aminotransferase (AST) values were statistically insignificant, and no significant difference was observed between the three groups and within the respective cycles. In Group-I, serum alkaline phosphatase (ALP) enzyme the value increased drastically on the third day of chemotherapy, while in Group-II, the values increased with each cycle due to the presence of ZnO nanoparticles and Docetaxel as

Radiograph taken to Evaluate Pulmonary metastasis

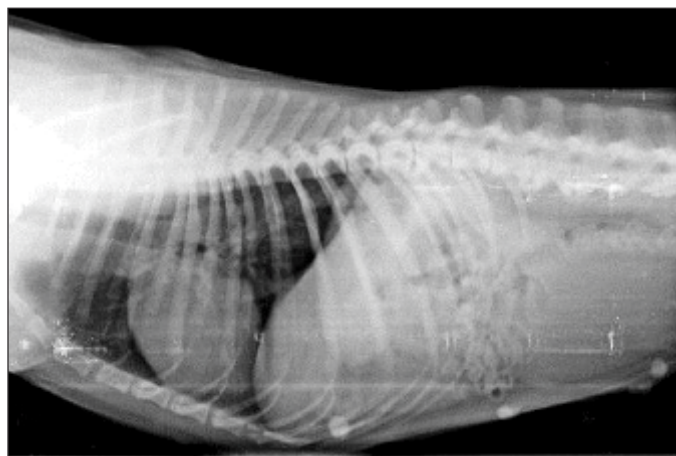


Fig. 1. Right Lateral view

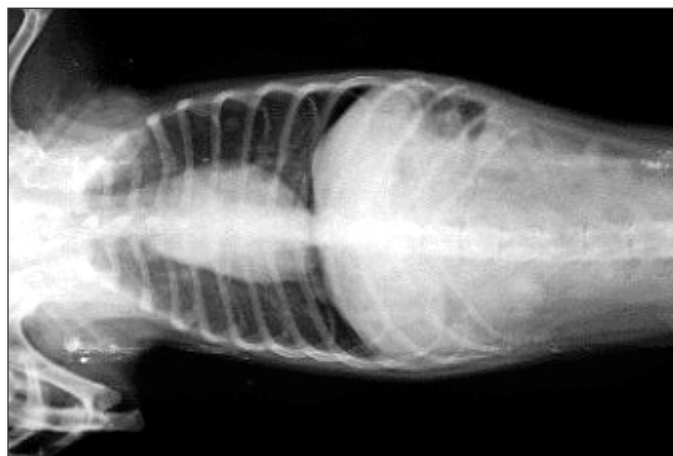


Fig. 2. Ventro-dorsal view

Regression of tumour in group-I

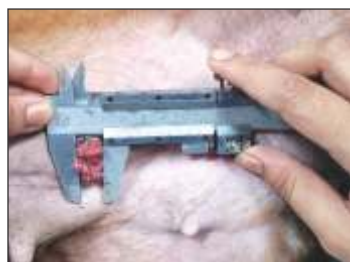

Fig. 3. Day 0

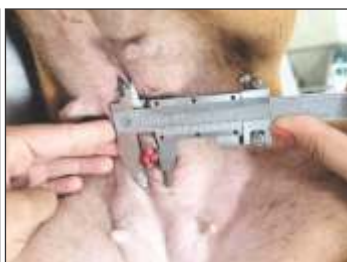

Fig. 4. Day 7

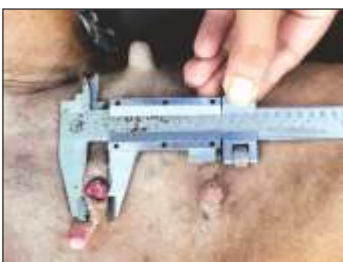

Fig. 5. Day 14

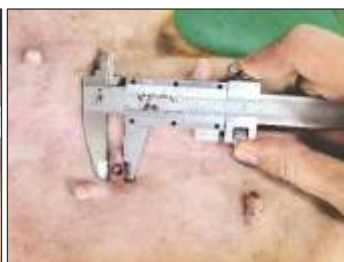

Fig. 6. Day 30

Regression of tumour in group-II

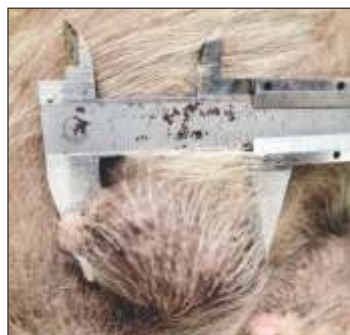

Fig. 7. Day 0



Fig. 8. Day 7

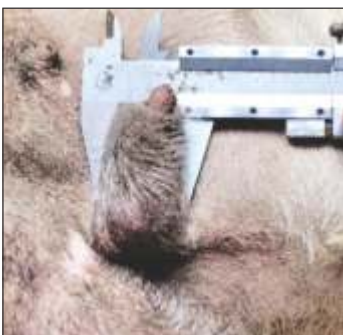

Fig. 9. Day 14

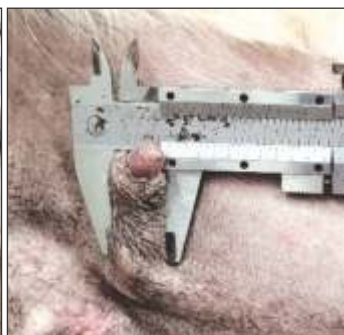

Fig. 10. Day 30

shown in Table 2. In Group III, the fluctuations were statistically insignificant.

The changes in serum BUN and creatinine levels were statistically insignificant, and no significant differences were seen between the three groups or within the corresponding cycles.

Radiography: Thoraco-abdominal radiographs were obtained in all dogs for evaluating lung metastases (Figs. 1 and 2). Out of the 18 cases included in this study, 5 (27.78%) cases showed significant metastatic lesions in the lung radiograph, 2 cases belonged to Group-I, and the remaining 3 cases were from Group-III of the study. In two cases of Group-I, lung metastasis was observed on day 0.

Subsequent radiographs revealed neither an increase nor decrease in lung metastasis following chemotherapy with intravenous Docetaxel. In cases where no metastatic lesions were observed on day 0, they remained unchanged and no new development of pulmonary metastasis was noticed.

Regression of tumour: The regression was compared between the two groups, Group-I and Group-II (Table 3). Tumour regression was shown to be statistically significant in both groups. The rate of tumour regression was more evident in Group-I (Figs. 3-6), showing that intravenous administration of docetaxel was significantly more effective than intratumoral administration of the Zinc

Oxide nanoparticle-docetaxel complex in causing regression. Although the adverse effects in Group-I were more significant than in Group-II (Figs. 7-10), the toxicity of docetaxel was found only in 2 cases in Group-I. The symptoms like fatigue, diarrhoea, and vomiting were reported, which subsided by the third day with therapeutic management. Three cases from Group-I animals were given a fourth dose of chemotherapy with intravenous Docetaxel injection. After the fourth dose, complete regression of the growth was observed in two cases, whereas in the third case, further reduction in the size of the tumour was observed.

Table3. Mean mammary tumour regression (%) at scheduled intervals in Group-I and II

Interval (days)	Mean size of growth (cm ³)%		%Growth		%Regression	
	Group I	Group II	Group I	Group II	Group I	Group II
0	32.75	32.75	100	100	0	0
7	17.34	20	52.95	60.07	47.05	38.93
14	8.89	16.48	29.44	50.32	70.56	49.68
30	6.77	13.26	20.68	40.49	79.32	59.51

Adverse effects of Chemotherapy: In the current study, five animals from group-I experienced symptoms of weakness and fatigue after intravenous administration of Docetaxel on the next day after chemotherapy, which subsided until day 5 with symptomatic management. In Group-II, no fatigue symptoms were observed after the drug's intratumoral administration. Febrile neutropenia is a severe condition associated with morbidity and mortality in patients undergoing chemotherapy and is more vulnerable to severe infections and requires hospitalisation. Two cases of Docetaxel toxicity were observed in Group-I. Vomiting and loose faeces with a small amount of blood were noticed in the first case of Group I on the third day, but these symptoms decreased by the fifth day in the second and third cycles. In the later case, frequent hematochezia was seen from the second day of each cycle onwards, which was gradually reduced by day 5. The administration of subsequent dosages was postponed until the dog's normal health status had returned.

Accordingly, the subsequent chemotherapy cycle was delayed in three dogs of group-I until the stabilisation

of hemato-biochemical parameters such as neutropenia, leukocytopenia, and increased values of ALP. Similar findings were observed by Shi *et al.* (2015) wherein, loose/watery stools and soft faeces were noted within the first 30 minutes after the intravenous DTX injection group in the studies on beagles.

CONCLUSION

Based on investigated parameters it is concluded that, intratumoral Zinc Oxide Nanoparticle Conjugated Docetaxel was effective in reversing mammary tumours, especially in older animals and those with compromised health status. The intravenous administration of docetaxel is more effective than intratumoral administration due to a faster regression rate and improved efficacy. Also, the adverse effects were manageable with the required supportive treatment and premedication. Intratumoral delivery of ZnO nanoparticle Docetaxel Complex was preferable, particularly in older animals and dogs having compromised health status who might not tolerate intravenous chemotherapy. Surgical excision is an effective method for the treatment of benign and non-metastatic larger-sized mammary tumours.

REFERENCES

- Adams, V.J., Evans, K.M., Sampson, J. and Wood, J.L.N. (2010). Methods and mortality results of a health survey of purebred dogs in the UK. *J. Small Anim. Pract.* **51(10)**: 512-524.
- Amat, S., Bougnoux, P., Penault-Llorca, F., Fétissov, F., Curé, H., Kwiatkowski, F. and Chollet, P. (2003). Neoadjuvant docetaxel for operable breast cancer induces a high pathological response and breast-conservation rate. *British J. Cancer*. **88(9)**: 1339-1345.
- Kintzel, P.E., Michaud, L.B. and Lange, M.K. (2006). Docetaxel associated epiphora. *Pharmacotherapy: J. Human Pharmacology and Drug Therapy*. **26(6)**: 853-867.
- Shi, J., Zhang, J., Shen, Y., Tang, L., Zhao, J., Tu, J. and Feng, Y. (2015). Arginine-stabilized mPEG-PDLLA (50/50) polymeric micelles of docetaxel by electrostatic mechanism for tumor-targeted delivery. *Drug Delivery*. **22(2)**: 168-181.
- Simon, D., Schoenrock, D., Baumgärtner, W. and Nolte, I. (2006). Postoperative adjuvant treatment of invasive malignant mammary gland tumors in dogs with doxorubicin and docetaxel. *J. Vet. Inter. Med.* **20(5)**: 1184-1190.
- Sorenmo, K.U., Rasotto, R., Zappulli, V. and Goldschmidt, M.H. (2011). Development, anatomy, histology, lymphatic drainage, clinical features, and cell differentiation markers of canine mammary gland neoplasms. *Vet. Pathol.* **48(1)**: 85-97.