

AN OUTBREAK OF *ARGAS PERSICUS* IN A FLOCK OF GAME FOWL- ASEELRABJOT KOUR, DEEPAK SUMBRIA*, ANAND PRAKASH¹, JASLEEN KAUR² and VIKRANT SUDANDepartment of Veterinary Parasitology, ¹Department of Livestock Farm Complex,²Department of Veterinary Medicine, College of Veterinary Science,

Guru Angad Dev Veterinary and Animal Sciences University (GADVASU), Rampura Phul, Punjab-151103, India

Received: 27.07.2023, Accepted: 14.10.2023

SUMMARY

Soft fowl tick - *Argas persicus* is a serious menace for poultry industry. Once a flock is infested, it is very difficult to eliminate the tick and it persists for many generations. The present communication describes an outbreak of *A. persicus* in game bird -Aseel in a poultry farm at Malerkotla (Punjab). The important morphological features of different stages of tick, as well as, its control are described herewith. This appears to be the first case report describing *A. persicus* on Aseel birds.

Keywords: *Argas persicus*, Aseel, Female tick, Larvae, Male tick, Propoxur

How to cite: Kour, R., Sumbria, D., Prakash, A., Kaur, J. and Sudan, V. (2024). An outbreak of *Argas persicus* in a flock of game fowl-Aseel. *The Haryana Veterinarian* 63(SI): 148-150.

Tick such as Fowl tick or poultry tick or blue tick, *Argas persicus* is a serious threat to poultry industry (Khan *et al.*, 2001; Zahid, *et al.*, 2021). The tick belongs to the family of soft ticks-Argasidae. These ticks are commonly found in warm and arid regions, particularly in the Middle East, Africa, and parts of Asia (Petney *et al.*, 2004) and are known to infest a variety of bird species, including domestic poultry like chickens, turkeys, and ducks (Pfäffle and Petney, 2017). As far as Indian scenario is concerned, the tick is reported particularly in the northern and western parts of the country, where the climate is more suitable for its survival (Miranpuri *et al.*, 1975). Even though it is present throughout India, a search of the literature finds only few reports of it in relation to the Indian environment.

Fowl ticks are known to cause several problems in poultry. They primarily cause irritation, discomfort, and stress to the birds, leading to decreased productivity, weight loss and decreased egg production (Taylor *et al.*, 2016). In severe infestations, fowl ticks can cause anaemia, develop severe skin lesions, and even death of young or weak birds (Soulsby, 1982; Bhatia *et al.*, 2016; Taylor *et al.*, 2016). Desi/local breeds of poultry alongside, game birds are considered to be hardy and comparatively resistant to parasites. The present communication reports an outbreak of *Argas persicus* ticks in a flock of Assel: the game bird from Malerkotla (Punjab).

In India Punjab state has total geographical area of 50,362 km² and is situated at 293° 302' N and 323° 322' N latitude, 733° 552' E and 763° 502' E longitudes with elevation of 300 meters (980 ft) above sea level, along with a range from 180 meters (590 ft) in the southwest to more than 500 meters (1,600 ft) around the northeast border. This state is further divided into 5 major agro-climatic

zones (Sub-mountain undulating zone, undulating plain zone, central plain zone, western zone, western plain zone) on the bases of variation in climatic, edaphic and agricultural pattern and is alienated into 23 districts. The present outbreak was reported from Malerkotla district of Punjab (Fig. 1A). This district falls under the central plain zone and lies at a latitude of 30° 31' 23.55" N and a longitude of 75° 53' 17.7" E or 30.523208 and 75.888251, respectively.

The owner is maintaining a pure line of Aseel birds for many years. They had maintained a flock of 62 birds at the time of outbreak. As per the owners, 42 birds succumbed to the tick infestation during the last one year. As per the information provided by the owner, he had tried various acaricides such as cypermethrin, organophosphates, etc., but none of the acaricide was able to completely curb the infestation. Although he reported temporary reliefs but the infestation re-established over and over again. Ticks and their developmental stages were collected from on and off the hosts and brought to the laboratory of the Department of Veterinary Parasitology, College of Veterinary Science, GADVASU, Rampura Phul, Bathinda, Punjab for the detailed identification. The ticks were identified as per Soulsby (1982) and Kettle (1984) and subsequently drug regime was prescribed to the owner to tackle the infestation both on and off the host.

The ticks and their developmental stages were identified as *Argas persicus* species based on the morphological features described by Kettle (1984). The ticks were small, flat, and oval-shaped (Fig. 1E, H), having a bluish-gray or blue-black coloration (Fig. 1E), accounting for their name 'blue tick' (Soulsby, 1982; Marchiondo *et al.*, 2019). During gross examination of bird, ticks were noticed at various regions such as under the wings (Fig.

*Corresponding author: deepak_sumbria@yahoo.com

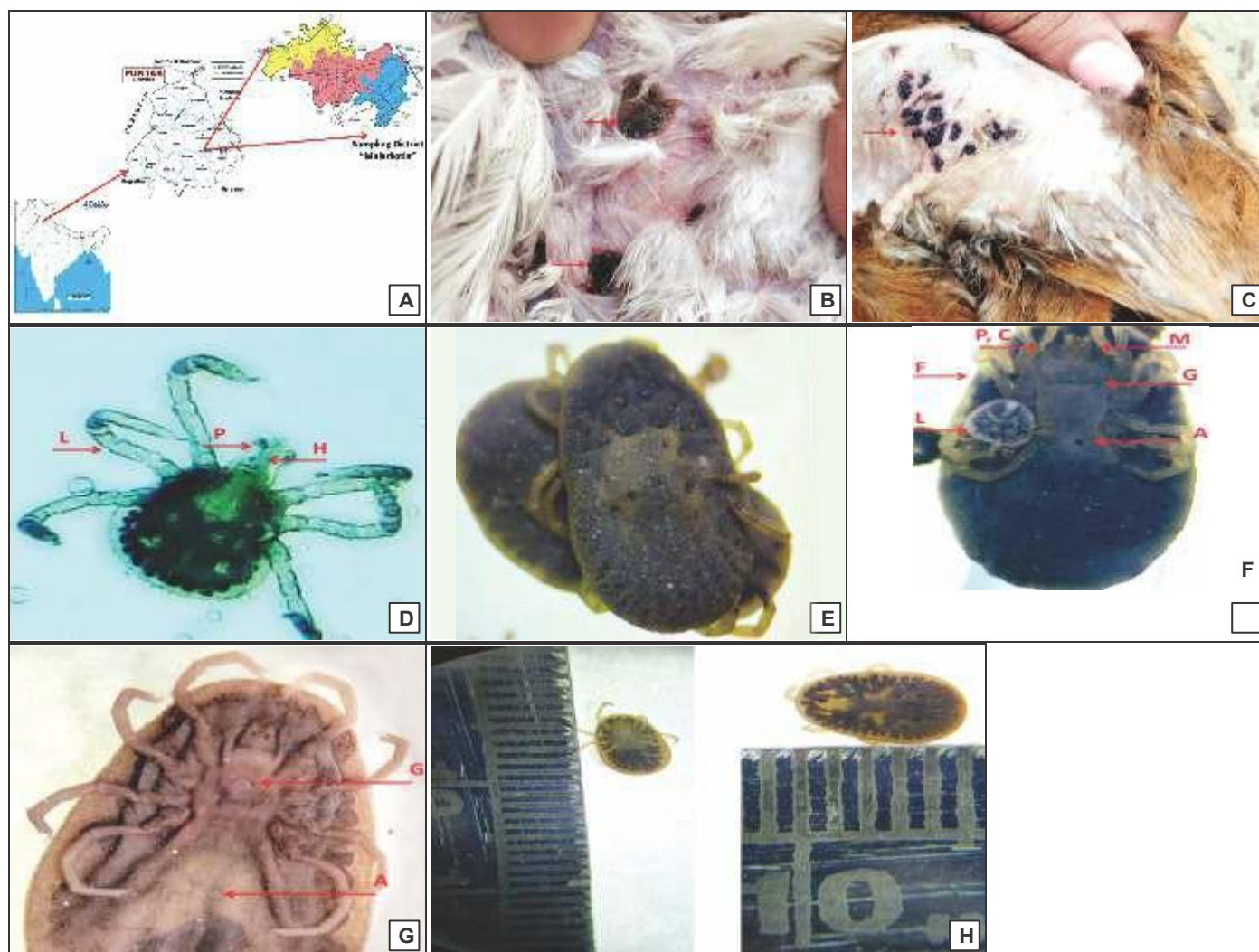


Fig. 1. (A) Map of Punjab (inset in map of India) showing the Malerkotla district where the outbreak had taken place; (B) Ticks under the wings (arrow); (C) Ticks underside of leg (arrow); (D) Larva (unfed) of *Argas persicus* tick showing anteriorly situated mouthparts such as palpi (P) and hypostome (H), three pairs of legs (L); (E) Dorsal view of *Argas persicus* having leathery investment with a finely granular surface; (F) Maternal-like behaviour of tick, larvae (L) were found to remain on the female's ventral surface (F), Anus (A), Pulvillus (P), Claws (C), horizontal slit like genital aperture (G), Mouth (M); (G) Ventral view of male *Argas persicus*. Semi-circular genital aperture (G), Anus (A); (H) Dorsal and ventral view of *Argas persicus*

1B) and thigh (Fig. 1C). Microscopic examination of larva and adult stages of tick was also performed. Unfed larva stage depicted presence of three pairs of legs along with well-developed palpi and hypostome (Fig. 1D). Dorsal surface of adult tick showed leathery appearance and granular surface (Fig. 1E). Female ticks were also observed showing maternal behaviour with larvae (Zahid *et al.*, 2021), they also had pulvillus and claws on legs (Fig. 1F). Female and male tick showed characteristic horizontal and semi-circular genital aperture respectively, moreover they were oval in shape and broader posteriorly than anteriorly (Fig. 1F, G). Dorsal and ventral view of ticks also revealed characteristic features (Fig. 1H). All these characters of ticks were concordant to various previous studies (Soulsby, 1982, Kakarsulemankhel, 2010, Mallesh *et al.*, 2018).

The owner was advised dusting of birds with

propoxur. The poultry farm was heavily infested and was made up of wooden frame. Older wood blocks with a high tick infestation were burned by the owner (Fig. 1B, C). In addition, it was recommended to use deltamethrin to spray the area to manage the host's developmental stages. *Argas persicus* being nocturnal parasite, the owner was suggested to perform dusting as well as spraying of premises during night hours so that maximum population of ticks could be exposed to the treatment.

Barring a few reports (Miranpuri *et al.*, 1975; Bhat *et al.*, 2014; Mallesh *et al.*, 2017), not enough literature is available to adjudge the actual scenario of soft ticks infestation of poultry in India. Additionally, the authors did not find any citable reference of soft tick infestation on game birds. Infestation of *A. persicus* is known to last for years in a flock (Zahid *et al.*, 2021) and can cause big nuisance. The

owner was practicing only on the host measures and no attention was paid to the off hosts stages. This accounted for the long persistence of ticks in the instant case. Extrinsic factors like humidity, temperature and stocking density of birds coupled with availability of hidden spaces for the developmental stages affects the life cycle as well as severity of infestation of soft ticks (Randolph, 2009; Leger *et al.*, 2013). During unfavourable conditions, *A. persicus* is known to starve for several years, reduces dehydrations and enters diapause in cracks and crevices (Walker *et al.*, 2003; Zahid *et al.*, 2021).

In conclusion, present communication describes outbreak of the soft tick *A. persicus* in a flock of game birds of Aseel breed and as per best of our knowledge this was the first report from Punjab, India. Over time, the owner experienced a significant number of deaths as a result of this tick's infection. The mistake was rectified and the ticks were managed both on and off the host using dust and spray with propoxur and deltamethrin, respectively.

REFERENCES

- Bhat, S.A., Wani, M.Y., Khajuria, J.K., Katoch, R. and Dhama, K. (2014). A rare report of ectoparasites in backyard poultry in Jammu region: prevalence study and economic importance. *Asian J. Animal Vet. Adv.* **9**: 727-731.
- Bhatia, B.B., Pathak, K.M.L. and Juyal, P.D. (2016). Textbook of Veterinary Parasitology, Kalyani Publishers, New Delhi.
- Kakarsulemankhel, J.K. (2010). Re-description and new record of *Argas (persicargas) persicus* (Oken, 1818) (Acarina: Argasidae) from Balochistan, Pakistan. *Pak. Entomol.* **432(2)**: 82-94.
- Kettle, D.S. (1984). Medical and veterinary entomology, CAB International, Wallingford, Oxon, UK.
- Khan, M.N., Khan, L.A., Mahmood, S. and Qudoos, A. (2001). *Argas persicus* infestation: prevalence and economic significance in poultry. *Pak. J. Agri. Sci.* **38**: 3-4.
- Leger, E., Vourc'h, G., Vial, L., Chevillon, C. and McCoy, K.D. (2013). Changing distributions of ticks causes and consequences. *Exp. Appl. Acarol.* **59**: 219-244.
- Malles, P., Kumar, M.U., Murthy, G.S.S. and Lakshman, M. (2017). Ultrastructural Studies on *Argas persicus*. *Intl. J. Livestock Res.* **7(9)**: 159-166.
- Malles, P., Kumar, M.U., Murthy, G.S.S. and Lakshman, M. (2018). Occurrence of *Argas persicus* infestation in poultry farms in and around Hyderabad, Telangana. *Pharma Innovation.* **7(4)**: 118-120.
- Marchiondo, A.A., Cruthers, L.R. and Fourie, J.J. (2019). Parasiticide Screening. *Chapter 4- Arachnida*, **1**: 257-377.
- Miranpuri, G.S., Bindra, O.S. and Prasad, V. (1975). Tick fauna of north-western India (Acarina : Metastigmata). *Int. J. Acarol.* **1(1)**: 31-54.
- Petney, T.N., Andrews, R.H., McDiarmid, L.A. and Dixon, B.R. (2004). *Argas persicus* sensu stricto does occur in Australia. *Parasitol Res.* **93(4)**: 296-299.
- Pfäffle, M.P. and Petney, T.N. (2017). *Argas persicus* (Oken, 1818) (Figs. 2 & 3). In: Estrada-Peña, A., Mihalca, A., Petney, T. (Eds) Ticks of Europe and North Africa. Springer, Cham.
- Randolph, S.E. (2009). Epidemiological consequences of the ecological physiology of ticks. *Adv. Insect Physiol.* **37**: 297-339.
- Soulsby, E.J.L. (1982). Helminths, arthropods and protozoa of domesticated animals. (7th Edn.), The English Language Book Society and Bailliere, Tindall, London, UK.
- Taylor, M.A., Coop, R.L. and Wall, R.L. (2016). Veterinary Parasitology (4th Edn.), Wiley-Blackwell.
- Walker, A.R., Bouattour, A., Camicas, J.L., Estrada-Peña, A., Horak, I.G. and Latif, A.A. (2003). Ticks of Domestic Animals in Africa: A Guide to Identification of Species. *Edinburgh: Biosci Reports.* 3-210.
- Zahid, H., Muñoz-Leal, S., Khan, M.Q., Alouffi, A.S., Labruna, M.B. and Ali, A. (2021). Life cycle and genetic identification of *Argas persicus* infesting domestic fowl in Khyber Pakhtunkhwa, Pakistan. *Front. Vet. Sci.* **8**: 664731.

THE HARYANA VETERINARIAN

Editors/Editorial Board Members are highly thankful to all the distinguished referees who helped us in the evaluation of articles. We request them to continue to extend their co-operation and be prompt in future to give their valuable comments on the articles for timely publication of the journal.