

AN INVESTIGATION ON AN OUTBREAK OF SYSTEMIC ASPERGILLOSIS IN POULTRY BIRDS AND ITS MANAGEMENT

RAHUL SINGH, RAKESH KUMAR*, ANMOL BISHT, SMRITI JAMWAL, ANKITA, ABHISHEK VERMA and R.K. ASRANI

Department of Veterinary Pathology, Dr. G.C. Negi College of Veterinary and Animal Sciences, CSKHPKV, Palampur, Himachal Pradesh, India-176062

Received: 25.08.2023, Accepted: 22.11.2023

SUMMARY

The present study was done with the aim of investigating an outbreak on a poultry farm. The birds kept on the poultry farm exhibited signs of ruffled feathers, anorexia, soundless gasping and dyspnoea. A total of 13 Kadaknath and 7 Delham Red breed dead birds were necropsied in the Department of Veterinary Pathology and showed several tiny, variable-sized, white-yellowish nodules on the lungs, air sacs and intestine. Histological evaluation of the stained tissue sections of the lungs reflected the presence of multiple granulomas comprising a central necrotic area, along with the infiltration of heterophils and giant cells. Fungal hyphae were also observed to invade peri-bronchiolar and interstitial tissue in association with haemorrhages in the lung sections. On inoculation on Sabouraud Dextrose Agar (SDA) plate, velvety colonies which were green in the centre and white at the periphery were observed. The use of copper sulphate as a therapeutic agent and the replacement of the litter in the poultry resulted in a dramatic decline in the mortality. The present outbreak was identified as systemic aspergillosis on the basis of clinical manifestations, gross and microscopic lesions and fungal isolation.

Keywords: Aspergillosis, Delham Red, Granuloma, Kadaknath, Pathology

How to cite: Singh, R., Kumar, R., Bisht, A., Jamwal, S., Ankita, Verma, A. and Asrani, R.K. (2024). An investigation on an outbreak of systemic aspergillosis in poultry birds and its management. *The Haryana Veterinarian* 63(SI): 119-122.

Aspergillosis has been reported in a wide range of avian species around the world, and probably all birds are vulnerable to this infection (Tell, 2005). Aspergillosis is one of the most common fungal diseases of avian respiratory system and sometimes infection may spread to the visceral organs as well. It is a fungal disease caused by different species of the widespread opportunistic saprophytic genus *Aspergillus*, specifically *Aspergillus fumigatus* (Barnes and Denning, 1993). Similar invasive mycosis can be produced by other species of fungi including *Aspergillus flavus*, *Aspergillus niger*, *Aspergillus glaucus* and *Aspergillus terreus*. These organisms flourish on organic matter in a warm (25° C) humid environment, such as chicken litter, feed, hatchery-damaged eggs and poorly ventilated systems. Aviary litter is abundant in organic materials, which promotes the proliferation and sporulation of *Aspergillus fumigatus*, resulting in the production of a large number of conidia that can remain active in the environment for a long time and are easily distributed in the air (Arne *et al.*, 2011). The primary virulence factor associated with the pathogenesis of *Aspergillus fumigatus* is the tiny size of its conidia (2-10 µm), which facilitates inhalation and colonisation of the terminal airways of the susceptible birds (De Oca *et al.*, 2017). Stress-induced immunosuppression is a key factor associated with the vulnerability of birds to mycotic infections. Poor husbandry practices, undernourishment, pre-existing illness, and the long-term use of antibiotics

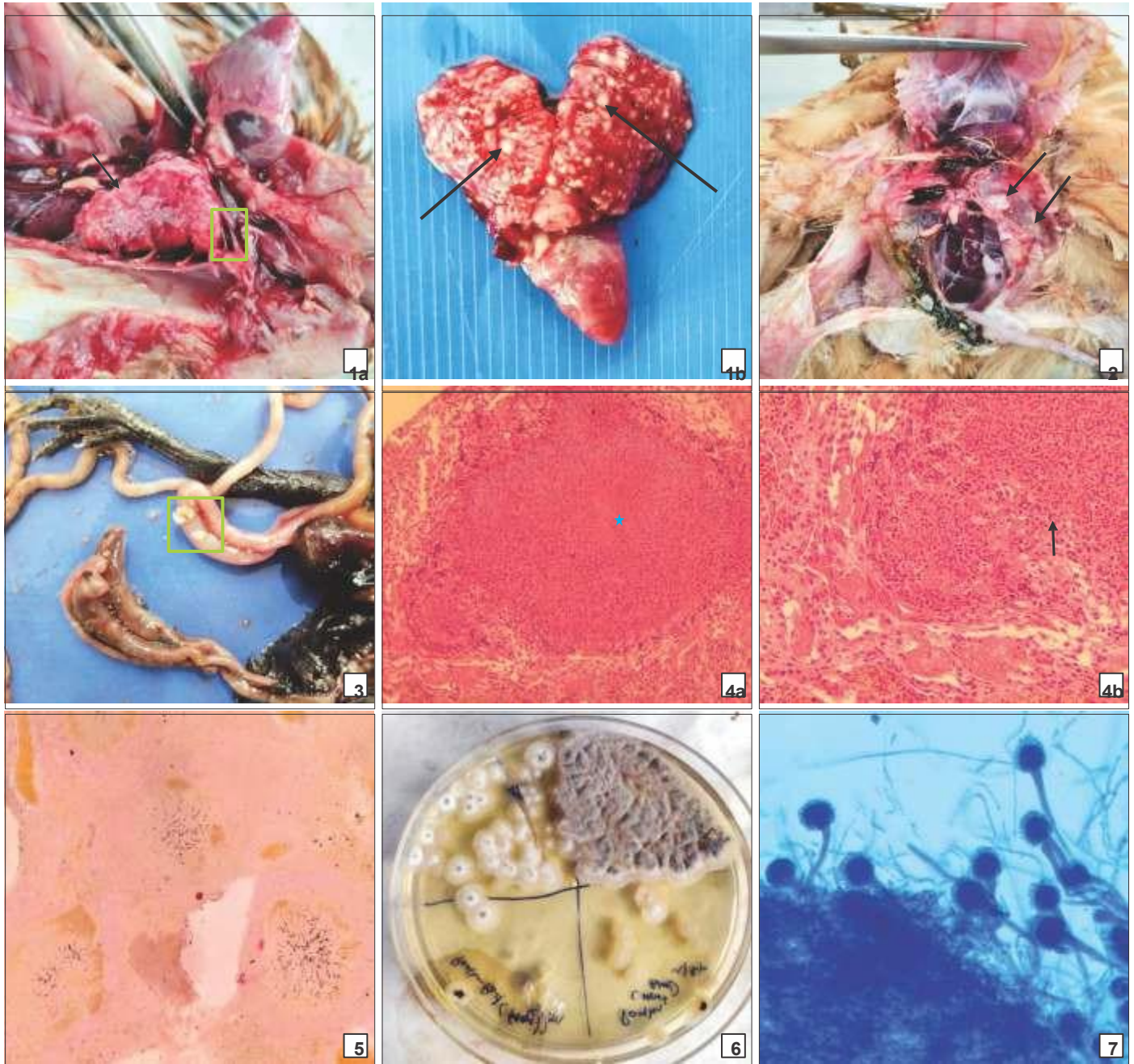
and steroids, all aggressively increases the susceptibility of birds to mycotic infections. The present manuscript addresses the pathology of aspergillosis in a poultry flock.

This study was conducted to identify the cause of mortality in poultry chicks submitted for post-mortem examination to the Department of Pathology, DGCN COVAS, CSKHPKV, Palampur (Himachal Pradesh). The affected flock was visited, and clinical symptoms were documented.

Dead birds were systematically inspected during necropsy following a standard protocol for diagnosis (Julian and Boulianne, 2013). The physical condition of the carcasses as well as evident gross pathological lesions of the organs were documented. The representative tissue samples (lungs) of approximate thickness of 5 mm were taken during necropsy and preserved in 10% neutral buffered formalin for histopathological examination. Following appropriate fixation, paraffin embedded tissue sections of 4-6µ thickness were obtained and stained for microscopic examination using the routine Haematoxylin & Eosin technique (Luna, 1968). Grocott's methenamine silver (GMS) staining technique was used on duplicate sections to confirm the presence of fungi in the lung tissues (Luna, 1968). Direct microscopic evaluation was carried out in the impression smear from lungs using Lactophenol cotton blue stain to detect the fungus.

Aspergillus fumigatus was isolated from the affected organs such as the lung and airsac. The samples were

*Corresponding author: rkvetpath@gmail.com



Figs. 1 to 7. **(1a)** Lungs reflecting adhesions (Box) with thoracic wall along with caseous nodules (Black Arrow). **(1b)** White-yellowish, circumscribed, raised, multifocal to coalescent, variable sized caseous nodules in the lungs.; **(2)** White to yellowish nodules of varying sizes evident on thoracic and abdominal air sacs.; **(3)** White and yellowish, raised, variable sized caseous nodules evident on the serosal surface of the intestine. ; **(4a)** Lung: Granuloma characteristic of aspergillosis, exhibiting eosinophilic central necrosis (star) encapsulated by thin layer of fibrous tissue (H&E*40x).; **(4b)** Intralesional septate hyphae, similar to the letter “Y” (arrow), morphologically compatible with *Aspergillus* spp. (H&E*400x).; **(5)** Pulmonary granulomas: Evidence of black coloured septate fungal hyphae through silver impregnation of the external wall of the fungus (GMS Staining*40X). ; **(6)** Velvety colonies on 4th day post incubating showing central green zone and white peripheral zone depicting colony characteristics of *Aspergillus fumigatus* (SDA). ; **(7)** Conidiophores of *Aspergillus fumigatus* with semispherical and dome shaped swollen apex bearing conidia, metulae, and phialides (Lactophenol cotton blue staining 400x).

directly streaked on Sabouraud Dextrose Agar (SDA) plates and incubated for 5 days at 37° C. The characteristics colony features and the microscopic appearance of fungi were used for identification of *Aspergillus* species. Direct slides were also prepared from culture for identification of mycelium and hyphae organisation and were examined by the wet mount method using the Lactophenol cotton blue

staining method (Karunakaran *et al.*, 2010).

The affected birds showed general clinical indications of aspergillosis, which included ruffled feathers, anorexia, increasing emaciation and dehydration. The affected birds exhibited moderate to severe dyspnoea, gasping and death. The findings are consistent with previous studies that indicated dyspnoea, gasping and nasal discharge in the

acute type of aspergillosis (Sajid *et al.*, 2006; Arne *et al.*, 2011).

Dead birds upon post-mortem examination revealed the presence of multifocal, well-demarcated, white-yellowish caseous nodules in the lungs (Fig. 1A and Fig. 1B), air sacs (Fig. 2) and intestines (Fig. 3). The nodules were variable in size, ranging from 2-10 mm in diameter. The lung parenchyma had become consolidated. There have been reports of similar findings of nodular lesions in the lungs (Latge, 2001, Akan *et al.*, 2002).

Microscopic investigation of lung histopathology revealed multifocal-to-coalescent granulomatous reaction having eosinophilic central necrotic area along with the infiltration of heterophils, macrophages, and giant cells encapsulated by the fibrous tissue layer (Fig. 4A). Numerous Y-shaped intralesional septate hyphae were observed (Fig. 4B) which are morphologically consistent with *Aspergillus* spp. Haemorrhages were observed in peribronchiolar and interstitial tissue. The duplicate section stained with Grocott methenamine silver staining technique clearly demonstrated hyphae of regular diameter, with septations into dichotomous branches, typically at acute angles similar with *Aspergillus fumigatus* (Fig. 5).

On the 4th day post-incubation on SDA, gross examination of petri dishes revealed velvety colonies with a green central area surrounded by a white zone at the periphery (Fig. 6). The colonies were examined by placing the fungal culture between a slide and coverslip, using a sterile loop. They were then stained with lactophenol cotton blue and observed under magnifications ranging from 100x to 400x. The examination revealed unbranched fungal hyphae bifurcating at a 45° angle, featuring distinctive conidiophores with a dome-shaped swollen vesicle at the tip and bearing lengthy chains of conidia, metulae, and phialides (Fig. 7).

Aspergillus thrives in moist soils, decomposing materials, organic detritus, and free grains. Species of *Aspergillus*, in particular, sporulate profusely, with each conidial head releasing hundreds of conidia into the atmosphere with a diameter tiny enough to reach the alveoli of the lungs via the upper respiratory tract. If spores are concentrated in the lungs, the fungi can spread to other regions of the body, causing either localised or systemic infections that typically result in death (Powell *et al.*, 1994). Immuno-suppression is a crucial component that makes birds more susceptible to infection. Stress, in combination with other variables such as confinement, poor husbandry practices, starvation, pre-existing sickness and the prolonged use of antibiotics and steroids, increases susceptibility. In the current investigation, the condition

was diagnosed based on history, clinical manifestations, gross and microscopic examination, and fungus isolation. The litter material (paddy straw mixed with sawdust) readily absorbs moisture and may act as a good medium for the proliferation of *Aspergillus*, leading to disease. Granulomatous nodular lesions are commonly restricted to the lungs and air sacs. Our findings are consistent with others who discovered that lesions in birds are frequently restricted to the lungs and air sacs (Charlton *et al.*, 2008). The lung's histopathology revealed granulomas with eosinophilic necrotic cores surrounded by heterophils and giant cells. These findings have already been reported by others (Islami *et al.*, 2009). The disease condition might have occurred due to improper hygiene and sanitation with improper ventilation and high humidity, which led to mouldy litter. The affected birds were treated using copper sulphate solution. Copper sulphate was administered orally at a rate of 1g per litre, twice daily in water, for a period of 7 days. To disinfect the premises, the Bordeaux mixture was sprayed as a fungicide (Agrios, 2005). The mixture was prepared by individually adding 1 kg of copper sulphate (CuSO₄) and 1 kg of slaked lime (Ca(OH)₂) to 10 litres of water, allowing each solution to stand overnight. On the next day, both solutions were strained, combined, and the final volume was adjusted to 15 litres for spraying. Concurrently, the old litter material (paddy straw mixed with sawdust) of the flock was replaced with fresh litter. Furthermore, griseofulvin can also be given at the dose rate of 2 mg/litre via drinking water for 5 days. The copper sulphate treatment of the flock along with litter replacement was found to be beneficial, as the severity of the clinical signs in the affected birds decreased on the third day and recovered fully within 5-7 days of treatment initiation (Srinivasan *et al.*, 2014).

We can conclude that aspergillosis in poultry can cause significant mortality in a short span of time, leading to high economic losses. So, it becomes essential to diagnose the disease as early as possible by observing clinical signs along with the systematic necropsy of dead birds. After tentative diagnosis, adoption of therapeutic approach along with managerial improvisation reduces mortality significantly and thus preventing the poultry farm from economic crisis.

REFERENCES

- Agrios, G.N. (2005). Plant Pathology. (5th Edn.), Academic Press, New York, U.S.A. pp. 293-353.
- Akan, M., Hazieoglu, R., Ilhan, Z., Sareyyupoglu, B. and Tunca, R. (2002). A case of aspergillosis in a broiler breeder flock. *Avian Dis.* **46**(2): 497-501.
- Arne, P., Thierry, S., Wang, D., Deville, M., Le Loc'h, G., Desoutter, A., Femenia, F., Nieguitsila, A., Huang, W., Chermette, R. and

- Guillot, J. (2011). *Aspergillus fumigatus* in poultry. *Int. J. Microbiol.* doi: 10.1155/2011/746356.
- Barnes, A.J. and Denning, D.W. (1993). Aspergilli-Significance as pathogens. *Rev. Med. Microbiol.* **4(3)**:176-180.
- Charlton, B.R., Chin, R.P. and Barnes, H.J. (2008). Fungal infections. In: Diseases of Poultry. Saif, Y.M. (12th Edn.). Iowa State Press, Ames, Iowa, U.S.A. pp. 989-1008.
- De Oca, V.M., Valdes, S.E., Segundo, C., Gomez, G.G., Ramirez, J. and Cervantes, R.A. (2017). Aspergillosis, a natural infection in poultry: mycological and molecular characterization and determination of gliotoxin in *Aspergillus fumigatus* isolates. *Avian Dis.* **61(1)**: 77-82.
- Islami, M.N., Rashid, S.M.H., Juli, M.S.B., Rima, U.K. and Khatun, M. (2009). Pneumomycosis in chickens: Clinical, Pathological and therapeutical investigation. *Int. J. Sustain. Crop Prod.* **4(3)**: 16-21.
- Julian, R.J. and Boulianne, M. (2013). Necropsy of the fowl: In: Avian Disease Manual. Boulianne, M. (7th Edn.), The American Association of Avian Pathologists, Jacksonville, Florida, U.S.A. pp. 268-272.
- Karunakaran, S., Nair, G.K., Nair, N.D. and Mini, M. (2010). Systemic aspergillosis in Emu chicks in an organised farm in Kerala. *Vet. World.* **3(10)**: 453-455.
- Latge, J.P. (2001). The pathobiology of *Aspergillus fumigatus*. *Trends Microbiol.* **9(8)**: 382-389.
- Luna, L.G. (1968). Manual of Histologic Staining Methods of the Armed Forces Institute of Pathology. (3rd Edn.), Mc Graw Hill Book Co, New York, U.S.A.
- Powell, K.A., Renwick, A. and Peberdy, J.F. (1994). The genus *Aspergillus*: from taxonomy and genetics to industrial application (1st Edn.), Plenum Press, New York, U.S.A.
- Sajid, M.A., Khan, I.A. and Rauf, U. (2006). *Aspergillus fumigatus* in commercial poultry flocks, a serious threat to poultry industry in Pakistan. *J. Anim. Pl. Sci.* **16(3-4)**: 79-81.
- Srinivasan, P., Murthy, T.R., Gopalkrishna., Saravanan, S., Balachandran, P., Mohan, B., Gowthaman, V. and Mohana, N. (2014). An outbreak of pulmonary aspergillosis in emu (*Dromaius novaehollandiae*) chicks. *Indian J. Vet. Pathol.* **38(3)**: 207-210.
- Tell, L.A. (2005). Aspergillosis in mammals and birds: Impact in veterinary medicine. *Med. Mycol.* **43(1)**: 71-73.

CONTRIBUTORS MAY NOTE

- Research/Clinical articles are invited for next issue from the Scientists/Veterinarians engaged in Veterinary Profession.
- Please follow strictly the format of 'The Haryana Veterinarian' for manuscript writing/submission.
- Please pay processing fee of Rs. 1200/- online in the account of Dean, College of Veterinary Sciences, along with each article.
- After revision, please return the revised manuscript and rebuttal at the earliest.
- Please mention your article reference number in all correspondence for a quick response.
- We solicit your co-operation.
- All correspondence should be addressed to 'The Editor', Haryana Veterinarian, Department of Veterinary Parasitology, College of Veterinary Sciences, LUVAS, Hisar-125004.

Editors