

DIAGNOSIS AND MANAGEMENT OF INTESTINAL OBSTRUCTION DUE TO FIBROUS BAND IN CATTLE

SUKHNANDAN SINGH^{1*} and H.R. BHARDWAJ²Division of Veterinary Surgery and Radiology, Faculty of Veterinary Sciences,
Sher-e-Kashmir University of Agricultural Sciences and Technology, Jammu (SKUAST-J), R.S. Pura-181102, India

Received: 15.05.2022; Accepted: 04.07.2022

SUMMARY

The present case report includes four-year Holstein Friesian cross-bred cattle with a history of colic followed by cessation of faeces. It was diagnosed as a case of intestinal obstruction due to fibrous band on exploratory laparotomy which was later resected to relieve the obstruction. The animal recovered uneventfully without any post-operative complication. It is concluded that exploratory laparotomy in cattle can be considered a diagnostic and therapeutic approach specially in intestinal obstructions.

Keywords: Cattle, Exploratory laparotomy, Fibrous band, Intestinal obstruction

How to cite: Singh, S. and Bhardwaj, H.R. (2023). Diagnosis and management of intestinal obstruction due to fibrous band in cattle. *Haryana Vet.* 62(SI): 117-118.

Among the various abdominal surgical affections, intestinal obstruction (IO) represents a potentially life-threatening condition of affected animals (Khalphallah *et al.*, 2016). There are two common types of intestinal obstruction interrupting the flow of intestinal contents that are recognized in large ruminants: these are mechanical and functional obstruction (Radostits *et al.*, 2007; Khalphallah *et al.*, 2016). Mechanical intestinal obstruction may be luminal or extra-luminal. Luminal obstructions include hemorrhagic jejunitis (occlusion of jejunum with blood clots); phytobezoars; cecocolic volvulus; impacted ingesta and atresia coli, recti, and ani. Obstructions due to occlusion of the lumen by extra luminal masses such as fibrous bands and adhesions (Sodhi *et al.*, 2019), whereas intussusceptions, strangulation and volvulus of the gastrointestinal tract as well as intestinal compression with an expanding abdominal mass such as lymphosarcoma or fat necrosis are the causes of extraluminal obstruction (Dharmaceelan *et al.*, 2012; Hussain *et al.*, 2015). Haematological examinations are hemoglobin (12.5 gram%), total erythrocyte count (7.02×10^6 /cubic millimeter), packed cell volume (37.6%) and platelet (419×10^3 /cubic millimeter) with. Marked neutrophilic (neutrophils 96%) leukocytosis (total leucocyte count was 18600/cubic millimeter) and corresponding lymphopenia (lymphocytes 4%) giving an interpretation of neutrophilic leukocytosis with many toxic neutrophils and left shift (Sodhi *et al.*, 2019). This report presents a case of four-year-old Holstein Friesian cattle with signs of intestinal obstruction by a fibrous band, subsequently diagnosed and surgically treated by standing right flank laparotomy under local anaesthesia.

Four-year-old Holstein Friesian cross-bred cattle was presented with the history of colic, cessation of faeces,

anorexia, reduced water intake and suspended rumination for the last three days. Rectal temperature, respiration rate and heart rates were 101.9, 24/min and 84 beats/min, respectively. Per rectal examination revealed absence of faeces. Tentatively, it was diagnosed as intestinal obstruction.

The right paralumbar fossa was aseptically prepared for right flank laparotomy and 2% lignocaine (Inj. Lox 2%, Neon Laboratories, Ltd., Mumbai) was infiltrated at the site of incision linearly. Laparotomy was performed by making a 15-20 cm skin incision vertically starting from 5cm below the lumbar transverse process. The external oblique muscle splitted caudo-ventrally, internal oblique and the transversus muscles were also separated cranio-dorsally and vertically, respectively representing a 'true grid' incision. The transversalis fascia and peritoneum were grasped and lifted with thumb forceps and incised with a scalpel. Peritoneal cavity was explored which disclosed a fibrous band forming a closed loop through which a part of the small bowel was entrapped (Fig. 1; A). The affected part was exteriorised through a laparotomy incision. The band was reconfigured to relieve intestinal obstruction and the entrapped intestinal loop was inspected for patency and viability (Fig. 1; B). The laparotomy wound was closed in a routine manner with polyglactin 910 no.1 suturing material.

Post-operatively, Enrofloxacin (Inj. Floxin, Samrudh Pharmaceuticals Tarapur, Thane) @ 5mg/kg body wt. and Meloxicam (Inj. Zobid M, Intas Pharmaceuticals Ltd, Ahmedabad) @ 0.2 mg/kg body wt. both were given intramuscularly for 5 days. Antiseptic dressing of the wound was done with povidone iodine daily for 10 days. Animal passed faeces after 5 hours and started taking feed from next day after surgery. Skin sutures were removed on the

*Corresponding author: nandanjhand7@gmail.com

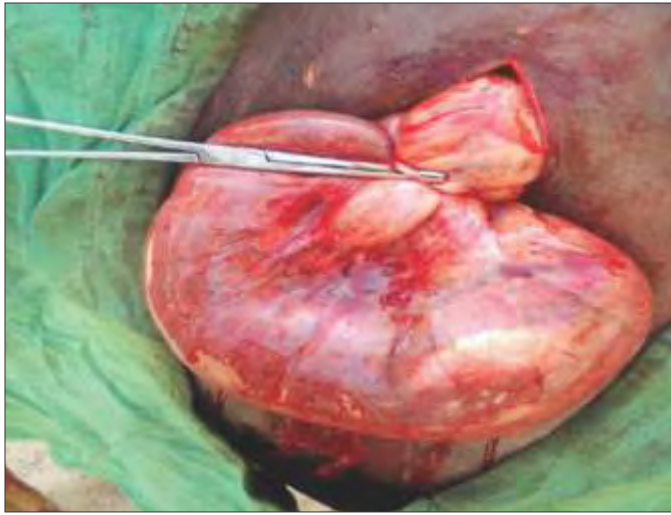


Fig. 1a. Intestinal obstruction due to fibrous band

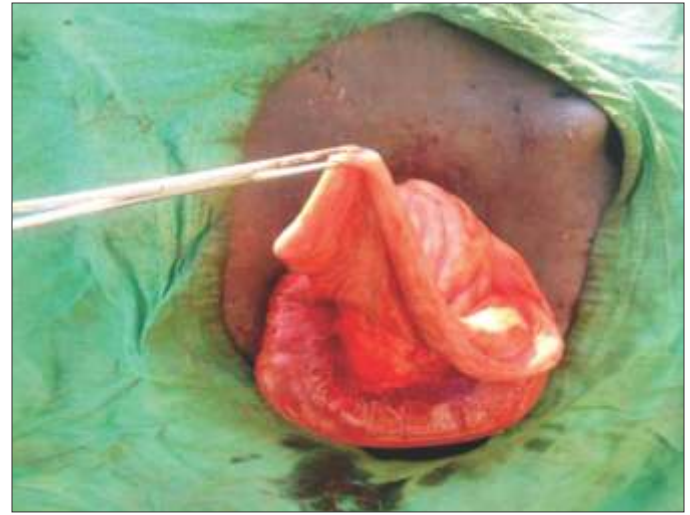

Fig. 1b. After resection of fibrous band to relieve intestinal obstruction

10th post-operative day. The animal recovered uneventfully without any post-operative complication and as per telephonic records is living a healthy life.

In the present case study, clinical signs of colic and cessation of faeces were suggestive intestinal obstruction which may be extraluminal or intraluminal (Radostits *et al.*, 2007; Dharmaceelan *et al.*, 2012; Hussain *et al.*, 2015). Intestinal obstruction due to fibrous band in cattle was reported by Sodhi *et al.* (2019). Similar reports of intestinal obstruction due to fibrous bands in human patients were also reported (Akgur *et al.*, 1992; Habib and Elhadad, 2003; El-Masry and Geevarghese, 2015). The origin of the fibrous band in our case was obscure, but it might be of congenital origin as reported by previous authors (Aphinives *et al.*, 2002; Habib and Elhadad, 2003; El-Masry and Geevarghese, 2015). In the present study standing right flank, exploratory laparotomy was opted as a diagnostic and therapeutic approach and similar findings were given by Sodhi *et al.* (2019).

CONCLUSION

It is concluded that exploratory laparotomy in cattle can be considered a diagnostic and therapeutic aid in intestinal obstruction. However, the possibility of a congenital fibrous band should be included in the differential diagnosis of patients with signs of intestinal obstruction, although this entity is very uncommon. This

clinical situation requires early surgical intervention.

REFERENCES

- Akgur, F.M., Tanyel, F.C., Buyukpamukcu, N. and Hicsonmez, A. (1992). Anomalous congenital bands causing intestinal obstruction in children. *J. Pediatr. Surg.* **27**: 471-473.
- Aphinives, P., Pukkem, A. and Bhudhisawasdi, V. (2002). Descending colon obstruction caused by a parietocolic band: a case report. *J. Med. Assoc. Thai.* **85**: 1042-1045.
- Dharmaceelan, S., Rajendran, N., Nanjappan, K., Subramanian, M. and Balasubramaniam, G.A. (2012). Incidence of bovine gastrointestinal obstruction in a teaching veterinary hospital of Tamilnadu, India. *Intern. J. Vet. Sci.* **1**(3): 112-114.
- El-Masry, N.S. and Geevarghese, R. (2015). Large bowel obstruction secondary to adhesive bands. *J. Surg. Case Rep.* **2**: 1-3
- Habib, E. and Elhadad, A. (2003). Small bowel obstruction by a congenital band in 16 adults. *Annales de chirurgie.* **128**: 94-97.
- Hussain, S.A., Uppal, S.K., Randhawa, C.S. and Sood, N.K. (2015). Bovine intestinal obstruction: blood gas analysis, serum C-reactive protein and clinical, haematological and biochemical alterations. *J. Appl. Anim. Res.* **43**(2): 224-230.
- Khalphallah, A., Aref, N.M., Elmeligy, E. and EL-Hawari, S.F. (2016). Clinical and ultrasonographic observations of functional and mechanical intestinal obstruction in buffaloes (*Bubalus bubalis*). *Vet. World.* **9**(5): 475-480.
- Radostits, O.M., Gay, C.C., Hinchcliff, K.W. and Constable, P.D. (2007). Diseases of the alimentary tract. In: *Veterinary Medicine: A textbook of the diseases of cattle, horses, sheep, pigs and goats*. (10th Edn.), Saunders, Elsevier, Philadelphia, PA. pp. 189-382.
- Sodhi, H.S., Sidhu, B.S and Kumar, A. (2019). Surgical management of Gut-Tie in a cow. *Int. J. Curr. Microbiol. App. Sci.* **8**(8): 542-547.