

## FREEMARTINISM IN CROSSBRED HOLSTEIN FRIESIAN HEIFER

ASLOOB AHMAD MALIK\*, KHURSHEED AHMAD SOFI<sup>1</sup>, PAWAN PREET SINGH and FASAL AHMAD MALIK

Division of Animal Reproduction Gynaecology and Obstetrics,

<sup>1</sup>Division of Veterinary Clinical Complex, Faculty of Veterinary Science and Animal Husbandry,  
Shera-e-Kashmir University of Agricultural Sciences and Technology of Kashmir, Srinagar-190006, J & K, India

Received: 25.10.2023; Accepted: 21.12.2023

### SUMMARY

Freemartin refers to a sterile female commonly reported in cattle but also documented in sheep and goat that develops alongside a male twin in the uterus. The present case study reports the two cases of Freemartin Holstein heifers diagnosed on the basis of history, clinical signs, per-rectal and ultrasonography examination. This case study serves as a reminder of the importance of understanding and addressing such condition in cattle breeding programs.

**Keywords:** Cattle, Freemartin, Heifers, Holstein Friesian

**How to cite:** Malik, A.A., Sofi, K.A., Singh, P.P. and Malik, F.A. (2024). Freemartinism in crossbred Holstein Friesian heifer. *Haryana Vet.* 63(1): 147-149.

Freemartin refers to a sterile female most commonly reported in cattle but also documented in sheep and goat (Abecia *et al.*, 2020) that develops alongside a male twin in the uterus (Esteves *et al.*, 2012). The key to understanding freemartins lies in the intricate exchange of blood and hormones between these twin foetuses through the shared placental circulation. This exchange often leads to the masculinization of the female twin, affecting the development of its reproductive organs (Garcia *et al.*, 2022). As a consequence, freemartins are rendered incapable of reproduction. The term "freemartin" carries significant implications in livestock breeding, as it can impact the genetic diversity and profitability of cattle farms, making the study of this condition vital in animal husbandry practices (Padula, 2005).

The prevalence of twinning in the population has a direct correlation with the prevalence of the Freemartin syndrome in cattle. Freemartinism although is not a heritable condition but rather congenital (Albarella *et al.*, 2019). Twinning has been observed to vary in prevalence across breeds and appears to have a hereditary basis. Twinning incidence may also change as a result of artificial selection enforced by men, such as culling or purposeful usage of cows with greater twinning rates (Esteves *et al.*, 2012), as well as due to repeated non-sexed embryo transfers, when two or more embryos are already deposited. Age and parity also have major effects in multiple pregnancies, whereas season has a minor impact. Freemartinism must coexist in the following three major events: pregnancy with dizygotic twins, fetuses of different sexes and placental anastomosis (Esteves *et al.*, 2012).

In livestock farming, freemartins can be identified through genetic testing and physical examinations early in

life. Understanding the freemartin condition is not only essential for managing livestock populations effectively but also throws light on the intricate interplay of genetics and hormonal influences during fetal development. The present report puts on record the two cases of Freemartin in Holstein Friesian heifers.

### CASE HISTORY AND DIAGNOSIS

Two Holstein Friesian heifers (Case No. 0658/1796 and 1723/1890) aged 3 and 2 years respectively, were presented in outpatient department (OPD) of Veterinary Clinical Complex with a history of normal twin birth along with male fetus. Both heifers were not displaying any signs of estrus even after attaining puberty although they appeared to be having high BCS (3.5).

On per rectal examination in case 1, it was observed that reproductive tract was absent but ovaries being present. On ultrasonography (using rectal probe with Frequency 5 MHz) findings left ovary was larger (1.91×1.78 cm) in size while right ovary (1.35×0.85 cm) was small in size without presence of any structures. Finchers test (Fig. 1) was performed with the freemartin probe and the length of vagina was measured to be 13 cm.

In case 2, on perrectal examination, horns and utrine body were present but cervix was rudimentary. USG examination revealed that uterus wall was thin and no structures were present on both the ovaries. Left and right ovary measured as 1.85×1.08 cm and 2.25×1.59 cm respectively. A lobe like structure was found within the ovarian cortex giving the appearance of rete testis (Fig. A) but without any follicular/luteal structures. Also, uterus was thin walled (Fig. B). Length of vagina was observed to be 13 cm after performing the Finchers test (Fig. 2).

Based on history, clinical signs and USG examination

\*Corresponding author: malikasloob@gmail.com

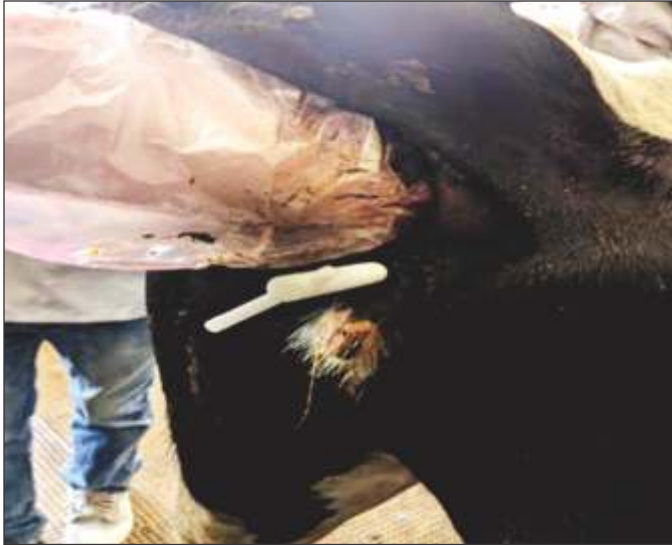

Fig. 1. Fincher's Test (HF Heifer 1, Vaginal length 13 cm)



Fig. 2. Fincher's Test (HF Heifer 2, Vaginal length 13 cm)

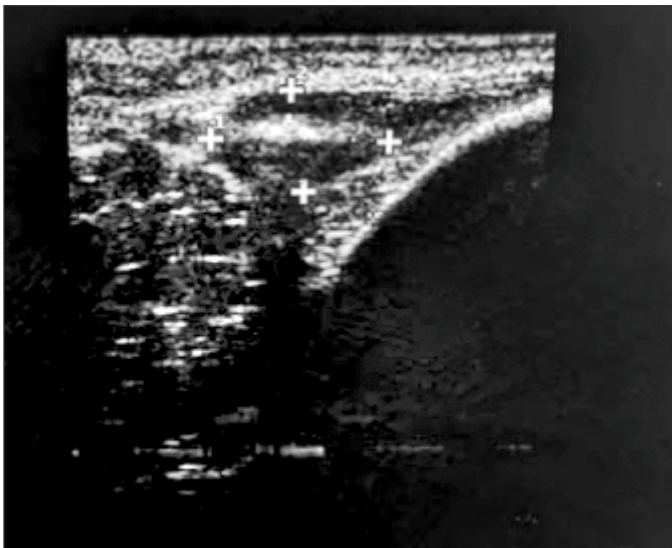


Fig A: Lobe like structure giving appearance of rete testis

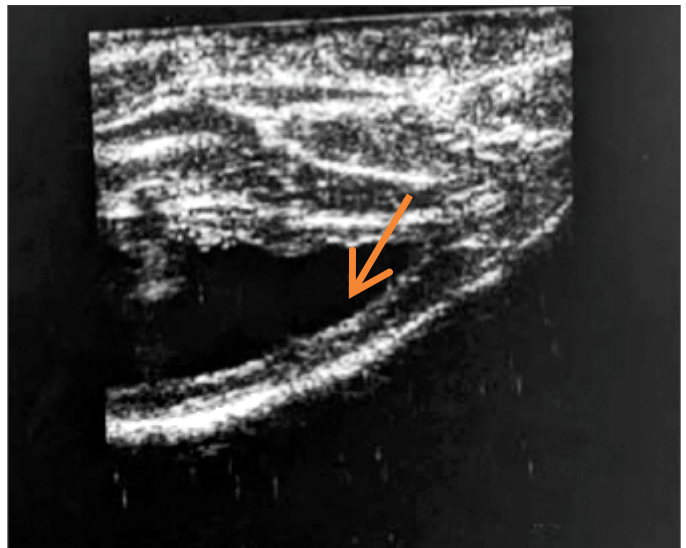


Fig B: Thin walled uterus

both the animals were diagnosed with freemartin condition.

### TREATMENT AND DISCUSSION

The present cases were diagnosed on the basis of history, clinical signs, per-rectal and USG examination. Since, Freemartinism in cattle is an unmanageable congenital condition with no available treatment. So the owners were advised to cull the animal. Although use of cytogenetic and molecular methods (PCR, short tandem repeats (STRs), real-time PCR) allowed us to conclude that molecular methods are more effective and guarantee fast and precise diagnosis (Kozubska *et al.*, 2016). Congenital defects present at birth occur frequently in cattle and these defects may enhance perinatal mortality, decrease maternal productivity and reduce the value of defective neonates (Tiwary *et al.*, 2016).

In females born from twin pregnancies or multiple

pregnancies bearing fetuses of opposite genders, the phenomenon of Freemartinism results in a disordered development of the reproductive system, including infertility (Szczerbal *et al.*, 2014). The condition occurs due to the exchange of blood between the circulatory systems of the male and female fetuses during early embryonic development. This exchange leads to the transfer of male hormones (androgens) from the male to the female fetus, resulting in masculinization of the female. One of the significant implications of Freemartinism is sterility in the affected female calf.

Esteves *et al.* (2012) discussed about the length of vagina in freemartin Holstein calves using Fincher's test. Freemartin upto one month old have vagina 5-8 cm long, whereas typical female vaginas are 13-15 cm long. In mature freemartins, the vagina is only 8-10 cm long, whereas the length of vagina in adult cow is 30cm. Singh et

al. (2019) reported a rare case of free martin co-twin with male fetus delivered by caesarean section while the other twin was found dead.

The internal reproductive organs of the freemartin are typically underdeveloped and non-functional. Males start their gonadal differentiation several days earlier than females do, which makes it possible for sex-determining substances to be transferred from the developing male gonad to the developing female embryo, leading to the malformation of female reproductive organs (Kozubska *et al.*, 2019). The abnormalities of the female twin are caused by the anti-Mullerian hormone, which is responsible for the regression of the Mullerian structures in males during their normal sexual development and is involved in the morphological differentiation of the testes (She and Yang, 2014). This condition has economic consequences for dairy and beef cattle operations, as freemartin females cannot be used for breeding. The exchange of hormones in utero can affect not only the external genitalia but also secondary sexual characteristics and behaviour. Freemartin heifers may display masculine morphology and do not exhibit estrus, further reducing their value in breeding programs (Esteves *et al.*, 2012). Early identification of freemartins can prevent economic losses associated with unproductive female cattle (Kozubska *et al.*, 2019). This condition is more common in cattle but has also been reported in other species with similar twinning patterns.

### CONCLUSION

The present report puts on record of two freemartin Holstein Friesian in Union Territory of Jammu and Kashmir, India. Timely identification and appropriate management of freemartins are crucial for maintaining the reproductive efficiency of cattle herds and minimizing economic losses associated with unproductive females. This study report reminds the importance of understanding

and addressing such conditions in cattle breeding programs.

### REFERENCES

- Abecia, J. A., Sánchez, M. and Arrebola, F. (2020). The effect of male co-twins on milk and kid production, and productive lifespan of goats during their adult life. *Livest. Sci.* **242**: 104279.
- Albarella, S., D'Anza, E., Galdiero, G., Esposito, L., De Biase, D., Paciello, O. and Peretti, V. (2019). Cytogenetic Analyses in Ewes with Congenital Abnormalities of the Genital Apparatus. *Anim.* **9(10)**: 776.
- Esteves, A., Bage, R. and Payan-Carreira, R. (2012). Freemartinism in cattle. *Rumin. Anat. Behav. and Disease*. New York: Nova Science Publishers. pp. 99-120.
- Garcia Ispuerto, I., Palacín Chauri, R.J. and López Gatius, F. (2022). Twin reduction in the late embryonic period prevents the condition of freemartin in dairy cattle. *Reprod. Domest. Anim.* **57(12)**: 1649-1651.
- Kozubska-Sobocińska, A., Danielak-Czech, B. and Rejduch, B. (2016). Cytogenetic and molecular diagnostics of XX/XY chimerism in cattle, sheep, and goats—a review. *Ann. Anim. Sci.* **16(4)**: 989-1005.
- Kozubska-Sobocińska, A., Smołucha, G. and Danielak-Czech, B. (2019). Early diagnostics of freemartinism in Polish Holstein-Friesian female calves. *Anim.* **9(11)**: 971.
- Padula, A.M. (2005). The freemartinism syndrome: an update. *Anim. Reprod. Sci.* **87**: 93-109.
- She, Z.Y. and Yang, W.X. (2014). Molecular Mechanisms Involved in Mammalian Primary Sex Determination. *J. Mol. Endocrinol.* **53**: R21-R37.
- Singh, G. (2019). Delivery of Free Martin (Co-Twin with Male) Fetus by Caesarean Section in a Non-Descript Cow. *Int. J. Agric. Sci. ISSN*, pp. 0975-3710.
- Szczerbal, I., Kociucka, B., Nowacka-Wozzuk, J., Lach, Z., Jaskowski, J.M. and Switonski, M.A. (2014). High Incidence of Leukocyte Chimerism (60, XX/60, XY) in Single Born Heifers Culled Due to Underdevelopment of Internal Reproductive Tracts. *Czech J. Anim. Sci.* **59**: 445-449.
- Tiwary, R., Gattani, A.N.I.L., Kumar, A., Kumar, A. and Singh, G.D. (2016). Surgical correction of congenitally fused vulva labia in a Holstein Friesian cross bred heifer. *Haryana Vet.* **55(1)**: 108-109.