

## MANAGEMENT OF UNILATERAL BARTHOLIN'S GLAND ABSCESS IN A CROSSBRED HOLSTEIN-FRIESIAN COW: A CASE REPORT

S. ALAGAR, M. KALAIVANAN, S. RANGASAMY\*, R. ARUN, A. METHAI, RANJANI RAJASEKARAN and P.N. RICHARD JAGATHEESAN

Department of Veterinary Gynaecology and Obstetrics, Veterinary College and Research Institute, Theni-625 534, Tamil Nadu Veterinary and Animal Sciences University

Received: 20.10.2023; Accepted: 12.12.2024

### SUMMARY

A 6-year-old crossbred Holstein Friesian cow, which has calved three times, was presented with a history of mild vaginal prolapse that had been occurring since a week. The cow had calved two months prior to presentation and had been recently acquired. Upon clinical examination- it was observed that a cyst was protruding between the vaginal lips. The cyst's wall appeared thin and well-supplied with blood vessels. Additionally, the surface epithelium displayed a yellowish colour. Ultrasonography examination further confirmed the presence of pus within the cyst. The cyst had a diameter of 7×10 cm, and the cow exhibited no pain upon palpation of the cyst. Under caudal epidural anaesthesia, the cyst was punctured and the pus was successfully evacuated. Following the drainage, a 10 ml solution of povidone iodine was infused into the cyst's cavity. The cow received antibiotics, anti-inflammatory medication, and antihistamines continuously for five days. Fortunately, the cow recovered without any complications and there has been no recurrence of the issue.

**Keyword:** Cross bred cow, Bartholin's gland, abscess and Exploratory puncture

**How to cite:** Alagar, S., Kalaivanan, M., Rangasamy, S., Arun, R., Methai, A., Rajasekaran, R. and Richard Jagatheesan, P.N. (2024). Management of unilateral bartholin's gland abscess in a crossbred Holstein-Friesian cow: A case report. *The Haryana Veterinarian* 63(1): 150-152.

The Bartholin or vestibular glands are normally paired and not palpable. These glands are situated in the vaginal labia minora and their duct opens on the lateral wall of the vestibule, approximately 2.5 cm caudal to the vagina, as a single duct (Roberts, 1971). These glands secrete mucus during the estrous cycle under the influence of the hormone estrogen (F.U. Sag. Bil, 2009). This secretion serves to lubricate the vagina during copulation (Marzano and Haefner, 2004).

When, the opening of these glands can become obstructed, resulting in the accumulation of secretions within the gland. This leads to the painless swelling referred to as Bartholin's or Vestibular cyst (Sharma and Thakur, 2023), which can grow to a size ranging from 2 to 10 cm. The obstructed state of the gland can also give rise to retention cysts, which have been mistakenly identified as vaginal prolapse. In cases where the fluid within the cyst becomes infected, it can lead to the accumulation of pus surrounded by inflamed tissue, forming an abscess (Bademkiran *et al.*, 2009).

A 6-year-old crossbred Holstein Friesian cow was brought to the Veterinary Clinical Complex at VCRI, Theni, with a history of mild vaginal prolapse persisting for a week. The cow was in a normal posture and all other parameters like temperature, haematology and biochemistry values were within normal ranges.

Upon clinical examination, a soft-walled cyst measuring 7 × 10 cm was observed on the left lateral caudal vaginal wall (Fig. 1). The cow displayed no pain upon

palpation and the yellowish appearance of the cyst's surface epithelium raised suspicion of pus material (Fig. 2). An ultrasound examination confirmed the presence of pus within the cyst cavity (Fig. 3).

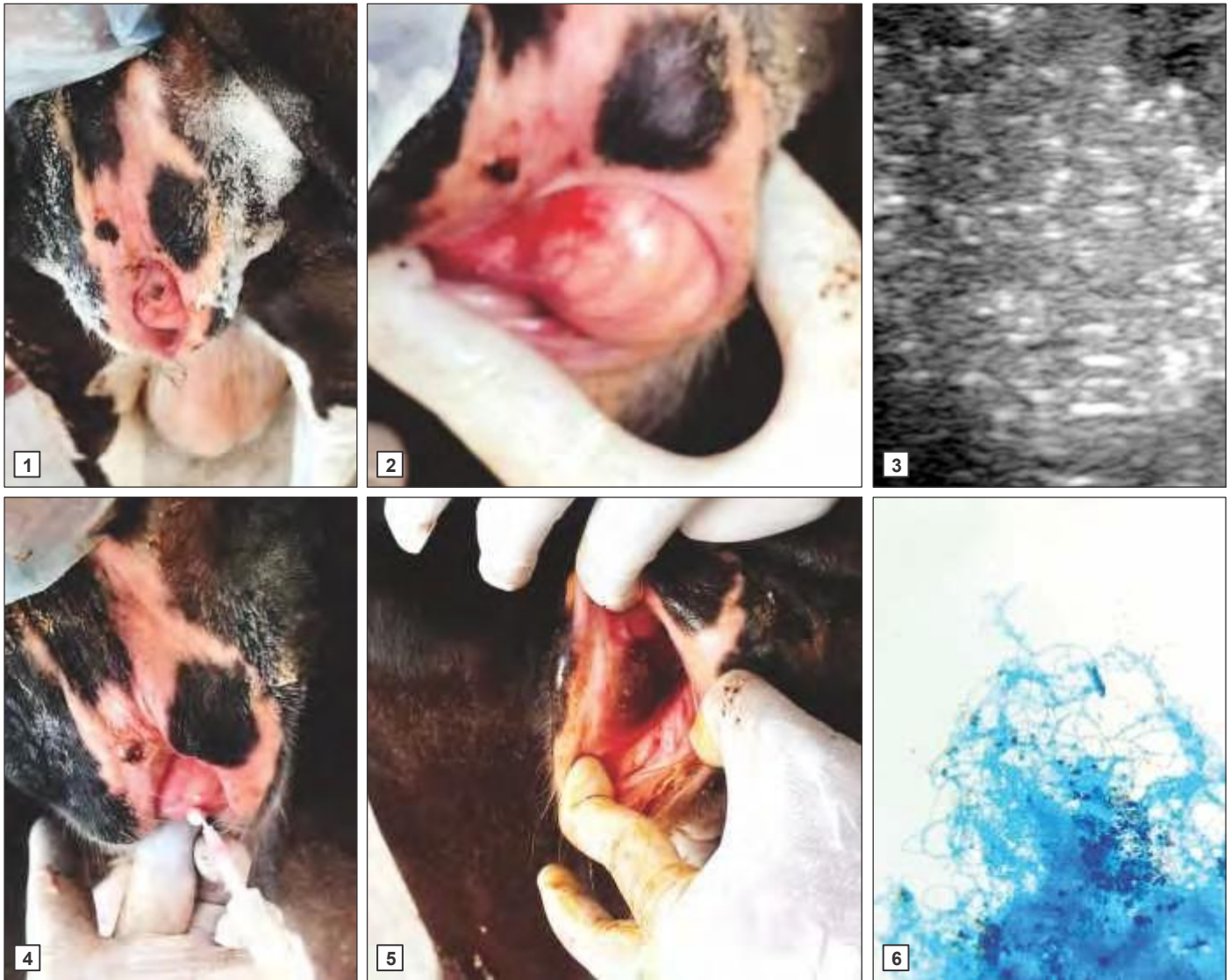
Under caudal epidural anaesthesia using, inj. Lignocaine hydrochloride -2.5 ml, the cyst wall was thoroughly cleaned with povidone iodine prior to puncturing the cyst. An exploratory puncture was performed using an 18G needle attached to a 10 ml syringe, resulting in the evacuation of approximately 20 ml of pus (Fig. 4). Subsequently, 10 ml of povidone iodine solution was infused into the cyst following pus removal.

The cow was also administered inj. Enrofloxacin @ 5 mg per kg/B.Wt, I/M, inj. Meloxicam @ 0.2 mg per kg/B.Wt, I/M and inj. Chlorpheniramine maleate @ 1 mg per kg B.Wt, I/M, for a period of 5 days. After 5 days, the cow was examined for the presence of any fluid accumulation at the cyst site (Fig. 5) and no abnormalities were observed. The cow made a full and uneventful recovery.

In the current case, the unilateral (left-sided) Bartholin's gland abscess observed in a crossbred cow may have been the result of difficulties during calving in field conditions. Previous studies by Selvaraju *et al.* (2010), Manokaran *et al.* (2014), and Kumar (2018) in buffalo, as well as Soundararajan *et al.* (2015) in aged Jersey, Holstein Friesian (HF) and Jersey crossbred cows, have also reported instances of unilateral Bartholin gland cysts.

The Bartholin's glands are positioned on either side

\*Corresponding author: drrangs1976@gmail.com



Figs.1-6. (1) Bartholin's cyst abscess; (2) Yellow colour surface epithelium; (3) Ultrasound image of cyst abscess; (4) Pus aspiration from the cyst; (5) Cyst after the treatment; (6) Methylene blue stain/ G- ve / Rod

of the vaginal opening. Their function is to secrete fluid that aids in the lubrication of the vagina (Marzano and Haefner, 2004). In cases of both normal and challenging calving experiences, trauma can occur and, in some instances, extensive lacerations may develop. This trauma can lead to the onset of local necrotic vulvovaginitis, which, in turn, can result in the obstruction of the duct opening (Fathella *et al.*, 2000).

Uterine, cervical and vaginal abscesses can be brought about by challenging parturition, rough handling during parturition or trauma incurred during Artificial Insemination (Hopper, 2015). It's worth noting that the cyst typically does not pose any issues during parturition and does not interfere with conception, as explained by Roberts (1971). However, there are instances when it can cause interference during the process of Artificial Insemination (AI), particularly when inserting the AI gun

through the vagina.

The external genitalia exhibited a distorted shape and a degree of vaginitis was observed in connection with this defect, especially when not treated promptly (Kumar, 2018). Bartholin glands can serve as reservoirs for pathogenic organisms (McEntee, 1970). In the current case, a culture test was conducted and found to be positive for gram-negative bacteria (*Fusobacterium necrophorum*), as confirmed by methylene blue staining (Fig. 4).

The formation of retention cysts can occur due to occlusive lesions of the duct, such as in cases involving metaplasia of the lining epithelium, which is associated with chronic hyperestrogenism in cows with ovarian-follicular cysts (Kumar, 2018). However, it's worth noting that in the present case, no recurrence of the condition was observed.

## CONCLUSION

The current case of a unilateral left-sided Bartholin's gland abscess may have arisen due to improper handling during the parturition process in field conditions. Following a correct diagnosis, the evacuation of pus from the cyst and the infusion of povidone iodine, along with five days of parenteral antibiotics, anti-inflammatory drugs and antihistamines, the patient made a successful recovery without any recurrence of the condition without any reoccurrence.

## REFERENCES

- Badmekiran, S., Yesilmen, S. and Yokus, B. (2009). Unilateral bartholin gland cyst in a pregnant heifer. *Firat Universitesi Saglık Bilimleri Veteriner Dergisi*. **23**: 6-63.
- Fathalla, M., Hailat, N., Lafi, S.Q., Abu Basha, E. and Al-Sahli, A. (2000). An abattoir survey of gross reproductive abnormalities in the bovine genital tract in Northern Jordan. *Israel. J. Vet. Med.* **55**: 56-61.
- F.U. Sag. Bil. (2009). Unilateral Bartholin Gland Cyst in A Pregnant Heifer. *Vet. Derg.* **23**(1): 61-63.
- Kumar, S. (2018). A rare case of unilateral bartholin's gland cyst in a Murrah crossbred buffalo. *Int. J. Curr. Microbiol. App. Sci.* **7**(12): 2851-2853.
- Manokaran, S., Sivasankar, K., Palanisamy, M., Selvaraju, M. and Ezakial Napoleon, R. (2014). Unilateral Bartholin's gland cyst in a Holstein Friesian crossbred cow. *Int. J. Livest. Res.* **4**(9): 48-50.
- Marzano, D.A. and Haefner, H.K. (2004). The bartholin gland cyst: past, present, and future. *J. Low. Genit. Tract. Dis.* **8**(3): 195-204.
- McEntee, K. (1970). The female genital system - In *Pathology of Domestic Animals*. Jubb and Kennedy, New York and London: Academic Press. **1**: 487-585.
- Hopper, R.M. (2015). *Bovine reproduction*. (1<sup>st</sup> Edn.), Wiley Blackwell publishing, Oxford, UK. p. 338.
- Roberts, J.S. (1971). *Veterinary Obstetrics and Genital Diseases*. (2<sup>nd</sup> Edn.), CBS Publishers and Distributors, New Delhi, India.
- Selvaraju, M., Palanisamy, M., Prabakaran, V., Ravikumar, K., Ravi, R. and Chandrasaran, C. (2010). Cystic Bartholin's gland in a Jersey crossbred cow: A case report. *Indian J. Field. Vet.* **5**(4): 74.
- Sharma, A.K. and Thakur, R. (2023). Unilateral Bartholin gland cyst in a cow and its surgical management - A case report. *Indian Vet. J.* **100**(8): 33-35.
- Soundararajan, C., Arul Parkesh, M. and Senthil Kumar, K. (2015). Unilateral Bartholin gland cyst in a Jersey crossbred cow. *Indian J. Ani. Reprod.* **36**(2): 75-76.

# THE HARYANA VETERINARIAN

Editors/Editorial Board Members are highly thankful to all the distinguished referees who helped us in the evaluation of articles. We request them to continue to extend their co-operation and be prompt in future to give their valuable comments on the articles for timely publication of the journal.