

## SURGICAL MANAGEMENT OF PERINEAL HERNIA IN MALE DOGS

SULEKHA\*, ANJU POONIA, DEEPAK KUMAR TIWARI, NEERAJ ARORA,  
SANDEEP SAHARAN, SANDEEP KUMAR, ALPA

Department of Veterinary Surgery and Radiology, College of Veterinary Sciences,  
Lala Lajpat Rai University of Veterinary and Animal Sciences, Hisar-125004 (Haryana)

Received: 14.10.2023; Accepted: 22.12.2023

### SUMMARY

Four male dogs with the history of swelling in the perineal region were brought to the Teaching Veterinary Clinical Complex (TVCC), LUVAS, Hisar. All the four animals were intact. Examination of the swelling revealed presence of content and the case was diagnosed as perineal hernia. Radiography and ultrasonography was performed in all the cases to rule out the contents of the hernial sac. Diagnostics revealed presence of different contents in the hernial sac including omentum, intestinal loops, urinary bladder. Upon surgical intervention, hernial contents in two cases were intestinal loops along with omentum and in remaining two cases urinary bladder was present. In one of the two cases, along with urinary bladder enlarged prostate was found. Anatomical herniorrhaphy was performed in all the cases and polypropylene mesh was used in one case. All the animals recovered uneventfully and no post operative complications were reported in any of the case.

**Keywords:** Perineal hernia, Male dog, Intestinal loops, Urinary bladder

**How to cite:** Sulekha, Poonia, A., Tiwari, D.K., Arora, N., Saharan, S., Kumar, S., Alpa (2024). Surgical management of perineal hernia in male dogs. *The Haryana Veterinarian* 63(1): 144-146.

Perineal hernia occurs due to the weakness, separation, and eventual failure of muscles in the pelvic diaphragm. This causes the pelvic and abdominal contents to displace into the perineal area (Burrows and Harvey, 1973). Perineal hernia occurs most often in middle to elderly aged intact male dogs (Radlinsky and Fossum, 2019). Additionally, castration may prevent occurrence of perineal hernia as muscle fibrosis due to hormones which are produced by testis is removed (Hayes *et al.*, 1978; Mann *et al.*, 1995; Niebauer *et al.*, 2005). Perineal hernia leads to tenesmus, dyschezia and in few cases obstruction secondary to urinary bladder retroflexion (Hosgood *et al.*, 1995; Baines *et al.*, 2018).

In short, to close the hernial ring anatomical herniorrhaphy is carried out with external anal sphincter muscle, levator ani muscle, coccygeus muscle, internal obturator muscle and sacro-tuberous ligament (Radlinsky and Fossum, 2019). Surgical correction is usually recommended for the alleviation of clinical signs (Baines *et al.*, 2018). The standard surgical treatment for perineal hernia involves the re-apposition of the muscles of the pelvic diaphragm using absorbable suture materials. (Bellenger and Canfield, 2003).

### HISTORY AND OBSERVATION

Four intact male dogs were brought to the Veterinary Clinical Complex in LUVAS, Hisar with a history of swelling around the right side of their perianal region (Fig. 1). The owner reported that the dogs' bowel movements were normal, and three of the dogs had no issues with urination. However, one dog had been experiencing

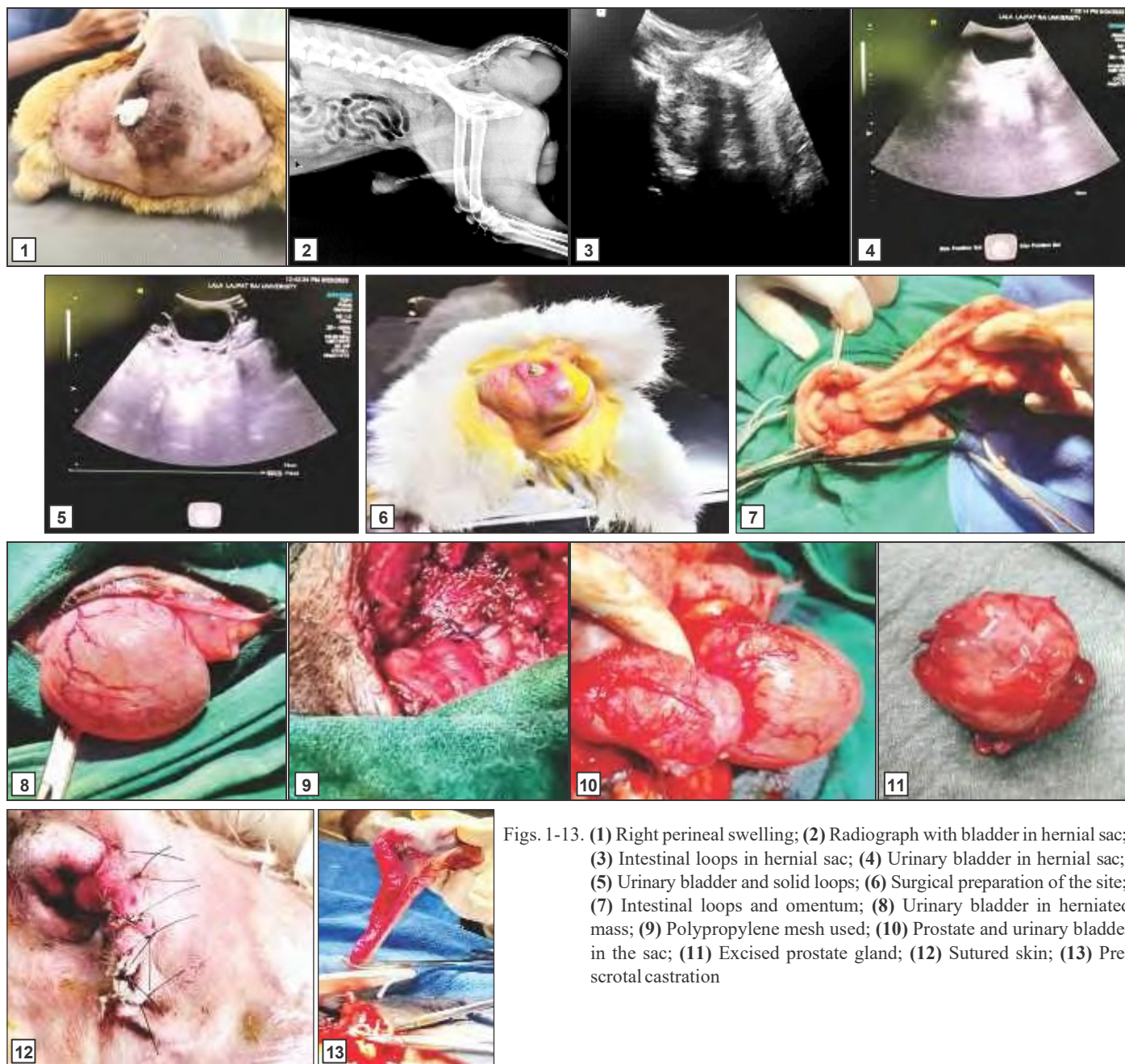
S.No	Age	Breed	Neutering status	History	Hernial content	Surgical intervention
1.	7 years	Non-descript	Intact	Right sided swelling since 20 days	Intestinal loops, omentum	Castration and Herniorrhaphy
2.	11 years	Labrador-cross	Intact	Right sided swelling since 1 week	Intestinal loops, omentum	Castration and Herniorrhaphy
3.	6 years	Spitz	Intact	Right sided swelling since 1 month	Urinary bladder, enlarged prostate	Castration and Herniorrhaphy
4.	6.5 years	Non-descript	Intact	Right sided swelling since 7 months	Urinary bladder	Castration and Herniorrhaphy

urinary retention for the past day. During the physical examination, it was discovered that there were contents within the swelling. The diagnosis was perineal hernia. Radiographic examination revealed that two of the cases had hernial content in the form of intestinal loops, while in the other two cases, the content was not clear on the radiograph (Fig 2). Ultrasonographic examination showed presence of intestinal loops (shown in Fig. 3) in two cases and in other two anechoic structure i.e., urinary bladder was visible (Fig. 4 and 5). Blood was collected for Complete Blood Count (CBC) examination and all the parameters were within the normal physiologic range.

### TREATMENT AND DISCUSSION

All the animals were pre-medicated with atropine sulphate at 0.04 mg/kg BW subcutaneously and after 10 minutes xylazine hydrochloride was administered at 1 mg/kg BW intramuscularly. Perianal region was shaved

\*Corresponding author: sulkhs.vet@gmail.com



Figs. 1-13. (1) Right perineal swelling; (2) Radiograph with bladder in hernial sac; (3) Intestinal loops in hernial sac; (4) Urinary bladder in hernial sac; (5) Urinary bladder and solid loops; (6) Surgical preparation of the site; (7) Intestinal loops and omentum; (8) Urinary bladder in herniated mass; (9) Polypropylene mesh used; (10) Prostate and urinary bladder in the sac; (11) Excised prostate gland; (12) Sutured skin; (13) Pre-scrotal castration

and prepared aseptically for the surgery. All the animals were placed in ventral recumbency with their hindquarter raised, hindlimbs tucked in as shown in Fig. 6 and tail tied to one side after bandaging. Induction of anaesthesia was done using 1:1 ratio of ketamine-xylazine till effect. Xylazine and ketamine were present at 1 and 5 mg/kg BW, respectively in the mixture. Thereafter, endotracheal tube was intubated and anaesthesia was maintained using 1.5-2% isoflurane. A curvilinear incision was made along the perineal region just above the swelling by taking care of the underlying structures. Subcutaneous layer was isolated and hernial sac was incised. Careful supervision of the hernial contents was done. In two cases, hernial contents included omentum and intestinal loops (Fig. 7), in one case

urinary bladder was present (Fig. 8) and in remaining one case urinary bladder along with highly enlarged prostate was there (Fig. 10). Enlarged prostate gland was excised as seen in Fig. 11. Thereafter, hernial contents were reduced and positioned back. In all the cases muscles were a bit atrophied. Anatomical herniorrhaphy was performed. External anal sphincter was apposed with coccygeus as well as internal obturator muscle with vicryl no. 1 suture material in lock stitch pattern. In one of the case, polypropylene mesh of 6 cm × 3 cm was used after cutting it into the size to fit the hernial ring and its edges were sutured in simple interrupted pattern to the underlying muscles and sacro-ischiatic ligament (Fig. 9). Subcutaneous tissue was sutured and skin sutures were placed in simple

interrupted pattern with Nylon no. 2 (Fig. 12). Castration was performed in all the animals with pre-scrotal method as shown in Fig. 13.

After the surgery, cefotaxime was given intravenously at a rate of 50 mg/kg BW for five days, along with ringers lactate and 5% dextrose solution for intravenous fluid therapy. Meloxicam was also given subcutaneously twice a day for five days at a dose of 0.2 mg/kg BW. The owner was advised to give an oral laxative twice a day for the next month, along with a liquid diet. No surgical complications were reported in any of the cases for three months after the surgery.

All the animals had an uneventful recovery without any observable post-operative complications. Normal passage of urine and motion was reported in all the cases post-surgery. No wound dehiscence was reported and it could be attributed to the maintenance of patients on liquid diet and laxatives. Castration helped in reducing the perineal muscle relaxation effect of androgen and decreases the size of prostate. Successful surgical management of perineal hernia was done by Martin *et al.* (2012) in a single dog using polypropylene mesh and by Heishima *et al.* (2022) in eight intact male dogs using pedunculated tunica vaginalis communis. In the present study, polypropylene mesh was used to close the hernial ring in one case and similar to Martin *et al.* (2012) perineal hernia was successfully managed.

Hence, it is concluded that all the four cases of perineal hernia was successfully managed by surgical intervention using anatomic herniorrhaphy in three cases and by use of polypropylene mesh in one case.

## REFERENCES

- Baines, S.J. and Aronson, L.R. (2018). Rectum, anus, and perineum. In: Johnston S.J., Tobias K.M. (eds.), *Veterinary Surgery: Small Animal*. (2<sup>nd</sup> Edn.), St. Louis, Missouri: Elsevier. 1783-1827.
- Bellenger, C.R. and Canfield, R.B. (2003). *Text Book of Small Animal Surgery*. (3<sup>rd</sup> Edn.), W.B. Saunders, Philadelphia. pp. 487-498.
- Burrows, C.F. and Harvey, C.E. (1973). Perineal hernia in the dog. *J. Small Anim. Pract.* **14**: 315-332.
- Hayes, H.M. Jr, Wilson, G.P. and Tarone, R.E. (1978). The epidemiologic features of perineal hernia in 771 dogs. *J. Am. Anim. Hosp. Assoc.* **14**: 703-7.
- Heishima, T., Asano, K., Ishigaki, K., Yoshida, O., Sakurai, N., Terai, K., Seki, M., Teshima, K. and Tanaka, S. (2022). Perineal herniorrhaphy with pedunculated tunica vaginalis communis in dogs: Description of the technique and clinical case series. *Front. Vet. Sci.* **9**: 931088. doi: 10.3389/fvets.2022.931088.
- Hosgood, G., Hedlund, C.S., Pechman, R.D. and Dean, P.W. (1995). Perineal herniorrhaphy: Perioperative data from 100 dogs. *J. Am. Anim. Hosp. Assoc.* **31**: 331-342.
- Mann, F.A., Nonneman, D.J., Pope, E.R., Boothe, H.W., Welshons, W.V. and Ganjam, V.K. (1995). Androgen receptors in the pelvic diaphragm muscles of dogs with and without perineal hernia. *Am. J. Vet. Res.* **56**: 134-9.
- Martin, K.D.J., Sarangom, S.B., Philip, S.B. and Kankonkar, A.P. (2012). Repair of recurrent perineal hernia using polypropylene mesh in a dog. *J. Vet. Anim. Sci.* **43**: 59-6.
- Niebauer, G.W., Shibly, S., Seltenhammer, M., Pirker, A. and Brandt, S. (2005). Relaxin of prostatic origin might be linked to perineal hernia formation in dogs. *Ann. N.Y. Acad. Sci.* **1041**: 415-22. doi: 10.1196/annals.1282.062.
- Radlinsky, M.G. and Fossum, T.W. (2019). *Small Animal Surgery*, (5<sup>th</sup> Edn.), *Surgery of the Digestive System*. Philadelphia, PA: Elsevier. pp. 496-501.