

## CAPILLARY-CAVERNOUS HEMANGIOMA IN A DOG: A MIXED PRESENTATION

AVANTIKA SRIVASTAV, SHYAMA N. PRABHU\*, NEERAJ K GANGWAR, RENU SINGH, AJAY PRATAP SINGH, KAVISHA GANGWAR, YASH BHATE, KAUSHAL and SANJAY PUROHIT

College of Veterinary Science and Animal Husbandry

Uttar Pradesh Pandit Deen Dayal Upadhyaya Pashu Chikitsa Vigyan Vishwavidyalaya Evam Go-Anusandhan Sansthan, Mathura-281001, Uttar Pradesh

Received: 25.09.2023; Accepted: 22.11.2023

### SUMMARY

A German shepherd dog was presented to the Veterinary Clinical Complex (VCC), College of Veterinary Science and Animal Husbandry, DUVASU, Mathura with the history of diuresis and a growth in the perineal region. The mass was surgically excised and the sample sent to the Department of Pathology for histopathology. The histopathological findings showed numerous capillaries as well as large vascular spaces lined by a single layer of plump endothelial cells. Based on the histopathological findings the given mass was diagnosed as subcutaneous mixed capillary cavernous hemangioma.

**Keywords:** Capillary, Cavernous, Hemangioma, Mixed, Subcutaneous

**How to cite:** Srivastav, A., Prabhu, S.N., Gangwar, N.K., Singh, R., Singh, A.P., Gangwar, K., Bhate, Y., Kaushal and Purohit, S. (2024). Capillary-cavernous hemangioma in a dog: A mixed presentation. *The Haryana Veterinarian* 63(1): 133-134.

Hemangiomas are benign tumors that spontaneously originate from vascular endothelial cells generally seen in dogs and rarely in other species (Goldschmidt *et al.*, 2002). In dogs, cutaneous hemangiomas are more common than hemangiosarcomas (Schultheiss, 2004). One of the most commonly associated risk factors involved in the development of cutaneous hemangiomas and hemangiosarcomas in dog is solar radiation (Pirie *et al.*, 2006). The incidence of hemangiomas in dogs comprise 4.5% of skin and subcutaneous tumors (Gross *et al.*, 2008).

A 11-year-old male German shepherd dog was presented at the VCC Mathura with a subcutaneous mass in the perineal region about 5 cm below the anal opening for the past 5-6 months and with a history of fever and diuresis (Fig. A). The mass was surgically excised under general anesthesia. Post-operative treatment was done with tab cefuroxime @ 15 mg/kg, tab Meloxicam @ 0.1 mg/kg, tab pantoprazole @ 2 mg/kg and vit. C tab @ 500 mg and the area well dressed. The surgically excised mass was submitted to the Department of Pathology for histopathological evaluation. Grossly the mass was hard, tuberculated and bright red in colour with cut surface showing honey comb-like/spongy pattern (Fig. B). The growth measured about 4.5 cm × 4.0 cm × 3.5 cm in dimensions (Fig. C). The excised mass was fixed in 10% formalin and processed for histopathology. Microscopically the tissue section showed multiple dilated capillaries (arrows) as well as large blood-filled vascular spaces (arrow heads) separated by honey comb-like pattern of connective tissue septae (Fig. D). The dilated vascular channels were lined by a single layer of endothelial cells

enclosing erythrocytes in their lumen (Fig. E).

Cutaneous hemangiomas are solitary, deep dermal tumors, whereas haemangiosarcomas are malignant tumors involving the different organs. In a retrospective clinicopathological study of cutaneous hemangiomas and hemangiosarcomas, the average age of the dogs affected was greater than 10 years with no sex predilection (Hargis *et al.*, 1992). Hemangiomas are benign tumours commonly seen in adult dogs. Grossly, hemangiomas are reddish-black in colour, varying in shape from ovoid to discoid with moderately firm consistency and with oozing of blood from the surface (Cooley *et al.*, 1997). Histologically, depending on the size of the vascular channels involved, the hemangiomas are categorised as capillary or small vessel hemangioma and cavernous hemangioma (Weiss and Goldblum, 2008). Capillary hemangiomas are composed of numerous minute capillaries lined by a single layer of endothelial cells supported in connective tissue stroma of varying density. Cavernous hemangiomas are formed by large, thin-walled vascular spaces or sinusoids that are lined with a single layer of endothelium and are separated by thin septa of connective tissue. Mixed type of capillary cavernous hemangiomas are histologically, characterized by a proliferation of smaller, more capillary-like as well as larger, cavernous blood vessels (Tessieras *et al.*, 2019; Nagameenalochini, 2021). Consequently, similar findings were observed in the present case.

Although capillary and cavernous hemangiomas are frequently seen in dogs, the mixed type of capillary cavernous form of hemangioma is relatively uncommon. A definitive diagnosis and complete surgical excision of hemangiomas is important in predicting the outcome of non

\*Corresponding author: kris\_shyama@yahoo.co.in

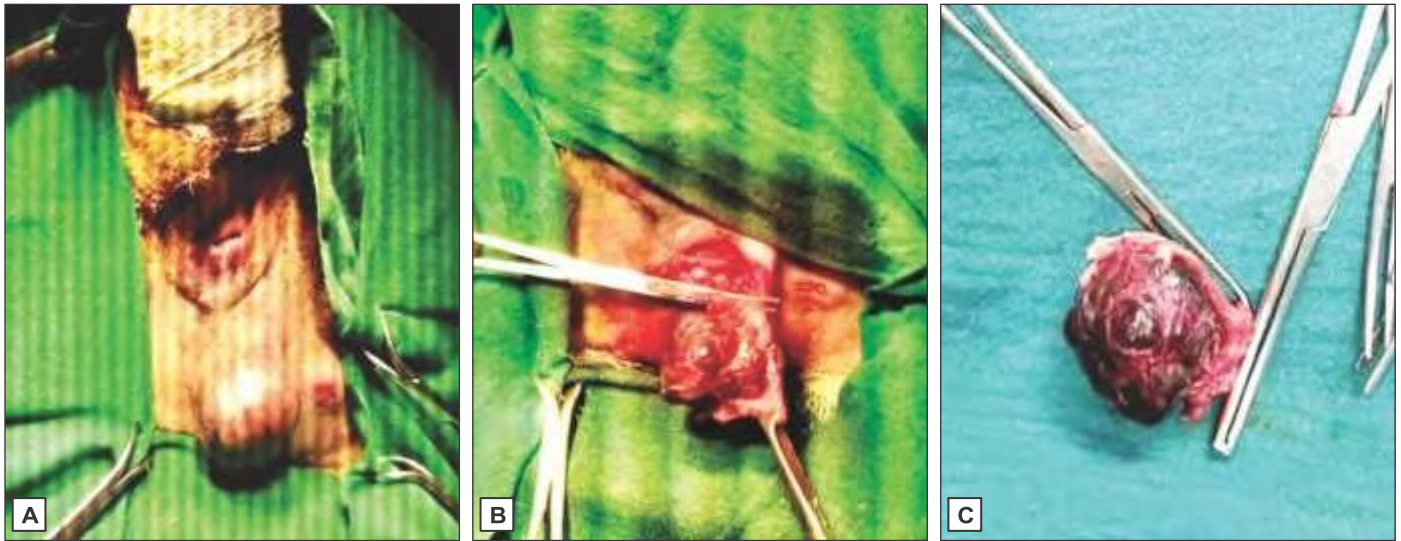


Fig. 1. (A) A small mass was observed subcutaneously in the perineal region below the anal opening. (B) The mass exposed upon skin incision appeared bright red and tuberculated. (C) The mass after surgical excision measuring about 4.5cmX 4cmX 3.5cm indimensions.

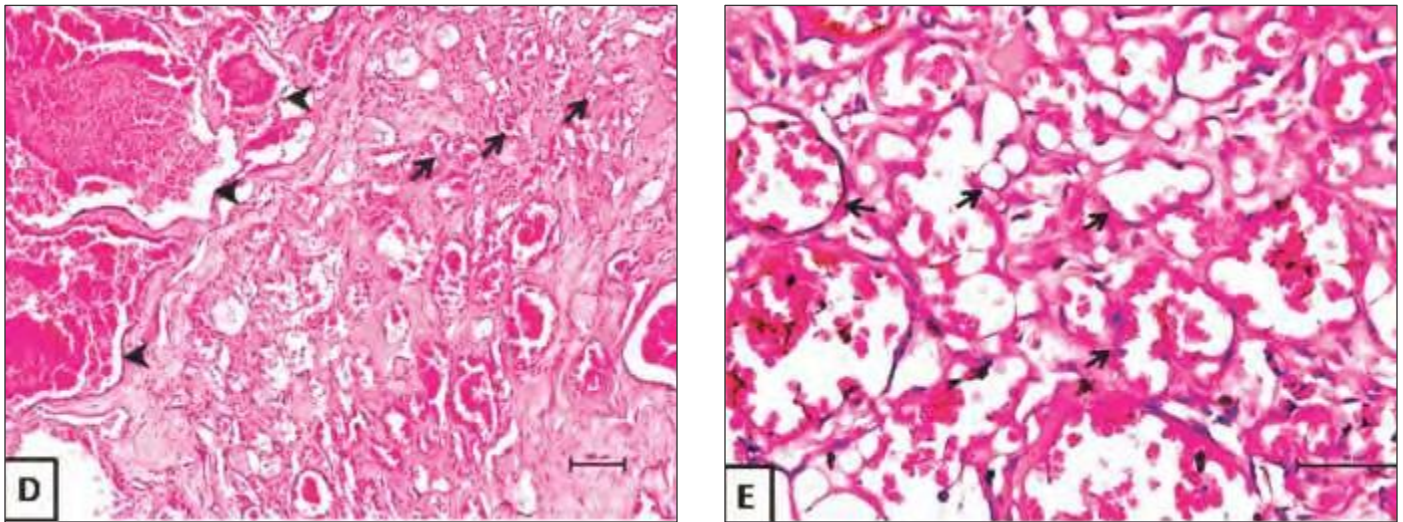


Fig. 1. (D) Section of tumour mass showing multiple dilated capillaries (arrows) as well as large blood-filled vascular spaces (arrow heads) separated by honey comb-like pattern of connective tissue septae H&E 100X. (E) The dilated vascular channels were lined by a single layer of endothelial cells enclosing erythrocytes in their lumen H&E 400X.

visceral hemangiomas (Schultheiss, 2004).

## REFERENCES

- Cooley, D.M., Allen, D.K. and Waters, D.J. (1997). Vascular neoplasms of dogs. *Kleintierpraxis*. **42**(11): 859-870.
- Goldschmidt, M.H., Hendrick, M.J. and Meuten, D.J. (2002). In: Tumors in domestic animals. Tumors of the skin and soft tissues. pp. 84-85.
- Gross, T.L., Ihrke, P.J., Walder, E.J. and Affolter, V.K. (2008). Skin diseases of the dog and cat: Clinical and histopathologic diagnosis. John Wiley & Sons.
- Hargis, A.M., Ihrke, P.J., Spangler, W.L. and Stannard, A.A. (1992). A retrospective clinicopathologic study of 212 dogs with cutaneous hemangiomas and hemangiosarcomas. *Vet. Pathol.* **29**(4): 316-328.
- Nagameenlochini, M. (2021). A review on the histological types of hemangioma. *J. Pharm. Res. Int.* pp. 36-39.
- Pirie, C.G., Knollinger, A.M., Thomas, C.B. and Dubielzig, R.R. (2006). Canine conjunctival hemangioma and hemangiosarcoma: A retrospective evaluation of 108 cases (1989-2004). *Vet. Ophthalmol.* **9**(4): 215-226.
- Schultheiss, P.C. (2004). A retrospective study of visceral and non visceral hemangiosarcoma and hemangiomas in domestic animals. *J. Vet. Diagn. Investig.* **16**(6): 522-526.
- Tessieras, J., Chenaye, J., Senechaud, C. and Banz, Y. (2019). Intranodal capillary-cavernous hemangioma: Report of a very rare case. *SAGE Open Med. Case Rep.* **7**: 2050313X19846710.
- Weiss, S.W. and Goldblum, J.R. (2008). Benign tumors and tumor-like lesions of blood vessels. Enzinger and Weiss's soft tissue tumors. Weiss, S.W. and Goldblum, J.R. (Eds.), Philadelphia: Mosby Elsevier, **22**: 633-670.