

SEVERE GASTROINTESTINAL HELMINTHOSIS IN HIMALAYAN GADDI GOAT WITH A NOTE ON HEMATO-BIOCHEMICAL ALTERATIONS

DIPALI PARMAR*, DEVINA SHARMA, AJAY KATOCH¹, EKTA SINGH and SUBHASH VERMA

Department of Veterinary Parasitology, ¹Department of Veterinary Medicine,
DGCN College of Veterinary and Animal Sciences,
CSK Himachal Pradesh Krishi Vishvavidyalaya, Palampur-176062 (H.P), India

Received: 21.09.2023; Accepted: 01.12.2023

ABSTRACT

Present case dictates about mixed infection with gastrointestinal parasites in a female Gaddi goat that had a usual history of inappetence, lethargy and stomach distress. Clinically, the animal had poor body condition with pale conjunctiva and FAMACHA score of 5. Even though the prognosis was guarded, a thorough clinical examination followed by extensive coprological and hemato-biochemical testing resulted in precise diagnosis thereby, saving the animal's life. The report is probably the first instance to document an excessively high fecal egg count (72, 000) and hyperglycemic state of animal.

Keywords: Gaddi goat, Gastrointestinal parasites, Fecal egg counts, Diagnosis, FAMACHA

How to cite: Parmar, D., Sharma, D., Katoch, A., Singh, E. and Verma, S. (2024). Severe gastrointestinal helminthiasis in himalayan Gaddi goat with a note on hematobiochemical alterations. *The Haryana Veterinarian* 63(1): 69-72.

Gaddi goats are a dual-purpose breed that are native to the Himalayan region and have breed characters suitable for challenging alpine terrain. The breed assists rural economy by providing high-quality animal protein, milk, and fiber (Archana *et al.*, 2009). Gaddi goats are typically raised semi-intensively or as migratory animals, sharing pastures with other ruminants. These rearing practices put the animal at a high risk for endo-parasitic illness, due to larvae pick-up from contaminated pastures (Mandal and Sharma, 2008). Among this, gastrointestinal parasitism (GIP) is the most common and predominant, caused by different helminths. Mostly encountered GI parasites belong to Family Trichostrongylidae, comprising of *Hemonchus contortus* at top, followed by other strongyles in association with *Strongyloides*, *Moniezia*, *Fasciola*, amphistomes and coccidia. Concurrent infections with one or more parasites have been reported (Parmar *et al.*, 2020). The current case puts forth a classical report on co-species infection with GI parasites in Gaddi goat along with complete coprological and hemato-biochemical analysis.

In the month of July, 2023 (the monsoon), a female Gaddi goat aged one year having body weight 14 kg was brought to the Advanced Multispecialty Veterinary Clinics of DGCN COVAS Palampur, Himachal Pradesh, with an usual history of inappetence for the preceding 3 days. The animal's physical appearance was dull and emaciated, with a body condition score of 1 (extremely thin) (Ockert, 2015). During the clinical examination, animal had an elevated heart rate (92 bpm), shallow breathing, and a rectal temperature of 101.9° F with white conjunctiva

having a FAMACHA score of 5. The inter-mandibular region was enlarged with development of bottle jaw. Blood from jugular venipuncture and fecal samples per-rectally were collected and examined as a part of investigation. The results of a hemato-biochemical analysis showed very low range for hemoglobin (2.1 g/dl), PCV (7.2%), TEC (4.41 106/ μ l), RBC (4.41 millions/ μ l), and protein (3.73 g/dl) as well as elevated ALT (28.11 U/L), AST (94.38 U/L) and glucose (222.49 mg/dl) levels (Table 1). Fecal sample was subjected to standard flotation technique using sheather sugar solution, to determine the type of egg (Soulsby, 1982). According to the size and shape, different eggs identified were of *Strongyles*, *Strongyloides*, *Moniezia* spp. and coccidian oocysts (Fig.1).

Egg counting using the modified McMaster technique was done at day 0 (pre treatment), 10 and 21 days (post treatment) to determine the infection gravity. The illness severity was suggested by abnormally high FEC of 72,000; acute instances of *Hemonchus* have been reported with high FECs up to 1,00,000. Female *H. contortus* is prolific breeder with magnificent daily egg production up to 15,000 (Emery *et al.*, 2016). Fentas Plus (fenbendazole and praziquantel) tablet was given to the animal as part of a treatment plan that also included other supportive therapies. As per Rinaldi *et al.* (2014), the effectiveness of the anthelmintic treatment was assessed at days 10 and 21 after treatment. Meanwhile, coproculture was carried out under humid conditions at 27° C for 7 days to know the generic composition of different species of larvae. The larvae were harvested and identified using standardized keys (VanWyk and Mayhew, 2013). As

*Corresponding author: parmardipali93@gmail.com

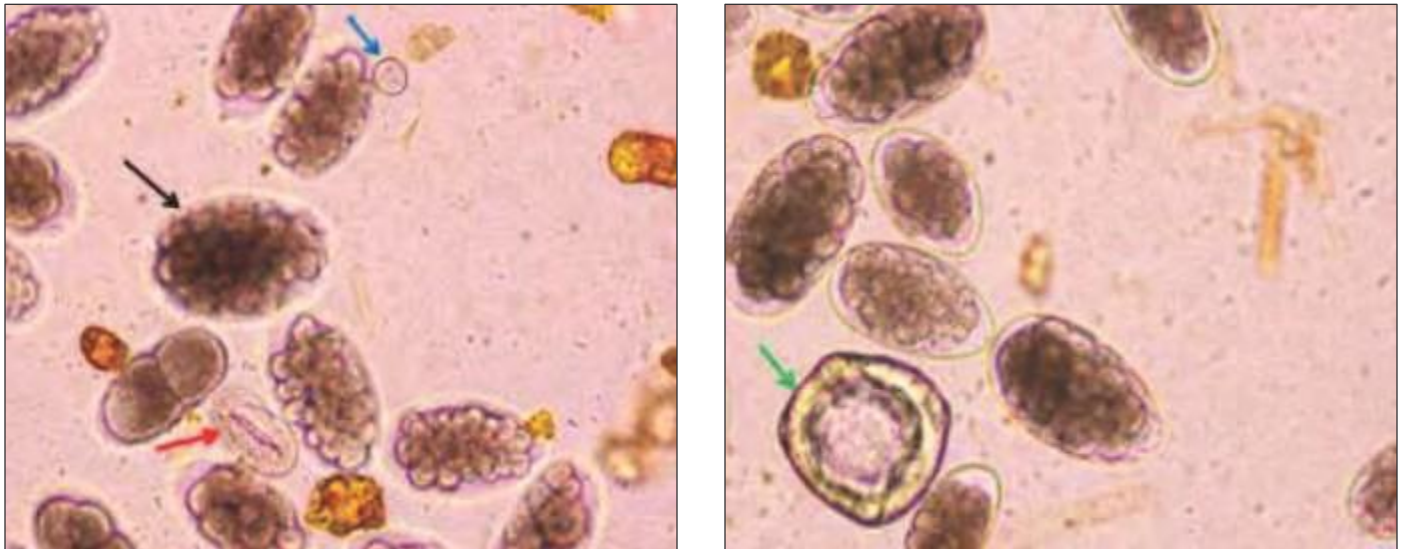


Fig. 1. Microphotograph of different eggs/oocyst depicted by colored arrows (20x): *Strongyle* egg (black), *Strongylodes* (red), coccidian oocyst (blue), *Moniezia* (green)

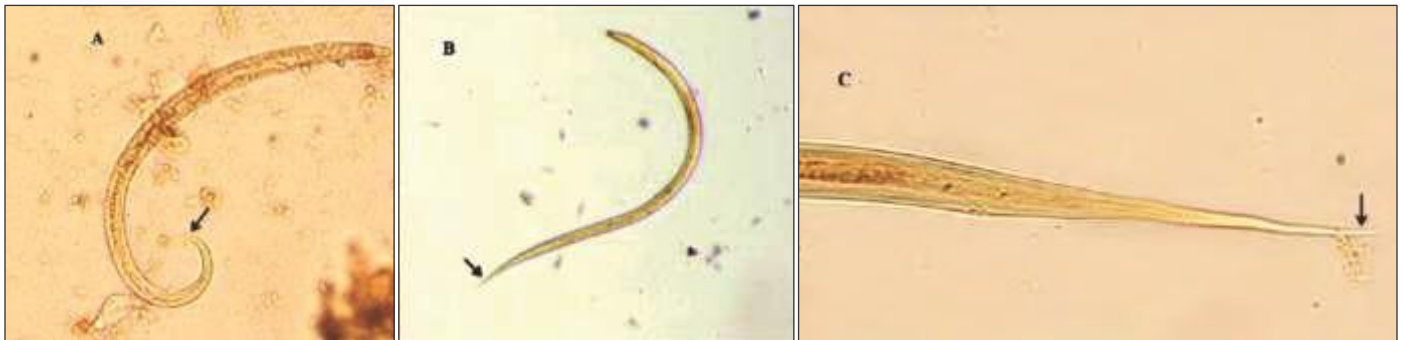

Fig. 2. Microphotographs (10 x) of different strongyle larva recovered by coproculture: (A) *Haemonchus contortus*, (B) *Trichostrongylus* spp. (C) *Oesophagostomum* spp.

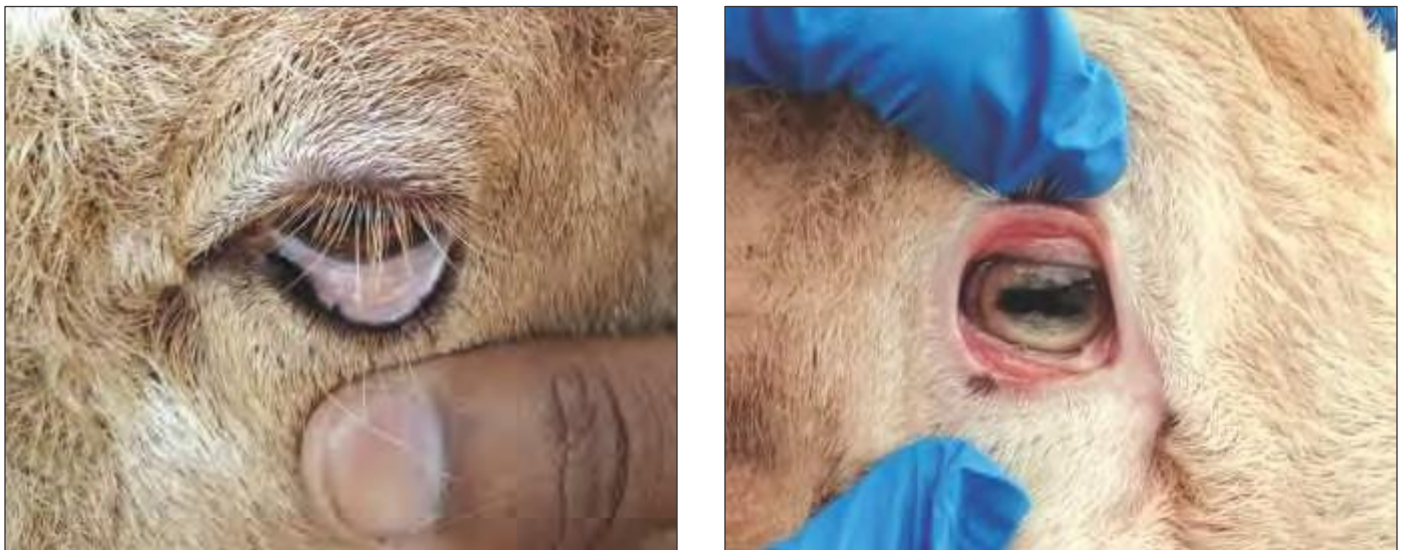


Fig. 3. Physical examination of conjunctiva to assess FAMACHA score: (A) Before treatment (score 5), (B) After treatment (score 1)

evidenced by the presence of 16 intestinal cells and a kink in the tail, the majority of the larvae retrieved belonged to the hematophagus nematode, *Haemonchus contortus*. Second majority was of *Trichostrongylus* followed by *Oesophagostomum*. The presence of a long, filamentous

tail in *Oesophagostomum* and a pointed, pencil-like caudal extremity in *Trichostrongylus* allowed the larvae to be distinguished morphologically (Fig. 2). Other common infections were of cestodes (*Moniezia* spp.) and coccidian parasites. At days 10 and 21, the EPG recorded was 6000

Table 1. Hemato-biochemical parameters of the infected goat

Parameter	Value	Reference Range*	Parameter	Value	Reference Range*
Hemoglobin (g/dl)	2.1	8-14	MCH (Pg)	4.7	10-12
PCV (%)	7.2	19-38	MCHC (g/dl)	290	310-340
WBC/TLC (10 ³ /uL)	22.31	4-13	ALP (U/L)	22.27	93-387
TEC (10 ⁶ /uL)	4.41	8-12	SGOT/AST (U/L)	94.38	13-37
N (%)	60	13-58	SGPT/ALT (U/L)	28.11	6-19
M (%)	3.2	0-11	Bilirubin (mg/dl)	0.13	0-0.1
L (%)	36.5	35-83	Protein (g/dl)	3.73	6.4-7.0
E (%)	0.3	0-8	BUN (mg/dl)	50.48	10-20
B (%)	0	0-2.5	Creatinine (mg/dl)	0.95	1-1.8
RBC (million/uL)	4.41	8-18	Glucose (mg/dl)	222.49	50-75
MCV (fL)	16.3	28-40			

*Reference ranges adapted from Jackson *et al.*, 2002

and 3100, respectively, yielding efficacy of 91.67% and 95.69%.

Global reports indicate that *H. contortus* (Barber's-pole worm) is dominant in mixed infections with GI parasites in pasture-grazed animals. Hot and humid climatic conditions in conjunction with seasonal rains favor parasite expansion. The unique ability of larvae to undergo arrested development, thereby withstanding temperature fluctuations makes infection with GI parasites ubiquitous. Larval activation is what causes an upsurge in animal infection rates following the arrival of rains (Barger, 1999).

A thorough hematological examination showed dropped levels of Hb, PCV, TEC, and RBC indicating anemia. Analysis of the MCV, MCH, and MCHC data revealed its microcytic hypochromic type. Assessing the grade of conjunctiva on Faffa Malan Chart (FAMACHA), a grade of 5 (Fig. 3) was recorded which corresponds to PCV level of 5%, categorizing animal as severely anemic. These findings were consistent and agree with prior studies by Flay *et al.*, 2022. Adults and late larval stages (L5) of *H. contortus* attach to abomasal tissue using a lancet, causing bleeding at the attachment site hence resulting in blood loss (El- Ashram *et al.*, 2017). Prolonged blood loss outpaces iron absorption, resulting in iron insufficiency, which is required for haem synthesis. Furthermore, one adult worm can drain 30-50 μ L of blood per day and a daily loss of 30 mL has been documented in sheep 11 days after infection with 10,000 infective larvae (Roberts and Swan, 1982). Lambs under 20 kg in weight can lose 8g/dl of hemoglobin after acquiring an infection with 112 adult abomasal worms (Flay *et al.*, 2022). The total WBC count (TLC) was high, which could be associated to a hemorrhagic illness (*Hemonchus*) that lowers cell number (Benjamin, 1978).

Biochemical reports showed low levels of total protein, creatinine but elevated levels of ALT, AST, BUN and glucose (Table 1). Hypoproteinemia can be induced by a disruption in the architectural details and physiological functioning of abomasal tissue, which results in protein seepage through broken cell junctions. Moreover, GIT sickness reduces dietary protein uptake and absorption. Furthermore, protein is diverted to mount an effective immune response during active infections as well as required for tissue repair.

A decrease in intravascular osmotic pressure causes fluid to escape from vessels and accumulate on locations with high hydrostatic pressure which resulted in development of bottle jaw condition (Besier *et al.*, 2016). Lower creatinine level is associated with decreased muscle mass as a result of emaciation which was also clinically assessed by poor body condition score. AST and ALT enzyme levels increase during disorders involving soft tissue injury; this was seen in our investigation, and the findings are consistent with past studies. (Moudgil *et al.*, 2017). GIT parasites cause severe harm to the gastrointestinal mucosa and deep muscle layers, resulting in pathogenic effects and elevated enzyme levels. Increased BUN signifies intestinal bleeding disorders and may be due to hematophagus activity of *Hemonchus* (Stockham and Scott, 2013). Alarming high glucose level was observed which may be linked to stress (increased cortisone production) and illness (moribund state) in the animal. Glucocorticoids and catecholamines are released in response to stress, which promotes gluconeogenesis and glycogenolysis and raises blood sugar levels. In the later stages of the disease, the reaction of the adrenal glands causes levels to significantly increase (Benjamin, 1978). Following treatment, the animal showed excellent prognosis as determined by improved BCS (3) and FAMACHA (3) score with reduction in FEC (Fig. 3).

However, the lowest EPG value observed in the study was 3100 after 21 days of treatment, which may be due to resistance of parasite to the drug (fenbendazole) as reported by Parmar *et al.*, 2020 or due to reintroduction of animal to the infected pastures (Moudgil *et al.*, 2017).

The study highlights that gastrointestinal parasite disease, notably hemonchosis, continues to be a major barrier to economic goat production. Anemia in goat induced by *H. contortus* remains a severe concern, making it critical to correctly diagnose, which may be overlooked. So it is important to take the necessary management and prevention methods for gastrointestinal parasitism. One of them may be spelling pastures (no grazing) to let parasite worms die in their free-living infective stages combined with selective and strategic deworming.

REFERENCES

- Archana, P., Katiyar, R.S., Sharma, D.N. and Farooqui, M.M. (2009). Gerontological studies on the gross and histomorphology of the vesicular gland of Gaddi goat (*Capra hircus*). *Int. J. Morphol.* **27**(1): 13-21.
- Barger, I.A. (1999). The role of epidemiological knowledge and grazing management for helminth control in small ruminants. *Int. J. Parasitol.* **29**(1): 41-47.
- Benjamin, M.M. (1978). Outline of veterinary clinical pathology (3rd Edn.). Iowa State University Press.
- Besier, R.B., Kahn, L.P., Sargison, N.D. and Van Wyk, J.A. (2016). Diagnosis, treatment and management of *Haemonchus contortus* in small ruminants. *Adv. Parasitol.* **93**: 181-238.
- El-Ashram, S., Al Nasr, I., Mehmood, R., Hu, M., He, L. and Suo, X. (2017). *Haemonchus contortus* and ovine host: A retrospective review. *Int. J. Adv. Res.* **5**(3): 972-999.
- Emery, D.L., Hunt, P.W. and Le Jambre, L.F. (2016). *Haemonchus contortus*: the then and now, and where to from here? *Int. J. Parasitol.* **46**(12): 755-769.
- Flay, K.J., Hill, F.I. and Muguiro, D.H. (2022). A Review: *Haemonchus contortus* infection in pasture-based sheep production systems, with a focus on the pathogenesis of anaemia and changes in haematological parameters. *Anim.* **12**(10): 1238.
- Jackson, P.G., Cockcroft, P.D. and Elmhurst, S. (2002). Clinical examination of farm animals Oxford: Blackwell Science UK: 303.
- Mandal, A. and Sharma, D.K. (2008). Inheritance of faecal nematode egg count in Barbari goats following natural *Haemonchus contortus* infection. *Vet. Parasitol.* **155**(1-2): 89-94.
- Moudgil, A.D., Sharma, A., Verma, M.S., Kumar, R., Dogra, P.K. and Moudgil, P. (2017). Gastrointestinal parasitic infections in Indian Gaddi (goat) breed bucks: clinical, hemato-biochemical, parasitological and chemotherapeutic studies. *J. Parasit. Dis.* **41**: 1059-1065.
- Ockert, K. (2015). Body condition scoring in goats. *MSU Extension*: 2.
- Parmar, D., Chandra, D., Prasad, A., Sankar, M., Nasir, A., Khuswaha, B., Khare, R. and Kaur, N. (2020). Efficacy of closantel against benzimidazole resistant *Haemonchus contortus* infection in sheep. *Indian J. Anim. Res.* **54**(4): 468-472.
- Rinaldi, L., Levecke, B., Bosco, A., Ianniello, D., Pepe, P., Charlier, J., Cringoli, G. and Vercruysse, J. (2014). Comparison of individual and pooled faecal samples in sheep for the assessment of gastrointestinal strongyle infection intensity and anthelmintic drug efficacy using McMaster and Mini-FLOTAC. *Vet. Parasitol.* **205**(1-2): 216-223.
- Roberts, J.L. and Swan, R.A. (1982). Quantitative studies of ovine haemonchosis. 2. Relationship between total worm counts of *Haemonchus contortus*, haemoglobin values and body weight. *Vet. Parasitol.* **9**(3-4): 217-222.
- Soulsby, E.J.L. (1982). Helminths, arthropods and protozoa of domesticated animals (7th Edn.), Bailliere Tindal London.
- Stockham, S.L. and Scott, M.A. (2013). Fundamentals of veterinary clinical pathology. (2nd Edn.), Wiley Black Well.
- Van Wyk, J.A. and Mayhew, E. (2013). Morphological identification of parasitic nematode infective larvae of small ruminants and cattle: A practical laboratory guide. *Onderstepoort. J. Vet. Res.* **80**(1): 1-14.

RETRACTION OF ARTICLE

This article earlier available at <https://www.luvas.edu.in/haryana-veterinarian/download/harvet2016-dec/1.pdf> entitled “Occurrence of some organochlorine pesticide residues in poultry feed and meat” has been retracted by the authors because of some error made during the data analysis process of the experimental observations due to counting the number of samples showing the concentration of pesticide below its corresponding Limit of Detection. All authors take full responsibility for this mistake and sincerely apologize for any inconvenience it may cause.

Editors