

RECTAL ADENOCARCINOMA IN DOGS: CLINICOPATHOLOGICAL AND HEMATO-BIOCHEMICAL STUDY

SHEETAL DOGRA*, SWARAN SINGH RANDHAWA, KULDIP GUPTA and ARUN ANAND

Department of Veterinary Medicine, College of Veterinary and Animal Sciences,
Guru Angad Dev Veterinary Sciences University, Ludhiana-141 004, Punjab

Received: 12.06.2022; Accepted: 25.07.2022

SUMMARY

Adenocarcinoma is the most common tumour of the large intestine in dogs. Seven unneutered male dogs in between 1 to 9 years age were presented with a history of hematochezia, tenesmus, dyschezia, and chronic weight loss for more than a month. On abdominal palpation, a hard mass was palpated in the terminal parts of the large intestine. Rectal examination revealed a diffuse mass in the rectum of one dog, corrugation of rectal mucosa in two dogs and normal rectal mucosa in four dogs. To rule out other causes of enteropathy, various clinical tests including complete blood count (CBC), serum chemistry and electrolytes, urinalysis, faecal examination, serum ELISA, rectal brush cytology, abdominal radiography, ultrasonography and gastrointestinal endoscopy were performed. Lateral View on abdominal radiography revealed soft tissue density in the rectum in one case and in the colorectal area in two cases. Lung metastasis was seen on thoracic radiography in one case with chronic signs of straining, reduced appetite and weight loss. Ultrasonography showed thickened colon and rectal walls in two cases. Ultrasound-guided FNAC and colonoscopy-guided biopsy of the colorectal mass/mucosa were undertaken in one case each. Rectal brush cytology showed several clusters of loosely adherent round epithelial cells or arranged in rosette-like structures with a small rim of bluish cytoplasm. Histopathology revealed the presence of varying sized tubules of tubular adenocarcinoma and infiltration of mononuclear cells and haemorrhages. Chemotherapy has questionable benefits in such cases.

Keywords: Colonoscopy, Colorectal tumors, Dog, Histopathology, Rectal Brush Cytology

How to cite: Dogra, S., Randhawa, S.S., Gupta, K. and Anand, A. (2023). Rectal adenocarcinoma in dogs: Clinicopathological and hemato-biochemical study. *Haryana Vet.* 62(1): 160-165.

Gastrointestinal tract tumors in dogs are characterized by imprecise clinical presentation and laboratory abnormalities. Imaging techniques plays an important role in the diagnosis of such diseases in routine veterinary practice. Tumors of large intestine are more common in dogs as compared to that of stomach and small intestine. The most vulnerable age group for colonic neoplasia usually range between 1 to 14 years (Simeoni *et al.*, 2021). Most colonic tumors are malignant and include adenocarcinoma, lymphosarcoma and gastrointestinal stromal tumors. A large number of these colonic tumors develop in descending colon and rectum however, leiomyosarcoma usually affect caecum. Benign tumors and polyps do occur but less common than malignant ones. All these tumors are associated with clinical signs of inflammation and obstruction *viz*; hematochezia, tenesmus and dyschezia. Clinical signs depends on which portion of the GI tract is involved and usually include chronic vomiting and/or diarrhea, gastro-intestinal blood loss (hematemesis, melena and/or hematochezia) with weight loss that could result from anorexia, malabsorption and/or maldigestion, loss of protein or generalized tumor cachexia. Laboratory abnormalities may include pan-hypoproteinemia, microcytic hypochromic anemia related to chronic gastro-intestinal blood loss and malabsorption (Gianella *et al.*, 2017 and Simeoni *et al.*, 2021). Rarely, carcinomas have been associated with diarrhoea due to effects of 5-HT on secretion and motility. Adenocarcinoma

(AC) is the most common primary GI malignancy in dogs, while lymphoma is the most common in cats. Adenocarcinomas are seen as the leading colonic neoplasia with occurrence in 43 % of cases followed by lymphosarcoma (19 %), stromal tumors (19 %) and adenomas (17 %) (Washabau and Day, 2013). Goethem (2015) reported that adenocarcinoma is the most common malignant rectal tumor occurring in the mid-to-distal rectum of elderly dogs with more sex predisposition (60-70%) towards male dogs. According to previous studies intestinal carcinomas were observed in male dogs with an average of 9 years age without any breed predisposition. Rectal tumors may cause prolapse and are clinically associated with progressive weight loss, anorexia, presence of mucous and blood in faeces and constipation sometimes. Colorectal carcinomas are classified according to histology as simple adenocarcinoma (papillary, tubular and tubulopapillary), mucinous adenocarcinoma, signet ring cell carcinoma and undifferentiated or solid carcinoma (Head *et al.*, 2002). The incidence of metastasis has been reported 90 per cent in regional lymph nodes and 40 per cent in viscera. Diagnosis in initial stage is difficult because of nonspecific clinical signs, so more than 40 per cent dogs develop metastasis at the time of clinical diagnosis (Paoloni *et al.*, 2002). Rectal examination can be useful in detecting a mass or stricture in most dogs with colorectal adenocarcinoma. Radiography, contrast studies, and ultrasonography are commonly used diagnostic imaging techniques. The main goal of the present study

*Corresponding author: shtl284@gmail.com

was to evaluate the signalment, clinical presentation, laboratory findings, ultrasonographic features and outcome in dogs suffering with rectal adenocarcinoma.

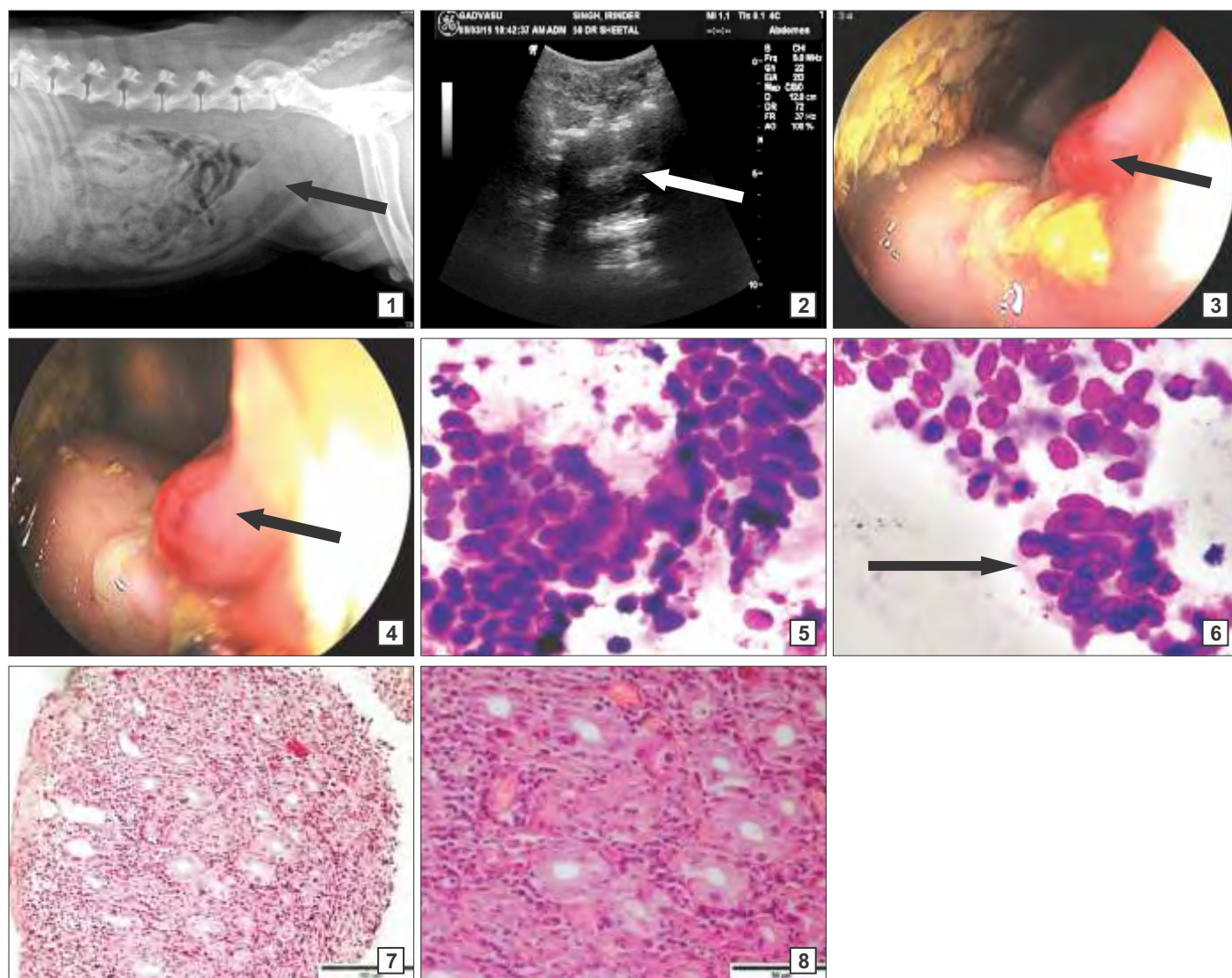
MATERIALS AND METHOD

Seven unneutered male dogs between age group of 1 to 9 years were presented between March, 2018 to December 2019 with the primary complaints of reduced appetite (n=3), tenesmus (n=5), hematochezia (n=2), dyschezia (n=2), swelling at perianal area (n=1) and chronic weight loss (n=4) since 2 months. The general state was active in most of the cases (n=6) but dull in one case at the time of presentation. Abdominal palpation was undertaken in all the cases. Abdominal radiography and ultrasonography were followed to ascertain any abdominal mass. Transrectal palpation of the organ during general medical examination and andrological check up was performed. A complete blood cell count (CBC), serum chemistry, urinalysis, faecal examination, serum ELISA for acute phase proteins (Serum Amyloid A-SAA and C-Reactive Protein-CRP), cobalamine, folate, bile acids, cortisol, Trypsin-Like immuno reactivity (TLI) and Pancreatic- Lipase immunore activity, (PLI), were done to rule out enteropathy of small intestinal, hepatic, renal and endocrine origin; to distinguish these cases from chronic non gastrointestinal disorders. Although, these tests are not routinely performed but to exclude other systemic cause for chronic gastroenteropathies, these tests were committed. Finally, the rectal brush cytology was undertaken in all the cases to diagnose any mucosal or rectal wall abnormalities. Ultrasound-guided FNAC and colonoscopy-guided biopsy of the colorectal mass/mucosa were undertaken in one case each where no diagnosis was possible in rectal brush cytology. The ultrasound-guided fine-needle aspirates were performed by using a 22- or a 20-gauge needle. Flexible endoscopy is preferable since examination and biopsy of the transverse and ascending colons may also be performed. Focal lesions are biopsied directly. In the absence of gross mucosal abnormalities, obtain 3-4 biopsy specimens from each colonic region using serrated jaw pinch biopsy forceps. Colorectal biopsy was followed and processed for histopathological evaluation. Samples were obtained endoscopically or surgically in each dog, fixed in 10% neutral buffered formalin, and routinely embedded in paraffin. The paraffin blocks were cut into 4 μ m thick sections and stained with hematoxylin and eosin (HE). Chemotherapy was done in one case according to standard protocol using Doxorubicin @1mg/kg I/V single dose followed by Vincristine @0.025mg/kg B.wt after one week and then repeated fortnightly for 6 doses. One dog was treated with prednisolone @ 2mg/kg b.wt. P.O. for

one week and then tapered over next two weeks. The delay in the presentation, marked severity of the disease and poor physical condition in 5 dogs made it impossible to undertake chemotherapy in these dogs.

RESULTS AND DISCUSSION

Adenocarcinoma is the most common primary neoplasm of dog's rectum and cat's colon. The mean rectal temperature, heart rate and respiration rate in the dogs suffering with rectal adenocarcinomas were 103.5 ± 0.22 °F, 90.01 ± 2.0 beats/min and 108.40 ± 2.33 breaths/min, respectively. Regarding the incidence of age and gender, older dogs are the most affected even if the age range is large (from 1 to 14 years of age); males are more frequently affected than females (Paoloni *et al.*, 2002). The mean value of haemoglobin, TEC, PCV and TLC was 13.41 ± 0.71 g/dl, 5.35 ± 0.43 , 10.99 ± 2.50 and 17295.71 ± 3002.99 , respectively. The mean neutrophil, lymphocyte, eosinophil and platelet count was recorded as 81.43 ± 6.60 , 15.14 ± 5.96 , 3.43 ± 1.84 and $379.57 \pm 85.29 \times 10^3/\mu$ l, respectively (Table 1). Laboratory abnormalities may include panhypoproteinemia, microcytic hypochromic anemia related to chronic gastro-intestinal blood loss and malabsorption. Similar findings were reported by Terragni *et al.* (2014) and Gianella *et al.* (2017) in their studies. Mean ALT, ALKP, total protein, albumin, BUN, creatinine, sodium, potassium, calcium and cholesterol levels in affected dogs were 43.00 ± 9.83 IU/L, 94.43 ± 13.45 IU/L, 6.56 ± 0.39 g/dl, 2.83 ± 0.26 g/dl, 13.00 ± 1.41 mg/dl, 0.80 ± 0.07 mg/dl, 146.86 ± 10.42 mg/dl, 5.11 ± 0.44 mg/dl, 8.77 ± 0.61 mg/dl and 182.29 ± 9.59 mg/dl, respectively (Table 2). Oliveira *et al.* (2018) recorded normocytic, normochromic anemia associated with neutrophilic leukocytosis and thromocytosis. Paoloni *et al.* (2002) reported hypoalbuminemia, elevation in ALT, ALKP, decreased Ca, Na and potassium levels in 15 dogs affected with rectal adenocarcinoma. Mean values of parameter SAA, CRP, Bile Acid, Cortisol, Folic Acid, Cobalamin, TLI and PLI were 0.20 ± 0.10 (μ g/ml or mg/L), 1.08 ± 0.57 (μ g/ml or mg/L), 0.65 ± 0.41 (mmol/L), 10.01 ± 5.78 (μ g/dL), 6.05 ± 3.81 (ng/ml or μ g/L), 3.51 ± 2.19 (ng/ml), 13.21 ± 8.26 (μ g/L) and 10.48 ± 5.99 (μ g/L), respectively (Table 3). No remarkable changes were seen in the levels of CRP, TLI, PLI, Cortisol, folic acid and Bile whereas decreased level of serum amyloid A and non-significant increased level of cobalamin was noted. CRP and SAA levels in the blood rise sharply in the first few hours following inflammatory stimulation, then swiftly return to baseline during the recovery phase (Ecker *et al.*, 2016). No report is available in literature regarding the effect of rectal adenocarcinoma on acute phase proteins and all other markers mentioned above.



Figs. 1-8. (1) Radiograph showing soft tissue density (black arrow) at rectum region in German Shepherd dog; (2) Ultrasonograph showing soft tissue density of rectum in Dachshund dog; (3) Rectal brush cytology showing large no of pleomorphic cells indicating rectal carcinoma (Leishman stain x 100 X); (4) Rectal brush cytology showing pleomorphic changes (Cluster formation) in the epithelial cells (Black arrow) indicating rectal adenocarcinoma (Leishman stain x 100 X); (5) Colonoscopy showing growth (Black arrow) in one site of colon in one case; (6) Colonoscopy showing growth (Black arrow) in another site of colon in one case; (7) Histopathology showing infiltration of mononuclear cells, hemorrhages are seen indicating adenocarcinoma. (H.E.) x 20X; (8) Histopathology revealing presence of varying size tubules suggestive of tubular adenocarcinoma along with mononuclear cells infiltration. (H.E.) x 40X

Table 1. Hematological Parameters in dogs suffering from Rectal adenocarcinoma

S.No.	Parameter	Rectal Adenocarcinoma (n=7)
1.	Hb (g/dl)	13.41 ± 0.71
2.	TEC 10 ⁶ /μl	5.35 ± 0.43
3.	PCV (%)	40.99 ± 2.50
4.	TLC 10 ³ /μl	17295.714 ± 3002.99
5.	Neutrophil (%)	81.43 ± 6.60
6.	Lymphocyte (%)	15.14 ± 5.965
7.	Eosinophil (%)	3.43 ± 1.84
8.	Platelets 10 ³ /μl	379.57 ± 85.29

Table 2. Biochemical Parameters in dogs suffering from Rectal adenocarcinoma

S.No.	Parameter	Rectal Adenocarcinoma (n=7)
1.	SGPT (IU/L)	43.00 ± 9.83
2.	ALKP (IU/L)	94.43 ± 13.45
3.	Total protein (g/dl)	6.56 ± 0.39
4.	Albumin (g/dl)	2.83 ± 0.26
5.	BUN (mg/dl)	13.00 ± 1.41
6.	Creatinine (mg/dl)	0.80 ± 0.07
7.	Sodium (mg/dl)	146.86 ± 10.42
8.	Potassium (mg/dl)	5.11 ± 0.44
9.	Calcium (mg/dl)	8.77 ± 0.61
10.	Cholesterol (mg/dl)	182.29 ± 9.59

Table 3. Acute Phase Proteins and other markers in dogs suffering from rectal adenocarcinoma

S.No.	Parameter	Rectal Adenocarcinoma (n = 7)
1.	SAA (µg/ml or mg/L)	0.20±0.10
2.	CRP (µg/ml or mg/L)	1.08±0.57
3.	Bile Acid (mmol/L)	0.65±0.41
4.	Cortisol (µg/dL)	10.01±5.78
5.	Folic Acid (ng/ml or µg/L)	6.05±3.81
6.	Cobalamin (ng/ml)	3.51±2.19
7.	TLI (µg/L)	13.21±8.26
8.	PLI (µg/L)	10.48±5.99

According to study of Bazzano *et al.*, 2022, acute phase proteins acts as nonspecific markers of systemic inflammatory processes for a timely assessment of health status in veterinary medicine and SAA as specific may improve early diagnostic tools for dogs, cats, cattle, and equines and for the diagnosis and monitoring of reproductive disorders in animals. Moreover, the major positive APP in dogs is the C-reactive protein (CRP) as its concentration changes very quickly with the onset and elimination of the inflammatory stimulus. Previous studies by Hindenberg *et al.*, 2020 and Malin and Witkowska-Piłaszewicz, 2022, observed altered levels within the first 4-24 h after the stimulus and reaches up to a 50-100-fold increase. In other studies, it has been documented that APP's concentration is elevated in several diseases, such as pyometra, panniculitis, acute pancreatitis, polyarthritis, sepsis, immune-mediated hemolytic anemia, and neoplasia in dogs. However, in a very recent study by (Lee *et al.*, 2021), the CRP levels were indicative of duodenal histopathologic severity marker but no differences in CRP concentrations were found in dogs with IBD and other chronic gastrointestinal diseases.

Prostate cancer is a common problem in older male dogs. Prostatic adenocarcinoma is highly metastatic cancer that spreads quickly to other parts of the body. Depending on the size and placement of the tumor, it may put pressure on the rectum and cause problems with defecation as well. Exact cause of prostatic adenocarcinoma is unknown but risk factors such as environment and genetics may play a role. A possible linkage between neutering too early in life and the increased risk of prostatic adenocarcinoma has been described by DeJaynes, J. (2021).

Rectal examination revealed diffuse mass in rectum (1), corrugation of rectal mucosa in 2 and normal rectal mucosa in 4 dogs. Rectal examination has been reported to be useful in detecting a mass or stricture in most of dogs with colorectal adenocarcinoma. However, in our

study, only 43 per cent cases of rectal adenocarcinoma were diagnosed on the basis of rectal examination.

Faecal samples were negative for ova/cyst in all the dogs affected with rectal adenocarcinoma. Oliveira *et al.* (2018) also observed similar results and negative results of faecal examination.

Abdominal palpation revealed a hard mass/thickened loops of colon palpated in the posterior abdomen. Radiography showed soft tissue density pressing colon ventrally with loss of layering of colon in two cases (German Shepherd (GS) and Daschund) (Fig. 1) but in rest of dogs, no abnormality was detected on radiography. Lung metastasis was evident in one GS dog on thoracic radiography. Lung metastasis was earlier reported by Oliveira *et al.* (2018) in dogs with rectal adenocarcinoma. In the present study, ultrasonography was helpful in two dogs (German Shepherd (GS) and Daschund) shown rectal wall thickness extending to the colon wall, causing constipation due to a decrease in the lumen of the rectum (Fig. 2). Similar sonographic findings were recorded by Oliveira *et al.* (2018) in rectal adenocarcinoma dogs. However, previous studies documented ultrasonography has the high efficacy (84 %) in diagnosing colonic tumors in dogs and cats. Colonoscopy was done in single cases of chronic gastroenteritis, lately diagnosed as Adenocarcinoma in our study (Figs. 5 & 6). Small polyp like structure was seen in colonoscopy along the rectal mucosal lining. Histopathology revealed presence of varying size tubules suggestive of tubular adenocarcinoma along with mononuclear cells infiltration in one dog. A small number of erythrocytes and occasional non-degenerate neutrophils and large mononuclear cells were also seen. Colonoscopy is indicated for the diagnosis of colitis-type diarrhea unresponsive to dietary modification and medical therapy, suspected colorectal neoplasia, chronic constipation and stricture.

Make a diagnosis is not always easy due to the non specific clinical signs and the possible overlap of different pathologies. Rectal brush cytology was helpful in diagnosing rectal adenocarcinoma in 5 dogs and ultrasound-guided FNAC and colorectal biopsy were required in one case each. A large cluster of pleomorphic epithelial cells and bluish cytoplasm indicated rectal adenocarcinoma in rectal brush cytology and FNAC (Figs. 3 & 4). A moderate amount of rounded to columnar epithelial cells with moderate pleomorphism and increased nucleus cytoplasm ratio and dark stained chromatin was also reported by Oliveira *et al.* (2018). Histopathology from one case revealed the presence of varying sized tubules suggestive of tubular adenocarcinoma along with mononuclear cells infiltration

in one dog. A small number of erythrocytes and occasional non-degenerate neutrophils and large mononuclear cells were also seen (Figs. 7 & 8). Head *et al.* (2002) also classified colorectal carcinomas on the basis of histological findings as simple adenocarcinoma (papillary, tubular, and tubulopapillary), mucinous adenocarcinoma, signet ring cell carcinoma, and undifferentiated or solid carcinoma. Uchida *et al.* (2016) compared histopathologic characteristics of colorectal inflammatory polyps with other colorectal proliferative lesions (adenomas and adenocarcinomas) in Miniature Dachshunds. Saito *et al.* (2018) observed the difference in the histopathological findings when repeated biopsy samples of colorectal polyps were processed from 67 Miniature Dachshund dogs. On basis of histopathological findings, they were divided into inflammatory polyp in 52 cases (78%), adenoma in 10 cases (15%), and adenocarcinoma in 5 cases (8%). They recommended that the inflammatory polyp is a progressive disease that may develop into adenoma and further into adenocarcinoma. In addition, immuno histochemical findings showed beta-catenin expression within the inflammatory polyp lesions that may involve in tumor development.

Chemotherapy was done in one case according to standard protocol using Doxorubicin @1mg/kg I/V single dose followed by Vincristine @0.025mg/kg B.wt after one week and then repeated fortnightly for 6 doses. One dog was treated with prednisolone @2mg/kg b.wt. P.O. for one week and then tapered over next two weeks. Although most of the palliative treatment in our study showed only partial reduction in tumor size or transient improvement of clinical signs. The delay in the presentation, marked severity of the disease and poor physical condition in 5 dogs made it impossible to undertake chemotherapy. In other two dogs chemotherapy and steroidal therapy was given which was unsuccessful. The dog on Doxorubicin and Vincristine protocol responded and passed faeces comfortably upto 2 months but thereafter, when the animal was presented for fifth dose of vincristine, the rectal lumen became more narrow, the rectal wall thickness increased and animal started showing dyschezia again. Patient was euthanized as per owner consent due to increase in the size of the tumour and a decline in the physical condition of the dog. According to Hankin, S.J. (2009), the decision is to be made in the best interest of the animal's quality of life based on a terminable illness or suffering of the animal as euthanasia relieves the animal from pain, avoiding unnecessary prolonging of the animal's suffering and distress. Little response was noted in the dog on prednisolone therapy but lately dog died after 2 weeks before start of chemotherapy. Other 4 dogs died before the start of

chemotherapy within one week of presentation. The last dog presented in November, 2019 was not given any chemotherapy because of poor body condition was still surviving for more than 400 days. However, metastasis was seen as multiples lumps all over the body. Similarly, Smith (2019) denied the usefulness of adjuvant chemotherapy for the treatment of dogs with adenocarcinoma. Although they estimated the survival time for dogs with small intestinal adenocarcinoma after surgical excision of tumor with or without adjuvant chemotherapy. In previous another studies by Eckser (2016) and Yamazaki *et al.* (2021), it was reported that dogs who has undergone tumor excision showed longer median survival time (544 days) and dogs <8 years of age had a significantly longer survival time (1,193 days) than dogs ≥ 8 years (488 days). They documented a fair prognosis in dogs opted for surgical excision even when lymph node metastasis is present. Earlier study documented medial survival time in 15 dogs treated with surgery from of 233 days with range between 5 to 784 days and mean of 267 days. They observed gender as the single variable having a significant relationship with survival. Three female dogs have a mean survival period of 29 days as compared to 12 male dogs with mean survival period of 326 days. Contrarily, in the present study, all the dogs with adenocarcinomas were male and the mean survival period was 7 to > 400 days. Longer mean survival time for adenocarcinoma in the large intestine was also recorded by Ohmi *et al.* (2021), which was 1,973 days. Usually, the treatment is not curative and is associated with poor prognosis.

In conclusion, in the present study all the seven male, unneutered dogs were diagnosed with rectal adenocarcinoma. Rectal brush cytology was diagnostic in more than 70 per cent (5 out of 7) of the cases of the rectal adenocarcinoma. Limitation of the present study include its retrospective nature, small sample size, and lack of standardized surgical and medical treatment protocol. However, identification of the type of tumour was possible in one dog only as histopathology was undertaken in only that dog. Some cases were diagnosed by endoscopic biopsy rather than full- thickness biopsy, which could have affected the results of the histopathological diagnosis. Ideally, all histologic samples would have been reviewed by a single pathologist. Postmortem examinations were not available for any case.

REFERENCES

- Bazzano, M., Marchegiani, A., Troisi, A., McLean, A. and Laus, F. (2022). Serum Amyloid A as a promising biomarker in domestic animals' reproduction: current knowledge and future perspective. *Animals*. **12**(5): 589.
- Cohn, L. A. and Côté, E. (2020). Cote's Veterinary Clinical Advisor

Dogs and Cats. (4th Edn.) Elsevier. pp. 828-831.

- Dejaynes J. (2021). Prostate Cancer in Dogs (Prostatic Adenocarcinoma). [PETMD.com]
- Ecker, B.L., McMillan, M.T., Datta, J., Mamtani, R., Giantonio, B.J., Dempsey, D.T. and Roses, R.E. (2016). Efficacy of adjuvant chemotherapy for small bowel adenocarcinoma: a propensity score-matched analysis. *Cancer*. **122**(5): 693-701.
- Gianella, P., Pietra, M., Crisi, P.E., Bergamini, P.F., Fracassi, F., Morini, M. and Boari, A. (2017). Evaluation of clinico-pathological features in cats with chronic gastrointestinal signs. *Pol. J. Vet. Sci.* **20**(2): 403-410.
- Goetem, B.V. (2015). Rectal tumors (Choose the Appropriate Approach) WSAVA, 40th World Congress Proceedings 15-18th, May.
- Hankin, S.J. (2009). Making decisions about our animals' health care: Does it matter whether we are owners or guardians. *Stan. J. Animal L. and Pol'y.* **2**: 1.
- Head, K.W., Else, R.W. and Dubielzig, R.R. (2002). Tumors of the intestines In: Meuten DJ, Tumors in Domestic Animals (4th Edn.) Iowa City, IA: Iowa State Press, pp. 461-468.
- Hindenberg, S.; Bauer, N.; Moritz, A. (2020). Extremely high canine C-reactive protein concentrations > 100 mg/L-Prevalence, etiology and prognostic significance. *BMC Vet. Res.* **16**: 147.
- Lee, J.H., Kim, H.S., Lee, D., Yun, T., Koo, Y., Chae, Y., Kang, J.H., Kang, B.T., Yang, M.P. and Kim, H. (2021). Clinical signs, duodenal histopathological grades, and serum high-mobility group box 1 concentrations in dogs with inflammatory bowel disease. *J. Vet. Intern. Med.* **35**: 2205-2214.
- Malin, K. and Witkowska-Piłaszewicz, O. (2022). C-Reactive Protein as a diagnostic marker in dogs: A review. *Animals*. **12**(20): 2888.
- Oliveira, A.R., Flecher, M.C., Horta, R.S., Souza, M.C.C., Hardt, I., Gonçalves, A.B.B. and Souza, T.D. (2018). Tubulopapillary rectal adenocarcinoma in dog: clinical, surgical, pathological and immunophenotypical aspects: case report. *Arq. Bras. Med. Vet. Zootec.* **70**: 463-468.
- Paoloni, M.C., Penninck, D.G. and Moore, A.S. (2002). Ultrasonographic and clinicopathologic findings in 21 dogs with intestinal adenocarcinoma. *Vet. Radiol. Ultrasound*. **43**(6): 562-567.
- Saito, T., Chambers, J.K., Nakashima, K., Uchida, E., Ohno, K., Tsujimoto, H., Uchida, K. and Nakayama, H. (2018). Histopathologic features of colorectal adenoma and adenocarcinoma developing within inflammatory polyps in Miniature Dachshunds. *Vet. Pathol.* **55**: 654-662.
- Simeoni, F., Del Signore, F., Aste, G., Bargellini, P., Rubini, G., Terragni, R. and Vignoli, M. (2021). B-mode and contrast enhanced ultrasonography features of gastric inflammatory and neoplastic diseases in dogs. *Animals*. **11**(3): 670.
- Terragni, R., Vignoli, M., Van Bree, H.J., Gaschen, L. and Saunders, J.H. (2014). Diagnostic imaging and endoscopic finding in dogs and cats with gastric tumors: a review. *Schweiz. Arch.* **156**(12): 569-576.
- Washabau, R.J. and Day, M.J. (2013). Canine and Feline Gastroenterology (1st Edn.), Elsevier Saunders, St. Louis, MO, USA, ISBN: 978-1-4160-3661-6.
- Yamazaki, H., Sasai, H., Tanaka, M., Tanaka, T., Nishida, H., Noguchi, S. and Akiyoshi, H. (2021). Assessment of biomarkers influencing treatment success on small intestinal lymphoma in dogs. *Vet. Comp. Oncol.* **19**(1): 123-131.

THE HARYANA VETERINARIAN

Editors/Editorial Board Members are highly thankful to all the distinguished referees who helped us in the evaluation of articles. We request them to continue to extend their co-operation and be prompt in future to give their valuable comments on the articles for timely publication of the journal.