

## THE EFFECT OF TEMPERATURE ON CLEARING OF TISSUES WITH NATURAL ALTERNATIVES TO XYLENE IN TISSUE PROCESSING

POONAM\*, M. KUMARI, A. RATHORE, R. SINGATHIA<sup>1</sup>, K. PUROHIT, G. SINGH, A. SAINI, GUNJAN and RASHMI

Department of Veterinary Pathology, <sup>1</sup>Department of Veterinary Microbiology,  
College of Veterinary and Animal Science, Navania, Udaipur-313601  
Rajasthan University of Veterinary and Animal Sciences, Bikaner- 334001

Received: 14.03.2022; Accepted: 16.06.2022

### SUMMARY

Xylene, commonly used as a clearing agent, is highly toxic, carcinogenic and poses a threat to histopathology laboratory personnel. The aim of this study was to evaluate the efficacy of coconut oil, groundnut oil, liquid paraffin, mustard oil, and sesame oil at a maintained temperature (40° C) as compared to xylene maintained at room temperature for 30 minutes as a safer alternative to act as clearing agent during tissue processing in histopathological laboratories. A total of 18 tissue samples of liver were collected from goat carcasses fixed in 10% Neutral Buffered Formalin and sectioned into six groups, group 1 control (Xylene), Group 2 (Coconut oil), Group 3 (Groundnut oil), Group 4 (Liquid paraffin), Group 5 (Mustard oil), and Group 6 (Sesame oil). A comparison was done between xylene and natural alternative-treated specimens with regard to ease of sectioning, quality of staining, clarity, and overall staining quality. When cellular details and staining quality were examined, no statistically significant differences were observed in either section. It was observed that clearing of tissues were achieved with oils at this temperature at par with xylene, so in contrast to hazardous xylene, these alternatives can be used as clearing agents without compromising histological details.

**Keywords:** Clearing, Coconut oil, Groundnut oil, Liquid paraffin, Mustard oil, Sesame oil, Tissue processing, Xylene.

**How to cite:** Poonam, Kumari, M., Rathore, A., Singathia, R., Purohit, K., Singh, G., Saini, A., Gunjan and Rashmi (2023). The effect of temperature on clearing of tissues with natural alternatives to xylene in tissue processing. *Haryana Vet.* 62(1): 147-150.

Histopathological examination of tissues is a routine standard test for diagnosis of diseases. For this fixation, dehydration, clearing, and embedding are the four main steps, followed by the sectioning and staining of the tissue (Rahmawati *et al.*, 2020). The process of clearing is essential in preparing histological sections, as it removes dehydrants such as alcohol/acetone from tissues prior to embedding in a material (usually paraffin wax). Xylene, chloroform, toluene, methyl salicylate, methyl benzoate, and cedarwood oil are some of the clearing agents used in tissue processing. Xylene is commonly used because it is miscible with both alcohol and paraffin (Chandraker *et al.*, 2018). Xylene (Dimethyl benzene) occurs naturally in petroleum as well as coal tar and can also form in small quantities during forest fires. It is a colourless, flammable liquid with a sweet smell. As per Occupational Safety and Health Administration (OSHA), its permissible exposure limits are 100 parts per million parts of air (ppm) over 8-hours and 200 ppm for 10 minutes as a short-term exposure limit (Bordoloi, 2018).

The toxic effects of “xylene” are caused by inhalation, ingestion, and contact with the eyes or skin (Rahmawati *et al.*, 2020). Researchers have shown that laboratory workers exposed to xylene for 1.5 to 18 years had symptoms similar to general poisoning disorders including pancytopenia and bone marrow toxicity (Erickson *et al.*, 1994). Hazardous effects of xylene include depression of the central nervous system with symptoms such as nausea,

headache, dizziness, and vomiting. Long-term exposure may lead to insomnia, irritability, extreme tiredness, tremors, agitation, impaired concentration and short-term memory (Kandyala *et al.*, 2010). In order to improve the safety of the working environment in histologic laboratories, the health hazards of xylene exposure should be reduced (Dapson, 2005). There were great concerns about its safety with evidence that its acute neurotoxicity was greater than that of benzene or toluene. It acts as an irritant in mild form and as a carcinogen in its severe form. Some alternatives to “xylene” have been investigated, like limonene reagents, aliphatic hydrocarbons, mineral oils and vegetable oils on soft tissues like skin, buccal mucosa, salivary gland, tendon, muscle and lymph nodes. Good histological details were found with these alternate clearing agents (Sermadi *et al.*, 2014; Saravanakumar *et al.*, 2019). The natural oils (vegetables and minerals oil) can be a better alternative as routine chemical clearing agents because they are safe, readily available and less expensive. Therefore, the present study was designed to compare the efficacy of natural oils as clearing agents in place of chemicals for clearing during tissue processing for histopathological examination of animal tissues.

**Tissue sample collection-** A total of 18 liver tissue specimens of liver were collected from carcass of goat submitted for post-mortem examination in the department of Veterinary Pathology, College of Veterinary and Animal Science, Navania, Vallabh Nagar, Udaipur. They were fixed

\*Corresponding author: jayalwalpoonam1995@gmail.com

in 10% formalin and sectioned in 6 equal parts and grouped as group 1, 2, 3, 4, 5, and 6 (tissues taken in triplicates for each group).

**Tissue processing-** The formalin fixed tissues were washed overnight in running tap water and processed for paraffin embedding technique (Lillie, 1965). After washing tissues were dehydrated in 70% alcohol for 1 hour and then in acetone for 1 hour in each change (I, II, and III). After dehydration, clearing was done with Xylene in Group 1 (as a Control) - for 30 minutes in each change (I, II, and III) at room temperature and with natural alternatives in other groups (Group 2-Coconut oil, Group 3- Groundnut oil, Group 4-Liquid paraffin, Group 5- Mustard oil, and Group 6- Sesame oil) for 3 changes of 30 minutes at 40° C each as clearing agents. The cleared tissues were then embedded in 4 changes of molten paraffin wax (wax I, II for 45 minutes and wax III, IV for 30 minutes) and blocks were prepared.

**Histopathological examination-** Tissue blocks were sectioned (4-5 µm), and stained using Hematoxylin and Eosin (H&E) and were observed for evaluation of nuclear staining, cytoplasmic staining, clarity and overall quality of stained slide under low and high power of microscope. The slides were evaluated in terms of quality of staining as follows:

Features	Score and criteria
Nuclear staining	0- Out of focus and unclear nuclear membrane 1- Clear staining and nuclear membrane 2- Smooth and clear staining with good contrast
Cytoplasmic staining	0- Out of focus 1- Cytoplasm clear 2- Clear smooth cytoplasm, clear nuclear membrane, good contrast
Clarity of staining	0- Not clear, hazy, out of focus 1- Clear staining throughout the slide 2- Crisp and contrast staining

The data was analyzed and interpreted by using ANOVA and significant differences between groups were evaluated using Tukey post hoc test using software.....

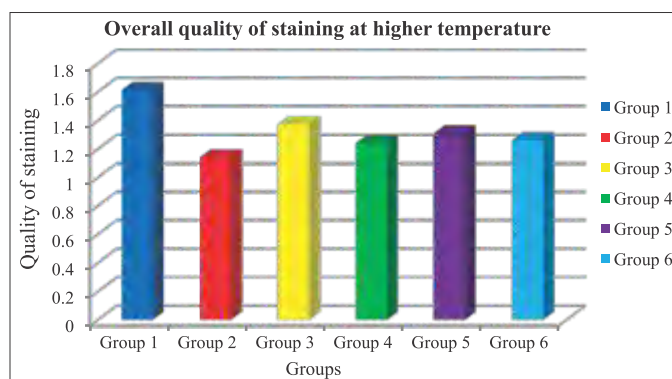
It was observed in the present study, that these natural alternatives had ability to clear tissue and maintain cellular architecture, a similar property to that of xylene. These oils are nontoxic and can be recycled. All the stained slides were assessed for nuclear staining and compared

**Table 1. Clearing of tissues by using different clearing agents at room temperature and 40° C**

Groups	Reagents	Temperature	Time
Group-1 (Control)	Xylene	Room temp.	30 minutes
Group-2	Coconut oil	40° C	30 minutes
Group-3	Groundnut oil	40° C	30 minutes
Group-4	Liquid paraffin	40° C	30 minutes
Group-5	Mustard oil	40° C	30 minutes
Group-6	Sesame oil	40° C	30 minutes

with group 1 as a control group, all natural alternatives (group 2, group 3, group 4, group 5, and group 6) were found statistically non-significant (Table 2) difference. Quality of staining of all stained slides were evaluated for cytoplasmic staining and compared with group 1 as a control group, all natural alternatives (group 2, group 3, group 4, group 5, and group 6) were also found statistically non- significant (Table 2) difference. When all the stained slides were assessed for clarity of staining and compared with group 1 as a control group, group 6 (sesame oil) showed statistically significant difference with xylene, whereas group 2, 3, 4, and 5 statistically non- significant values at ( $p < 0.05$ ) (Table 2). Overall quality of staining of all stained slides at higher temperature (group 1, group 2, group 3, group 4, group 5, and group 6) were found statistically non-significant values at ( $p < 0.05$ ), when compared with group 1 as a control group (Table 2 and Fig. 1).

The results of clearing the tissues with natural alternatives at higher temperature (40° C) revealed that the tissues were cleared and the staining quality was at par with control group. This suggests that high temperature increased the rate of penetration of the oils so better clearing could be achieved in reduced time. Bernoulli's principle states that fluid dynamics viscosity depends on temperature. As a temperature increases, viscosity decreases and fluid penetration increases (Rahmawati *et al.*, 2020). Digala *et al.* (2013) and Saravanakumar *et al.* (2019) found



**Fig. 1. Histogram showing mean score of overall quality of staining of tissues of various groups cleared at higher temperature**



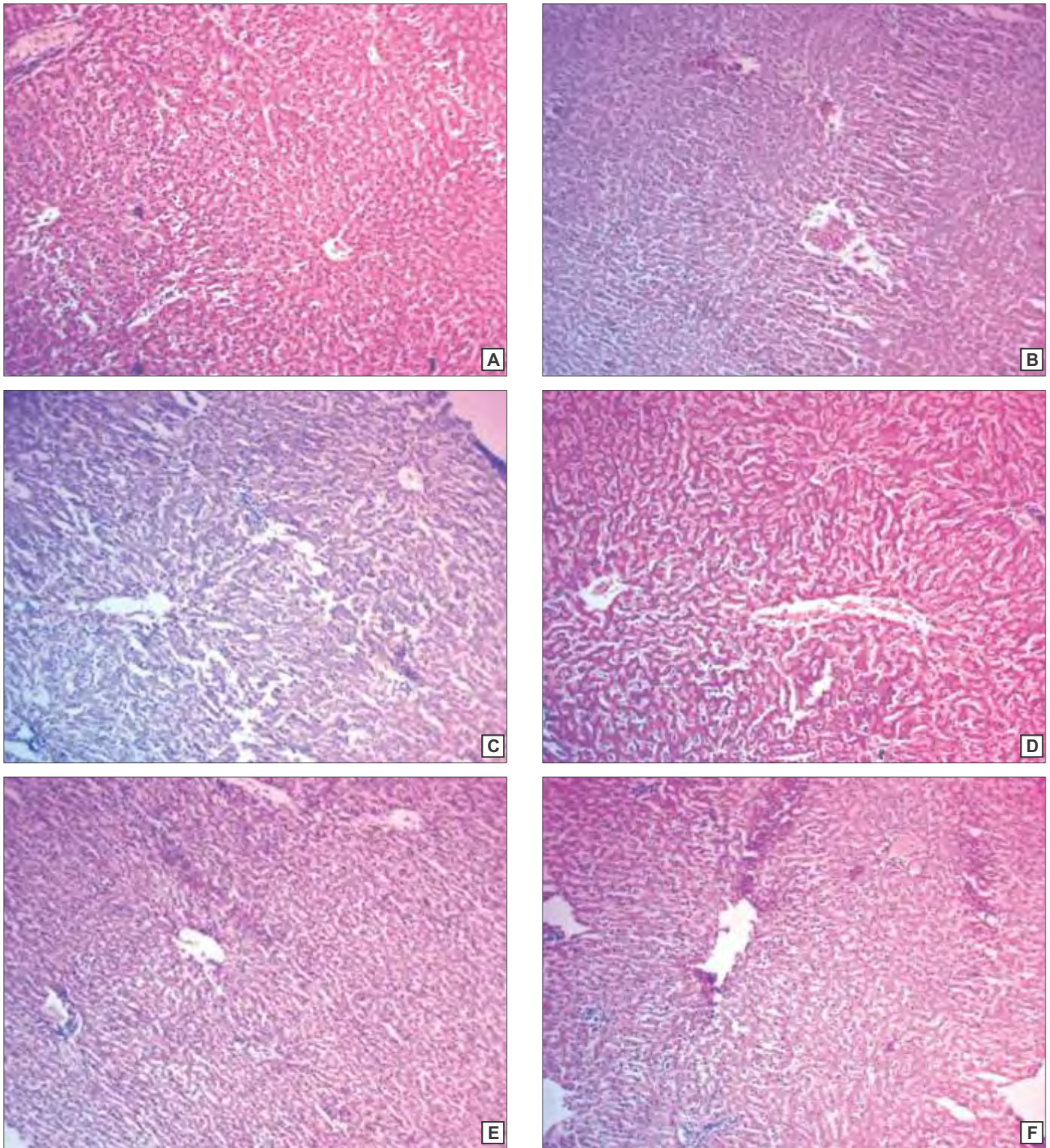


Fig. 2. Comparison of microphotographs of Liver tissue sections cleared with (A) Group 1- xylene, (B) Group 2- Coconut oil, (C) Group 3- Groundnut oil, (D) Group 4- Liquid paraffin, (E) Group 5- Mustard oil and (F) Group 6- Sesame oil showing infiltration of leukocytes and mild degenerative changes. H & E (100x)

that there was no significant difference in the quality of staining and tissue architecture of coconut oil and groundnut oil treated tissues at 60° C for 30 minutes as compared to xylene. They also reported that the translucency, rigidity, shrinkages and section cutting of coconut oil and groundnut

oil were enhanced while compared with Xylene.

However, Rasmussen *et al.* (1992) used a mixture of coconut oil and olive oil (at 50° C) as a clearing agent and noted an incomplete impregnation, leading to problems in cutting sections, and therefore concluded the mixture was

**Table 2. Mean score of Quality of H & E stained sections cleared with natural alternatives at higher temperature**

Groups	Reagents	Nuclear staining (Mean±SE)	Cytoplasmic staining (Mean±SE)	Clarity of staining (Mean±SE)	Overall quality of staining at higher temperature (Mean±SE)
Group 1	Xylene	1.67±0.33 <sup>a</sup>	1.67±0.33 <sup>a</sup>	1.49±0.25 <sup>b</sup>	1.61±0.31 <sup>a</sup>
Group 2	Coconut oil	1.21±0.24 <sup>a</sup>	1.16±0.09 <sup>a</sup>	1.05±0.05 <sup>ab</sup>	1.1444±0.11 <sup>a</sup>
Group 3	Groundnut oil	1.72±0.14 <sup>a</sup>	1.16±0.09 <sup>a</sup>	1.22±0.22 <sup>ab</sup>	1.3689±0.15 <sup>a</sup>
Group 4	Liquid paraffin	1.50±0.28 <sup>a</sup>	1.16±0.09 <sup>a</sup>	1.05±0.05 <sup>ab</sup>	1.2389±0.13 <sup>a</sup>
Group 5	Mustard oil	1.61±0.20 <sup>a</sup>	1.22±0.14 <sup>a</sup>	1.10±0.05 <sup>ab</sup>	1.3122±0.10 <sup>a</sup>
Group 6	Sesame oil	1.44±0.29 <sup>a</sup>	1.33±0.25 <sup>a</sup>	1.00±0.00 <sup>a</sup>	1.2578±0.18 <sup>a</sup>

Means with unlike superscript in each column show significant differences at P<0.05

ineffective. In contrast to their observation, this study found coconut oil to be as effective as xylene without interfering with further impregnation and ease of sectioning. It is possible that this difference occurred because olive oil present in the mixture preparation interacted with the properties of coconut oil and so adversely affected the whole process.

Moreover, Taneeru *et al.* (2013) evaluated the efficiency of sesame oil and limonene oil as substitutes for xylene in tissue processing. Their study concluded that sesame oil cleared tissues had all the staining quality (nuclear staining, cytoplasmic staining, clarity, uniformity and intensity of staining) which were adequate for diagnosis aspect. These findings were in accordance to the results of our study.

### CONCLUSION

It is concluded that all the natural alternatives used in the present study, could be used as clearing agents in histological preparations. As they are non-hazardous, have pleasant odor, are easier to find, and are less expensive, as well as maintain good cell architecture and good staining quality so they can be better alternatives to xylene in tissue processing.

### REFERENCES

- Bordoloi, B. (2018). Xylene Its Health Hazards and Biocompatible Substitutes. *World J. Pharm. Res.* **7**(15): 1017-1027.
- Chandraker, R., Rathod, V.C., Chandraker, N.K., Pundir, S., Dixit, S. and Desai, V. (2018). Comparison between Xylene and Coconut Oil in Tissue Processing. *Mod. Med. Lab. J.* **2**(1): 96-99.
- Dapson, J.C. and Dapson, R.W. (2005). Hazardous materials in the histopathology laboratory: regulations, risks, handling and

- disposal. (4<sup>th</sup> Edn.), Battle Creek, Anatech. pp. 65-78.
- Digala, P., Bollu, D., Karthicka, C., Vincy, S.J., Selvam, R. and Kandaswamy, S. (2013). Alternative to Reduce Occupational Hazards for Paramedical Staffs in Histopathology Department. *J. Pharm. Biol. Sci.* **12**(5): 05-12.
- Erickson, T., Amed, V., Leibach, S.J., Bushnik, P., Saxon, A., Hryhorczuk, D.O. and Knopse, W.H. (1994). Acute bone marrow toxicity and pancytopenia following exposure to lead chromate, xylene, and ethylbenzene in a degloving injury. *Am. J. Hematol.* **47**(4): 257-261.
- Kandyala, R., Raghavendra, S.P.C. and Rajasekharan, S.T. (2010). Xylene: An overview of its health hazards and preventive measures. *J. Oral Maxillofac. Pathol.* **14**(1): 1-5.
- Lillie, R.D. (1965). Histopathological techniques and practical histochemistry Mc Graw Hill Book Company, New York. pp. 176.
- Rahmawati, S., Janar Wulan, A., Utami, N. and Jaya, B.P.D. (2020). Preliminary study: The potency of vegetable cooking oil as alternative clearing agent for histological preparation. International confrence on agromedicine and medical sciences. pp. 01-08.
- Rasmussen, B.B., Hjort, K.N., Mellerup, I., Sether, G. and Christensen, N. (1992). Vegetable oils instead of xylene in tissue processing. *J. Pathol. Micro. Immunol.* **100**(7 12): 827-831.
- Saravanakumar, P., Bharanidharan, R., Ramadoss, R. and Kumar, A.R. (2019). Efficacy of "groundnut oil" and "coconut oil" as a substitute for "xylene" in clearing tissues samples—A comparative study. *SRMJ. Res. Dent. Sci.* **10**(4): 194-196.
- Sermadi, W., Prabhu, S., Acharya, S. and Javali, S.B. (2014). Comparing the efficacy of coconut oil and xylene as a clearing agent in the histopathology laboratory. *J. Oral Maxillofac. Pathol.* **18**(4): 49-53.
- Taneeru, S., Guttikonda, V.R., Vanajakshi, C.N. and Korlepara, R. (2013). Xylene free method for tissue processing: A pilot study. *Health Sci. J.* **2**: JS004.