

## SURGICAL MANAGEMENT OF OBSTRUCTIVE UROLITHIASIS USING SILVER COATED FOLEY'S CATHETER AND LATEX COATED FOLEY'S CATHETER IN MALE BUFFALO CALVES

DISHANT SAINI<sup>1</sup>, DEEPAK KUMAR TIWARI, ASHOK KUMAR, NEERAJ ARORA, GAURAV KUMAR, SATBIR SHARMA<sup>1</sup> and SANDEEP KUMAR<sup>2</sup>

Department of Veterinary Surgery and Radiology, <sup>1</sup>Department of Veterinary Clinical Complex,

<sup>2</sup>Department of Veterinary Physiology and Biochemistry, College of Veterinary Sciences, Lala Lajpat Rai University of Veterinary and Animal Sciences, Hisar-125004, India

Received: 20.08.2022; Accepted: 20.10.2022

### ABSTRACT

The objective of the present study was to compare the efficacy of latex Foley's catheter with silver coated Foley's catheter in male buffalo calves for surgical management of obstructive urolithiasis. The present study was conducted on twelve male buffalo calves presented with the history of urinary incontinence, straining during urination and bilateral distension of abdomen. The calves were divided into two groups having six animals in each on the basis of type of catheter used. Hematobiochemical examination divulged increase in serum creatinine, blood urea nitrogen and total leukocyte count. Ultrasonography of kidney and urinary bladder revealed divulged hydronephrosis and rupture of bladder in two calves (16%). Tube cystostomy was done using silver (group II) and latex (group I) coated Foley's catheter. The clinical outcome was uneventful in all the calves with less post-operative complications in group-II.

**Keywords:** Obstruction, Silver, Tube cystostomy, Ultrasonography, Urinary bladder

**How to cite:** Saini, D., Tiwari, D.K., Kumar, A., Arora, N., Kumar, G., Sharma, S. and Kumar, S. (2023). Surgical management of obstructive urolithiasis using silver coated foley's catheter and latex coated foley's catheter in male buffalo calves. *The Haryana Veterinarian* 62(1): 81-85.

Obstructive urolithiasis (OU) is the formation of calculi in the urinary tract with subsequent urinary blockade by uroliths (Radostits *et al.*, 2000). The condition is diagnosed with history of anuria coupled with other clinical manifestations, urinalysis and abdominocentesis. Ultrasonography can be used as a diagnostic aid to look for Urinary bladder rupture in bovine calves (Magda, 2006). Obstructive urolithiasis in calves need surgical intervention (House *et al.*, 1996). Tube cystostomy with latex Foley's catheter (Williams and White, 1991) used to bypass the urethra and help in making the normal flow of urine from the bladder, in conjugation with supportive treatments are reported for the management of urethral obstruction in cattle. The advantages reported for tube cystostomy are; less occurrence, preservation of reproductive function of the animal, an opportunity for the removal of cystic calculi and simplicity of the technique (Williams and White, 1991). Silver impregnated catheters with hydrogel coating have broad spectrum antiseptic activity against both bacteria and fungi without inducing resistance (Donlan, 2001). Silver's mechanism of action involves the release of ions that cause oxidative damage to a bacteria's cellular DNA and disruption of the cell's membrane (Duran *et al.*, 2007) and thus causing reduction in the rate of catheter associated urinary tract infections (Rupp *et al.*, 2004) as compare to latex coated Foley's catheter. So, the presented study was for comparative

evaluation of latex Foley's catheter with silver coated Foley's catheter in surgical management of obstructive urolithiasis in male buffalo calves.

### MATERIALS AND METHODS

The present study was conducted on twelve clinical cases of male buffalo calves brought to Teaching Veterinary Hospital, Hisar, Haryana with the history of straining during urination and abdominal distension. The calves were randomly divided into two groups comprising of six in each group; Group I: calves treated with tube cystostomy using Latex Foley's catheter and Group II: silver coated Foley's catheter.

**History and Clinical examination:** A complete history regarding the age of the male buffalo calf, urinary incontinence, abdominal distention, difficulty in micturition, duration of illness, early signs of the disease, previous treatment, if any, were recorded. The calves were subjected to thorough clinical examination which included general body condition (fair/dull and depressed/recumbent), rectal temperature (°F), heart rate (beats/min), respiratory rate (breaths/min) at 0<sup>th</sup>, 7<sup>th</sup>, 14<sup>th</sup> and 28<sup>th</sup> day, post operatively.

**Hematology and Blood biochemistry:** Five millilitres and four millilitres of blood was collected from jugular vein in ethylenediaminetetra acetic acid (EDTA) and serum vials, respectively using aseptic syringes in sterile EDTA vials on 0<sup>th</sup>, 7<sup>th</sup>, 14<sup>th</sup> and 28<sup>th</sup> day for the analysis of

\*Corresponding author: dishantag95@gmail.com

various haematology parameters (Total leucocyte count and differential leucocyte count) and biochemistry (blood urea nitrogen and creatinine) using semi-automatic haematological analyser and automatic serum analyser.

**Ultrasonography:** Trans-cutaneous ultrasonographic examination of the urinary bladder was done in a dark and quiet room using 7.5 MHz sector probe of a real time; B-mode Siemens Acuson S2000 ultrasound machine after shaving and cleaning of Vento-lateral abdomen towards inguinal region. The ultrasound gel was used for coupling of the transducer with skin. None of the calves were given sedation or tranquillization for ultrasonography. Ultrasonography was done to confirm the status of the urinary bladder and kidney and to locate the urinary calculi, if possible.

**Surgical Management (Tube cystostomy):** Preoperatively, fluid and supportive therapy was given to the calves with severe dehydration and/or uremia as per the requirement. After stabilization, the calves were prepared for surgery. The calves were sedated with inj. xylazine hydrochloride @ 0.01 mg per kg b.wt. intravenously and local infiltration analgesia using 2% lignocaine hydrochloride in the left paramedian area starting from the rudimentary teats. A 2-3 cm stab incision was given to expose the muscles and fascia (Figs. 5 & 6). The condition of the bladder as intact or ruptured was assessed using index and middle finger. For intact bladder a 2 mm blunt pin was used to insert the catheter by applying moderate force on the dorsal surface of bladder. If the bladder was ruptured, then it was retracted with Ally's forceps and cystorraphy was performed after debridement of edges and flushing of uroliths with simple continuous suture pattern (Fig. 7). A subcutaneous tunnel was created by passing a straight artery forceps just proximal to laparocystotomy incision after giving a nick over the skin with a BP blade before introduction of Foley's catheter into the bladder (Fig. 8). The jaws of the forceps inside the tunnel were opened to grasp the free end of the catheter to pull it out through the subcutaneously, where it was anchored with the skin in all the calves. Foley's catheter was introduced inside the bladder by making a stab incision away from the site of rupture (Fig. 9) and the bulb of the catheter was distended with 30 ml of normal saline. The Foley's catheter was sutured at multiple sites on the ventral abdomen with the help of simple interrupted sutures. Group-I animals were subjected to tube cystostomy using Latex Foley's catheter, while Group-II animals were subjected to tube cystostomy using silver coated Foley's catheter. The skin and muscles were closed routinely (Figs. 10, 11). The latex Foley's catheter (Fig. 12) and silver coated Foley's catheter (Fig. 13) were kept in-situ until free flow of urine occurs from the urethra.

Broad-spectrum antibiotics cefotaxime @ 5 mg per kg b.wt. along with amikacin @ 2 mg per kg b.wt. and anti-inflammatory/analgesics meloxicam @ 0.5 mg per kg b.wt. were given for five days post-operatively. Powder ammonium chloride @ 0.5 mg per kg b.wt. was given orally for acidification of urine. Flushing of catheter with betadine solution daily was carried out till catheter was removed to prevent post-operative complications. Post-operatively, subcutaneous injection of antibiotics gentamicin was given along with steroid prednisolone to increase the vascularity of the area and increase the speed of healing in urine scalding due to uroperitoneum.

## RESULTS AND DISCUSSION

The prominent clinical signs in Group-I calves were restlessness, straining for urination (n=6; 100%), followed by anorexia, depression (n=4; 66.6%), swelling on the ventral abdomen (n=3; 50%), bilateral abdominal distension, kicking at belly, mild bloat, recumbency (n=2; 33.3%) and tendency of rectal prolapse (n=1; 16.6%). However, in Group-II calves exhibited clinical signs that included anorexia (n=6; 100%), kicking at belly, recumbency (n=2; 33.3%), followed by concretion encrustation at preputial orifice (n=1; 16.6%), mild bloat, restlessness (n=1; 16.6%), tendency of rectal prolapse (n=1; 16.6%), swelling on ventral abdomen (n=1; 16.6%). The early sign of obstructive urolithiasis are caused by the urethral pain and once the urinary bladder or urethra ruptures, these symptoms disappear and those of uremia supervene (Radostits *et al.*, 2000 and Villar *et al.*, 2003). The high degree of abdominal distension makes the calf reluctant to move probably because of the discomfort caused by turbulence of excessive peritoneal fluid. Blood hematology showed an increase in total leucocyte count and a significant ( $p<0.05$ ) increase in the neutrophils from day 0 to day 28<sup>th</sup> in Group I as compared to Group II. The return of TLC and neutrophils values towards normalcy could be attributed to the removal of inciting causes like stress, pain and infection (Lederer *et al.*, 2014).

The blood urea nitrogen (BUN) was recorded to be significantly ( $p<0.05$ ) low from day 0 to day 7 but later increased upto day 28<sup>th</sup> in Group I while in Group II, a significant decrease ( $p<0.05$ ) from day 0 to day 28<sup>th</sup> was recorded. The BUN were higher in the calves of both groups at the day of presentation which could be due to onset of acute renal failure manifested by decreased glomerular filtration rate as a result of back pressure on the kidneys and absorption of urea from the urine present in the bladder in the intact urinary bladder cases of urethral obstruction and absorption of urea from peritoneal cavity in the ruptured urinary bladder cases of complete obstructive urolithiasis (Sharma *et al.*, 2006). The decrease



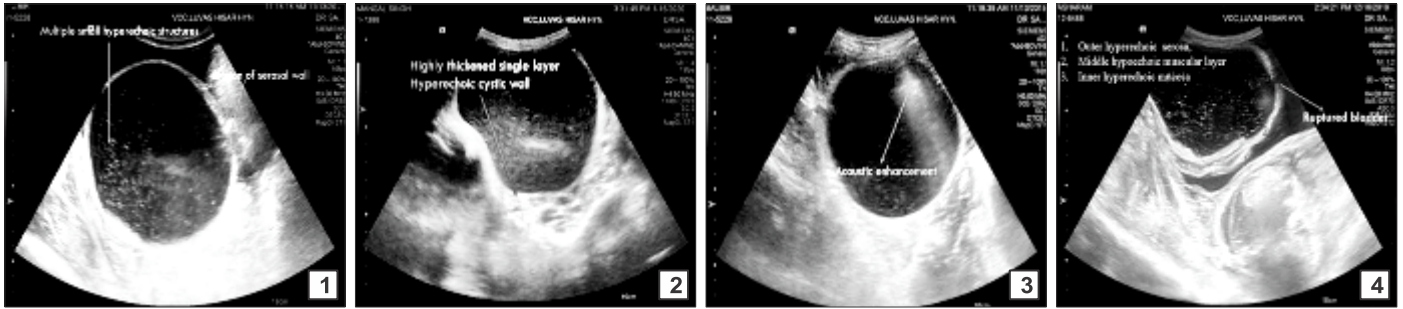
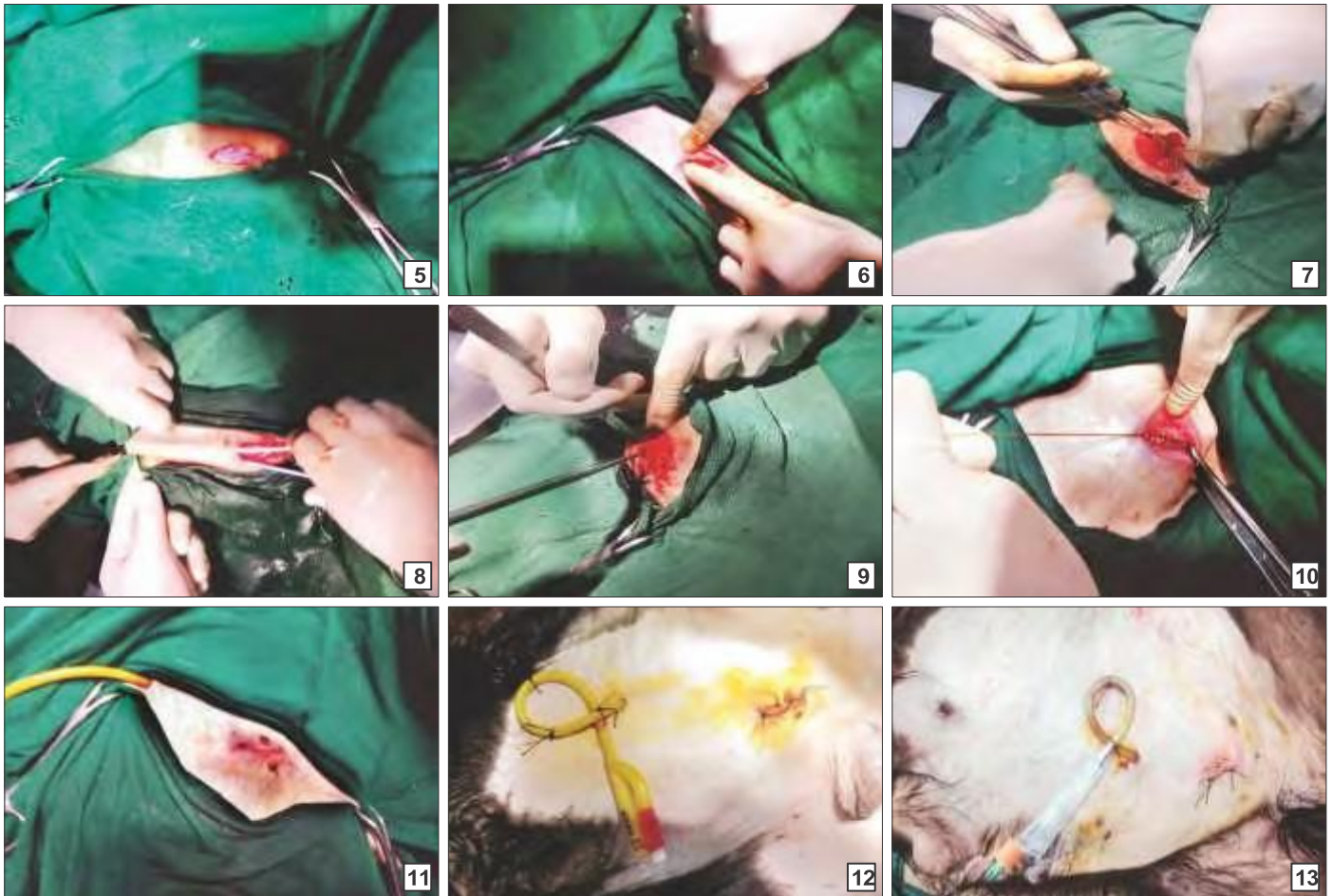


Fig. 1-4. (1) Transabdominal cystosonogram showing serosal erosion with bulging of muscular and mucosal layers outside the bladder's silhouette and with intraluminal multiple hyperechoic foci (urocystoliths). (2) Transabdominal cystosonogram showing highly thickened hyperechoic single layered cystic wall (cystitis) with hyperechoic intraluminal materials without any acoustic shadow. (3) Transabdominal cystosonogram showing single hyperechoic mass with appreciable acoustic enhancement. (4) Transabdominal cystosonogram showing pear shaped bladder with three layered cystic walls; (1. outer hyperechoic serosal layer, 2. middle hypoechoic muscular layer, and 3. inner hyperechoic mucosal layer).



Figs. 5-13. (5) Incision on the skin; (6) Refract the Muscles; (7) Photograph showing the exteriorization of ruptured bladder for cystorrhaphy; (8) Subcutaneous Tunnel making for passing the Foley's catheter; (9) Foley's catheter was introduced inside the bladder by stab incision from the site of rupture; (10) Muscle suturing with lock and stitch suture pattern; (11) Intradermal suturing of skin; (12) Latex Foley's Catheter fixation with simple interrupted sutures; (13) Silver coated Foley's catheter fixation with simple interrupted sutures

in the BUN post-operatively has also been reported but faster return of BUN level towards normalcy in calves operated with silver coated Foley's catheter may be due to the cessation of CAUTI's by silver alloy as compared to latex coated Foley's catheter (Magnusson *et al.*, 2019). There was significant ( $p < 0.05$ ) increase in serum creatinine from day 0 to day 28 in Group I while decrease in Group II. The absorption of creatinine from the

accumulated urine in the body and increased production of creatinine precursor due to muscle catabolism (Finco, 1970), and decreased excretion due to decreased glomerular filtration rate (GFR) (Sharma *et al.*, 2006), might have contributed to the increase in creatinine at presentation. The significant ( $P < 0.05$ ) decrease in the base value of calves of Group II as compared to other Group I at the same corresponding interval could be due to the

indirect effect of silver on preventing catheter associated secondary bacterial infections which indirectly help the kidney to retain its normal GFR (Ogilvie *et al.*, 2018). Post-operatively, creatinine values increased steadily at different intervals from the base values in group I, due to inability of latex catheter in preventing post-operative infections.

The trans-abdominal ultrasonographic examination revealed the different shapes of urinary bladder with hyperechoic cystic wall and anechoic lumen (urine). Urinary bladder was oval shaped in 6 cases (Fig. 1). In extremely distended cases (n=4), the cystic wall appeared as a single hyperechoic layered (Fig. 2), while in 2 ruptured bladders, it was found in the abdominal cavity. Erosion of serosal layer of cystic wall at ventral part of the urinary bladder, accompanied with cystitis and concomitant with uoperitoneum was observed only in one case (Fig. 1).

The rupture of urinary bladder was appreciated with connection between peritoneal cavity and cystic lumen along with disruption in bladder wall orientation. The fluid obtained from the abdominal cavities of these cases ranged from 5 to 19 litres. The urinary bladder rupture is suspected fit is not visible on ultrasound examination especially in large cattle (Braun *et al.*, 2006). The uoperitoneum is often associated with pinpoint leaks in small ruminants, rather than overt bladder rupture (Ewoldt *et al.*, 2006). Urocystoliths were ultrasonographically diagnosed in all the 12 cases of buffalo calves suffering from complete retention of urine with (100%) accuracy but with different patterns, depending upon the number and size of the calculi. In 8 calves (66.6%), on ultrasonography, multiple small hyperechoic structures of varying size were seen swirling in the anechoic fluid (urine) without any acoustic shadows (Fig. 2). The urinary stones are hyperechoic structure with acoustic shadow on USG (Saini and Singh, 2002). However, during this study acoustic shadow accompanying a single calculus or mass of calculi in a single unit was seen in urinary bladder in all the twelve cases. Cystic calculi appeared as curvilinear hyperechoic interfaces blocking much of the sound beam at the first fluid-calculus interface and hence casting a distal acoustic shadow while several calculi accumulate together with combined interface creating a hyperechoic undulant line. In four (33.3%) cases, mass of calculi along with denuded mucosal tissues and blood clots were found freely floating in the urinary bladders with hyper-echogenicity and acoustic enhancement (Fig. 3). Cystitis was characterized by highly thickened and single layered hyperechoic cystic wall and with or without the hyperechoic material within the lumen and/or attached to the mucosal layer but without any acoustic shadow in one case. The cystic wall

measurements ranged from 0.5 to 0.9 mm in cases of cystitis. Likewise, urinary bladder distension ranged from 10 to 24 cm in diameter (Halland *et al.*, 2002). Ultrasound examination is helpful in measuring the thickness of the urinary bladder and urethral wall in cases of cystitis and urethritis (Magda, 2006). Tube cystostomy using indwelling catheter is effective technique in obstructive urolithiasis cases in male buffalo calves being simple, of short duration and results in restoration of full urethral patency (Fortier *et al.*, 2004). The catheter loss was observed in 4 (33.3%) calves after 28 days, while in one calf of Group I, the catheter was retrieved into the abdominal cavity after 22 days. The dislodgement of Foleys catheter is common in goats (Fortier *et al.*, 2004).

The catheter got blocked in three cases in Group I and one of Group II. The blockade was removed after flushing these catheters with normal saline solution. The blockade might have occurred by urinary sludge, blood clots, sandy material left in urinary bladder, and mucosal shreds. Failure to remove the blockade in the urethral catheter by flushing could be due to its kinking (Van Metre, 2004). The occurrence of blockage was more in Group I than Group II because of the presence of hydrogel coating on the catheter which prevents the aggregation of sandy material and blood clots on it therefore, preventing secondary bacterial infection.

## CONCLUSION

The tube cystostomy done using silver coated indwelling Foley's catheter is more effective in minimizing the post-operative urinary infection, reduced abdominal adhesion and muscle fibrosis, reducing chances of catheter blockage and facilitating free drainage of urine thereby normalizing BUN and creatinine levels as compared to latex Foley's catheter.

## REFERENCES

- Braun, U., Nuss, K., Wapf, P. and Lischer, C. (2006). Clinical and ultrasonographic findings in five cows with a ruptured urachal remnant. *Vet. Rec.* **159**: 780-782.
- Donlan, R.M. (2001). Biofilms and device-associated infections. *Emerg. Infect. Dis.* **7**(2): 277.
- Duran, N., Marcato, P.D., De Souza, G.I.H., Alves, O.L. and Esposito, E. (2007). Antibacterial effect of silver nanoparticles produced by fungal process on textile fabrics and their effluent treatment. *J. Biomed. Nanotech.* **13**: 203-208.
- Ewoldt, J.M., Jones, M.L. and Miesner, M.D. (2006). Surgery of obstructive urolithiasis in ruminants. *Vet. Clin. North Am. Food Anim. Pract.* **24**(3): 455-65.
- Finco, D.R., Rosin, E. and Jhonson, K.H. (1970). Canine urolithiasis: A review of 133 clinical and 23 necropsy cases. *J. Am. Vet. Med. Assoc.* **157**(9): 1225-1228.
- Fortier, L.A., Gregg, A.J., Erb, H.N. and Fubini, S.C. (2004). Caprine obstructive urolithiasis: Requirement for 2<sup>nd</sup> surgical intervention

- and mortality after percutaneous tube cystotomy, surgical tube cystotomy or urinary bladder marsupialisation. *Vet. Surg.* **33**(6): 661-667.
- Halland, S.K, House, J.K. and George, L.W. (2002). Urethroscopy and laser lithotripsy for the diagnosis and treatment of obstructive urolithiasis in goats and pot-bellied pigs. *J. Amer. Vet. Med. Assoc.* **220**(12): 1831-1834.
- House, J.K., Smith, B.P. and George, L.W. (1996). Obstructive urolithiasis in ruminants: Medical treatment and urethral surgery. *Compend. Contin. Educ. Vet.* **18**: 317-328.
- Lederer, J.W., Jarvis, W.R., Thomas, L. and Ritter, J. (2014). Multicenter cohort study to assess the impact of a silver-alloy and hydrogel-coated urinary catheter on symptomatic catheter-associated urinary tract infections. *J. Wound Ostom. Continen Nurs.* **41**(5): 473.
- Magda, A. (2006). Diagnosis of obstructive urolithiasis in cattle and buffalo by using ultrasonography. *Online J. Vet. Res.* **10**: 26-30.
- Magnusson, B., Kai-Larsen, Y., Granlund, P., (2019). Long-term use of noble metal alloy coated urinary catheters reduces recurrent CAUTI and decreases proinflammatory markers. *Ther. Adv. Urol.* **11**: 1756287219854915.
- Ogilvie, A.T., Brisson, B.A., Gow, W.R., Wainberg, S., Singh, A. and Weese, J.S. (2018). Effects of the use of silver-coated urinary catheters on the incidence of catheter-associated bacteriuria and urinary tract infection in dogs. *J. Am. Vet. Med. Assoc.* **253**(10): 1289-1293.
- Radostitis, O.M., Blood, D.C., Gay, C., and Hinchcliff, K.W. (2000). *Veterinary Medicine: A Textbook of the Diseases of Cattle, Sheep, Pigs Goats and Horses*, (10<sup>th</sup> Edn.), London: Bailliere Tindall, pp. 493-98.
- Rupp M.E., Fitzgerald, T., Marion, N., Helget, V., Puumala, S., Anderson, J.R. and Fey, P.D. (2004). Effect of silver-coated urinary catheters efficacy, cost-effectiveness, and antimicrobial resistance. Department of Internal Medicine, University of Nebraska medical centre. p. 272.
- Sharma, P.D., Singh, K., Singh, J. and Kumar, A. (2006). Bacteriological, biochemical and histopathological studies in uroperitoneum in buffalo calves (*Bubalus bubalis*). *Indian J. Anim. Sci.* **76**(2): 124-126.
- Van Metre, D. (2004). Urolithiasis. *Farm Animal Surgery*, Susan L. Fubini and Norm G. Ducharme (Edts), W.B. Saunders, New York, pp. 534-547.
- Villar, D., Larson, D.J., Janke, B.H., Yaeger, M.J., Carson, T.L. and Blaylock, R. (2003). Case report - obstructive urolithiasis in a feedlot steer. *Bovine Pract.* **37**(1): 74-77.
- Williams, J.M. and White, R.A.S. (1991). Tube cystotomy in dog and cat. *J. Small Anim. Pract.* **32**(12): 598-602.

## CONTRIBUTORS MAY NOTE

- Research/Clinical articles are invited for next issue from the Scientists/Veterinarians engaged in Veterinary Profession.
- Please follow strictly the format of 'The Haryana Veterinarian' for manuscript writing/submission.
- Please pay processing fee of Rs. 1000/- online in the account of Dean, College of Veterinary Sciences, along with each article.
- After revision, please return the revised manuscript and rebuttal at the earliest.
- Please mention your article reference number in all correspondence for a quick response.
- We solicit your co-operation.
- All correspondence should be addressed to 'The Editor', Haryana Veterinarian, Department of Veterinary Parasitology, College of Veterinary Sciences, LUVAS, Hisar-125004.

Editors