

**ENLARGED CLITORIS IN A BEETAL GOAT VIS-A-VIS PSEUDO HERMAPHRODITISM**

ANKIT AHUJA\*, TYSON, AMIT SHARMA, PANKAJ SOOD and VASU SHARMA

Dr. G.C. Negi College of Veterinary and Animal Sciences,

Chaudhary Sarwan Kumar Himachal Pradesh Krishi Vishvavidyalaya, Palampur-176 062 (HP), India

Received: 17.07.2022; Accepted: 18.10.2022

**SUMMARY**

Present article dictates about the anatomical description of two months old horned female Beetal kid which was presented for an enlargement of clitoris associated with profound male libido and characteristic behavioral signs.

**Keywords:** Goat, Enlarged clitoris, Pseudo-hermaphrodite

**How to cite:** Ahuja, A., Tyson, Sharma, A., Sood, P. and Sharma, V. (2023). Enlarged clitoris in a beetal goat vis-a-vis pseudo hermaphroditism. *The Haryana Veterinarian* 62(1): 170-171.

Intersex animal is the one which fails to gratify the criterion for sex determination videlicet genetic configuration, gonadal histology, genital tract morphology and appearance of external genitalia (Noden and DeLahunta, 1985). According to Hafez and Hafez (2000) hermaphroditism can be classified into three categories: i) true hermaphrodites: having both male and female gonadal tissues with external genitalia ranging from normal male to normal female, ii) pseudo hermaphrodites: refers to gonadal dysgenesis having gonads of either sex and external genitalia of other sex and iii) free martin: which can be considered as a form of intersexuality due to anomalous genetic configuration. Variation between phenotypic and gonadal sex is distinctive for pseudo hermaphrodite. It can be further classified as either male or female pseudo hermaphrodite on the basis of the existing gonadal tissue (Kennedy and Miller, 1993). Male pseudo hermaphrodite have testes with external genitalia resembling an assortment of both sexes or either female. Female pseudo hermaphrodite possess ovaries but phenotypically have masculine appearance with or without enlarge clitoris (Weng *et al.*, 2005). Preliminary suspicion is often made by investigating external genitalia whereas laparoscopic examination can be done to achieve final diagnosis (Hafez *et al.*, 2005). The underlying mechanisms of pseudo hermaphroditism are perhaps beyond the realm of embryology and endocrinology however can be determined at gene level. The present paper puts forth a novel report of genital anomaly in Beetal goat together with its anatomical and ultrasonographic findings.

Two months old horned apparently female Beetal kid weighing 8.5 kg was presented to Advanced Veterinary Multispecialty Centre, Dr. G.C. Negi College of Veterinary and Animal Sciences, Palampur, India. The animal was presented for an abnormal enlargement of the clitoris,

which magnifies in size since birth. She was born as singlet to the dam. Although there was no history of dysuria yet the kid exhibited profound male libido with characteristic behavioral signs. These sign includes frequent mounting, sniffing of vulva and nudging. Physically, the kid was rather masculine in appearance. The kid was phenotypically horned female with normally located non-lactating infantile udder and vulva. Ano-genital distance was comparatively smaller measuring 1.8 cm with morphologically enlarge clitoris measuring 2.2 cm in length (Fig. 1). Halfway to the ano-genital length displayed atypical bilateral compression from lateral sides. Clitoris possesses identifiable glans with raphe glandis like groove in the center of the free end of the glans, covered laterally with prepuce like folds. The enlarge clitoris, upon examination protruded out partially from the fossa clitoridis. To avoid complete protrusion and occupy the minimum presented space, the clitoris was kinked and folded like bandaneon fashion. Also, if the clitoris would have been straightened, it would be several centimeters long. The kid had a stenosed slit like vaginal opening with relatively shorter vaginal length of 2.5 cm. Glans like appendage on clitoris had no lumen and urine was passing through urethral orifice at the vestibule-vaginal junction, situated at its usual place. Trans-abdominal ultrasonography was fruitless in depicting gonadal structures. Trans-rectal ultrasonography (TRUS) in consort with AI sheath insertion pervaginum depicted hyper echoic band in the cranial vagina (Fig. 2). Beyond this hyper echoic band the vagina bluntly closes in cul-de-sac fashion. The animal being young with underdeveloped reproductive edifice limits the optimum usage of TRUS in depicting gonads. Even though TRUS was ineffectual in revealing gonadal tissue however vaginal canal ending into a blind pouch created suspicion for ascertaining the actual gonadal sex of the animal.

Scarce reports, nearly a dozen, pertaining to intersex

\*Corresponding author: ankit.ahuja1947@gmail.com

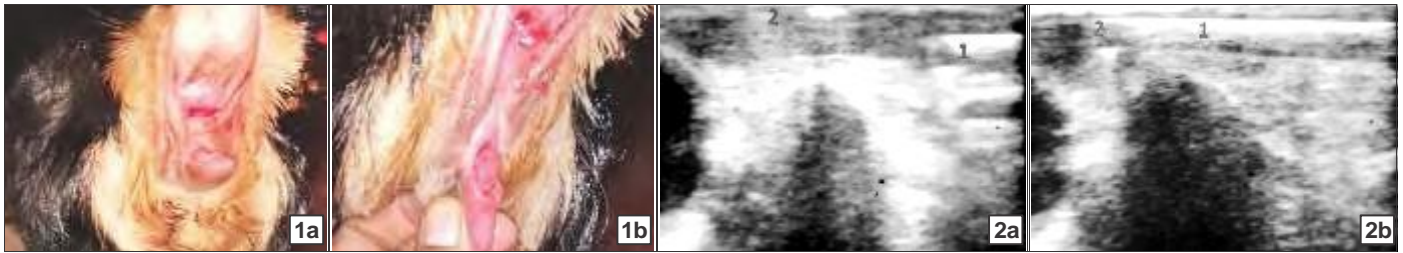


Fig. 1. a) Enlarged clitoris b) Protruded glans like appendage Fig. 2. a) TRUS depicting per vaginum AI sheath (1) and hyperechoic band covered laterally with prepuce like folds (Note the raphe glandis like groove in the center of the free end of glans)

b) blind pouching in cranial vagina (2) with AI sheath (1) at the farthest point

/hermaphroditism/genital anomaly in goats were found during author's read out of literature. Minimum age amongst the cases reported in the literature was three months (Hafez *et al.*, 2005) whereas in the present case the age of kid was two months only. Majority of them were presented for amplified male libido with masculine appearance and male like character videlicet male odor and chin beard (Hafez *et al.*, 2005). Precisely, in the cases of male pseudohermaphrodite, enlarged clitoris (maximum 3 cm long; Ottaway and Arnold, 1945) in conjunction with small vulva and slit like vulvar opening is associated with presence of testicular tissue in the abdomen. Corroborating to the findings of present case, we also depicted hypertrophied clitoris with reasonably shorter vagina ending in blind cul-de-sac fashion with hyper echoic band in cranial vagina as evinced by passing AI sheath per vaginum during TRUS. Presence of underdeveloped gonads, majorly testes, intra-abdominally in male pseudohermaphrodite is a promising feature. Although they lack germinal epithelium thus are agametogenic in nature but a single layer of Sertoli cells might be present along with some interstitial tissue mainly Leydig cells (Ozsoy and Kutsal, 2009). Presence or absence of accessories of genital system i.e. seminal vesicles, prostate gland, and bulbourethral gland, is by far linked with the extent of hermaphroditism.

In the wake of available literature and author's understanding regarding the condition, the kid can be regarded as hermaphrodite. In the present article, we put forth a comprehensive view of anatomical aspects of hermaphrodite in youngest of all goat kid reported.

## REFERENCES

- Hafez, E.S.E. and Hafez, B. (2000). Genetics of reproductive failure, in: Hafez, B., Hafez, E.S.E. (Eds.), Reproduction in farm animals, Lippincott Williams and Wilkins. Philadelphia. pp. 315-316.
- Hafez, S.A., Huckle, W.R. and Caceci, T. (2005). Anatomical, histological and genetic investigations of a sexually anomalous goat. *Vet. Rec.* **157**: 513-516.
- Kennedy, P.C. and Miller, R.B. (1993). The female genital system. In: Jubb, K.V.F., Kennedy, P.C., Palmer, N. (Eds.), Pathology of Domestic animals (4<sup>th</sup> Edn.), Academic Press, San Diego, pp. 349-357.
- Noden, D.M. and De Lahunta, A. (1985). Cytogenetics and sex determination. In: The embryology of domestic animals, Stamathis, G. (Edt.) Williams and Wilkins, Baltimore, pp. 343-356.
- Ottaway, C.W. and Arnold, R.H. (1945). A case of intersexuality (hermaphroditism) in a horned goat. *Vet. J.* **101**(7): 151-153.
- Ozsoy, S.Y. and Kutsal, O. (2009). Male Pseudohermaphroditism in a Lamb. *Vet. Fakultesi Dergisi.* **20**(1): 65-67.
- Weng, Q., Murase, T., Asano, M. and Tsubota, T. (2005). Male pseudohermaphroditism in a Raccoon dog (*Nyctereutes procynoides*). *J. Vet. Med. Sci.* **67**: 603-605.