

ACUTE ORAL TOXICITY STUDY OF QUINALPHOS IN MALE SWISS ALBINO MICE

PREETI SINGH, VINOD KUMAR, PREETI BAGRI*, DEEPIKA LATHER¹ and VINAY KANT

Department of Veterinary Pharmacology and Toxicology,

¹Department of Veterinary Pathology, College of Veterinary Sciences,
Lala Lajpat Rai University of Veterinary and Animal Sciences, Hisar-125004, India

Received: 05.09.2022; Accepted: 09.11.2022

ABSTRACT

The present study was conducted to evaluate the acute toxic effect of quinalphos (QNP) on relative organ weight, hematological parameters and histological changes in liver and kidney of male Swiss albino mice. Maximum tolerated dose (MTD) was determined and effect of single oral dose of MTD was observed in different groups of mice after the peak effect, 24 h and 14 days. The changes in relative body weight, relative organ weight of vital organ (heart, liver, kidneys, spleen, thymus, testis and epididymis), hematological parameter (Hb, TEC, TLC and DLC) and histopathology of liver and kidney were observed. The MTD of QNP which was determined first time in male Swiss albino mice was found to be 15 mg/kg b.wt. The study concluded that single dose of MTD of QNP produced acute toxic effects (14 days) as revealed by alterations in relative thymus weight, hematological parameters (Hb, TLC, TEC, differential lymphocyte and neutrophil count) and histopathological changes in liver and kidneys. Liver showed degenerative changes at 1 h 45 min, severe vascular changes after 24 h and mild vascular changes with few areas of focal hepatitis in parenchyma after 14 days. In kidney, mild glomerular congestion was present at 1 h 45 min, moderate vascular changes after 24 h and milder vascular, degenerative and necrotic changes in parenchyma after 14 days. Significant difference was found in differential lymphocyte count at peak effect group and in relative testis weight at 24 h group.

Keywords: Hematological parameters, Histopathology, Maximum tolerated dose, Quinalphos, Swiss albino mice

How to cite: Singh, P., Kumar, V., Bagri, P., Lather, D. and Kant, V. (2023). Acute oral toxicity study of quinalphos in male swiss albino mice. *The Haryana Veterinarian* 62(1): 133-137.

Pesticides are extensively used in agriculture for controlling pests in order to increase the crop yields. Roughly, on application of pesticides in the fields less than 0.1% of the pesticide, reaches the specific target organism while the rest 99.9% enters into the environment and affects the non-target organisms (Ramakrishnan *et al.*, 2010; Chitra *et al.*, 2013). Worldwide, organophosphate (OP) pesticides is likely to be the most important cause of death from self-poisoning, causing about 200,000 deaths each year. Quinalphos (QNP), being an organophosphate (OP) insecticide has wide applicability to control pests in farming due to its good penetrative properties. The animals may be directly or indirectly exposed to QNP. The long residual action of QNP in animals and aquatic organisms put it as a matter of concern (Muttappa *et al.*, 2014). The LD₅₀ of QNP is known but the maximum tolerated dose (MTD) has not been determined yet in mice. So, the present study was conducted to find MTD of QNP and to investigate the alteration in organ weight, hematological parameters and histological changes in liver and kidney of male Swiss albino mice on administration of single dose of MTD of QNP on acute exposure.

MATERIALS AND METHODS

Chemicals and experimental animals- Quinalphos (formulation VAZARA 25% EC) originally obtained from Bharat Crop Care, New Delhi, India was used in the present investigation. Male Swiss albino mice weighing

between 20-24 g were procured from Disease Free Small Animal House (DFS AH), Lala Lajpat Rai University of Veterinary and Animal Sciences (LUVAS), Hisar, Haryana. Mice were housed in polypropylene cages in group of 5 per cage under 12-12 h dark-light cycle with free access to freshly prepared feed and water. They were acclimatized for a period of one week in the Departmental Animal House. Animal house temperature varied between 22° C to 27° C throughout the study. The study was carried out after the approval from the Institutional Animal Ethics Committee (IAEC)(ApprovalNo.VCC/IAEC/1630-58dated26.07.2018).

Determination of Maximum tolerated dose (MTD)- Various doses of quinalphos were screened for determination of MTD in pilot dose range finding study following standard method (Bagri and Kumar, 2020). In this method, pilot dose range finding study was conducted in which an apparent LD₅₀ for technical grade QNP (55 mg/kg, oral) in male mice was considered. This study was conducted in small groups of mice (n= 2) using several doses including few lethal doses. These doses are presented in table 1. In each group of mice, single oral dose of QNP in distilled water (DW) was administered through a metal gavage needle.

Out of these doses, a maximum dose was selected which had produced clear sign of toxicity but not resulted in lethality i.e. MTD. The time of peak effect of QNP in mice was also determined based on the intensity of effects observed at different time interval after administration of doses. The MTD was verified in a larger group of animals

*Corresponding author: preetisuhag.vets@gmail.com

(n=10). Among these 10 mice, five mice were randomly selected and sacrificed after 24 h. The remaining five mice were kept for 14 days and observed daily to see delayed effect, if any. These mice were sacrificed on 15th day.

Single dose of QNP at MTD was administered orally in three treatment groups and observations were taken after 1 h 45 min (time of peak effect), 24 h and 14 days and results were compared with respective controls for the different parameters. The mice of 24 h and 14 days were same which were used for verification of MTD. The control group for 1 h 45 min and 24 h group was same. DW (1ml/100 g b.wt, oral) was administered to the control group mice.

Acute toxicity study: The acute toxicity study for testing of chemicals was performed as described by earlier workers (Bagri *et al.*, 2013). Mice were sacrificed under thiopentone anesthesia. Blood was collected through cardiac puncture in the heparinized test tubes. Hematological parameters *viz.* hemoglobin (Hb) total erythrocyte count (TEC), total leukocyte count (TLC) and differential leukocyte count (DLC) were estimated by standard method (Weiss and Wardrop, 2010). Necropsy was performed and organ weights of heart, liver, kidneys, spleen, thymus, testis and epididymis were recorded. The relative body weights and organ weights were expressed as g/100 g body weight of mice.

Small pieces of liver and kidney of mice from all groups were fixed in 10% buffered formalin, dehydrated in ascending alcohol grades and embedded in paraffin wax. Approximately 5 µm thick sections were prepared and stained with hematoxylin and eosin (H&E) for assessment of histopathological changes in liver and kidney under light microscopy. All these parameters were conducted in three treatment groups with their corresponding control groups as mentioned earlier.

Statistical analysis

Data were analyzed using Graph Pad Prism version 5.03. Results were expressed as mean±SEM with 'n' equal to number of animals. Unpaired Student's t-test was used for comparison between two groups. In all tests, p values less than 0.05 were considered statistically significant.

RESULTS AND DISCUSSION

Estimation of MTD

In this study, MTD of QNP was found to be 15 mg/kg b.wt. lower than LD50 (55 mg/kg). QNP after oral administration produces dose-dependent onset and severity of toxic symptoms in mice as shown in the table 1. The peak effect of mice was found to be at 1h 45 min.

Signs and symptoms of acute toxicity

Animals were observed at an interval of 15 min for

Table 1. Mortality of mice at various dose levels of quinalphos administered orally

Doses of QNP (mg/kg, b.wt. p.o.)	No. of mice died/ total mice
30	2/2
20	1/2
17	1/2
15	0/2
15	0/10
13	0/2
10	0/2

Table 2. Effect of oral exposure of mice to single MTD (15 mg/kg) of quinalphos on the body weight (g) at 1 h 45 min and 24 h post-treatment

Treatment (p.o.)	Body weight (g)		Body weight (g)	
	0 th day	1h 45 min	0 th day	24 h
Control (1ml/100g)	25.70 ± 0.70	25.70 ± 0.70	25.70 ± 0.70	25.80 ± 0.78
QNP (15 mg/kg, b.wt.)	24.40 ± 1.47	24.40 ± 1.47	24.70 ± 3.76	25.00 ± 3.69

Data are presented as mean ± SEM (n= 5 mice/group). The values were compared using unpaired Student's t-test.

3h, one-hour interval for 12 h, 24 h and daily for 14 days post-administration of MTD (15 mg/kg) in all the three groups for signs and symptoms of acute toxicity. Animals showed symptoms of toxicity till peak effect and after recovery no abnormal behavior was observed other than vocalization and aggressiveness in 1–2 mice on day 2 of 14 days post-administration.

Effect of QNP on body weight, relative body weight gain and relative organ weight

The effect on body weight and relative body weight gain and relative organ weight are given in table 2, 3, 4 and 5. No significant change was observed in body weight after 1h 45 min, 24 h and 14 days indicating no direct acute toxic effect of QNP. A significant increase in relative body weight gain was observed in QNP-treated mice as compared to control on 14 day of post-treatment and it may be due to obesity and effect of pesticide on adipose tissues or adiposity. Animal growth in terms of body weight, relative body weight gain, organ weight and relative organ weight are measured routinely for toxicological studies and are key parameters for interpretation of toxic effects (Hoffman *et al.*, 2002). A significant decrease was observed in relative organ weight of right testis after 24 h, however, left testis showed no significant change at 1 h 45 min, 24 h and 14 days post-treatment as compared with control group. In comparison with our results, Shahid *et al.* (2019) documented a significant decrease in absolute and

Table 3. Effect of oral exposure of mice to single MTD (15 mg/kg) of quinalphos on the body weight (g)

Treatment (p.o.) Days	Body weight (g)							
	0 th	2 nd	4 th	6 th	8 th	10 th	12 th	14 th
Control (1ml/100g)	24.60±2.02	24.60±2.02	25.00±2.21	26.50±1.75	26.40±1.75	26.70±1.90	26.80±1.90	27.20±1.76
QNP (15 mg/kg b.wt.)	24.50±1.96	24.50±1.96	25.60±2.09	26.20±2.06	26.90±2.32	27.40±2.23	28.70±1.86	29.70±2.11

Data are presented as mean ± SEM (n= 5 mice/group). The values were compared using unpaired Student's t-test.

Table 4. Effect of oral exposure of mice to single MTD (15 mg/kg) of quinalphos on relative body weight gain

Treatment (p.o.) Days	Relative body weight gain (g/100 g b.wt.)						
	2 nd	4 th	6 th	8 th	10 th	12 th	14 th
Control (1ml/100g)	0.0±0.0	1.44±1.11	2.92±1.84	2.92±1.84	4.23±1.53	4.25±2.35	4.89±1.85
QNP (15 mg/kg b.wt.)	0.0±0.0	4.43±0.94	7.01±1.42	9.60±1.68	11.92±3.05	15.23±5.79	18.24±4.50*

Data are presented as mean ± SEM (n= 5 mice/group). The values were compared using unpaired Student's t-test. * P≤0.05 in comparison to control.

Table 5. Effect of oral exposure of mice to single MTD (15 mg/kg) of quinalphos on relative organ weight of mice at 1 h 45 min, 24 h and 14 days post-treatment

Organ	Relative organ weight gain (g/100 g b.wt.)					
	Treatment					
	1h 45min		24 h		14 days	
	Control (1 ml/100g)	QNP (15 mg/kg b.wt.)	Control (1 ml/100g)	QNP (15 mg/kg b.wt.)	Control (1 ml/100g)	QNP (15 mg/kg b.wt.)
Heart	0.50±0.04	0.53±0.04	0.50±0.04	0.50±0.01	0.50±0.05	0.46±0.04
Liver	6.03±0.23	5.62±0.43	6.02±0.23	6.28±0.34	5.40±0.41	4.71±0.42
Left kidney	0.74±0.06	0.58±0.03	0.74±0.06	0.69±0.03	0.70±0.04	0.58±0.05
Right kidney	0.76±0.06	0.75±0.05	0.76±0.06	0.73±0.04	0.72±0.05	0.60±0.05
Spleen	0.69±0.18	0.41±0.05	0.69±0.18	0.49±0.05	0.40±0.04	0.36±0.05
Thymus	0.38±0.01	0.43±0.03	0.38±0.01	0.45±0.03	0.38±0.03	0.21±0.03**
Left testis	0.34±0.04	0.36±0.03	0.34±0.04	0.41±0.03	0.27±0.04	0.29±0.02
Right testis	0.35±0.04	1.15±0.80	0.35±0.04	0.10±0.01***	0.32±0.05	0.32±0.02
Left epididymis	0.10±0.01	0.35±0.23	0.10±0.01	0.09±0.01	0.10±0.01	0.10±0.00
Right epididymis	0.11±0.01	0.37±0.24	0.11±0.01	0.10±0.01	0.29±0.16	0.12±0.00

Data are presented as mean ± SEM (n= 5 mice/group). The values were compared using unpaired Student's t-test.

P ≤ 0.01, *P ≤ 0.001 in comparison to control.

Table 6. Effect of oral exposure of mice to single MTD (15 mg/kg) of quinalphos on acetylcholinesterase activity in blood and brain at 1 h 45 min, 24 h and 14 days post-treatment

Sample	1h 45min		24 h		14 days	
	Control (1 ml/100g)	QNP (15 mg/kg b.wt.)	Control (1 ml/100g)	QNP (15 mg/kg b.wt.)	Control (1 ml/100g)	QNP (15 mg/kg b.wt.)
Blooda	4.37±0.31	2.40±0.42**	4.37±0.31	3.04±0.24*	4.30±0.24	3.13±0.25
Plasmaa	3.28±0.49	1.57±0.18*	3.28±0.49	1.98±0.28	3.28±0.29	2.16±0.28
Erythrocytea	1.14±0.26	0.83±0.32	1.14±0.26	1.06±0.11	1.01±0.17	0.98±0.28
Brainb	11.55±0.88	12.18±0.41	11.55±0.88	8.22±0.20**	14.82±0.81	15.83±2.48

a - μmole of thiocholine produced/min/ml whole blood; b - μmole of thiocholine produced/ min/g brain

Data are presented as mean ± SEM (n= 5 mice/group). The values were compared using unpaired Student's t-test *P ≤ 0.05, **P ≤ 0.01 in comparison to control.

relative weights of the right and left testes in pyriproxyfen treated mice for 28 days. The testis weight is mainly dependent on the number of differentiated spermatocytes and reduction in the size of seminiferous tubules. Elongated spermatids and decreased population of germ

cells and seminiferous tubule fluid tend to decrease the weight of right testis (Sanchez-Pena *et al.*, 2004). This might be associated with increased apoptosis in right testes in comparison to left testis. This suggested that QNP may be slightly toxic to male reproductive system and can

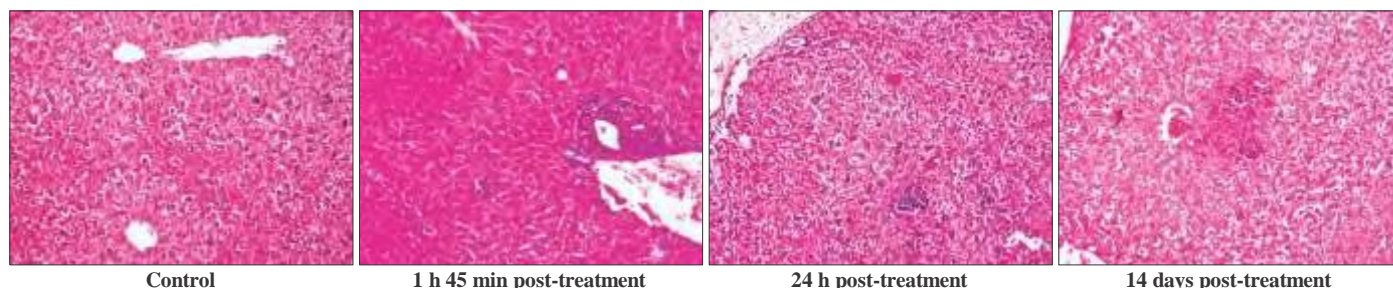


Fig. 1. Representative images (H&E stain 200 × magnification) of liver of mice of control and treatment groups exposed to single dose of MTD (15 mg/kg) of QNP at 1 h 45 min, 24 h and 14 days post-treatment

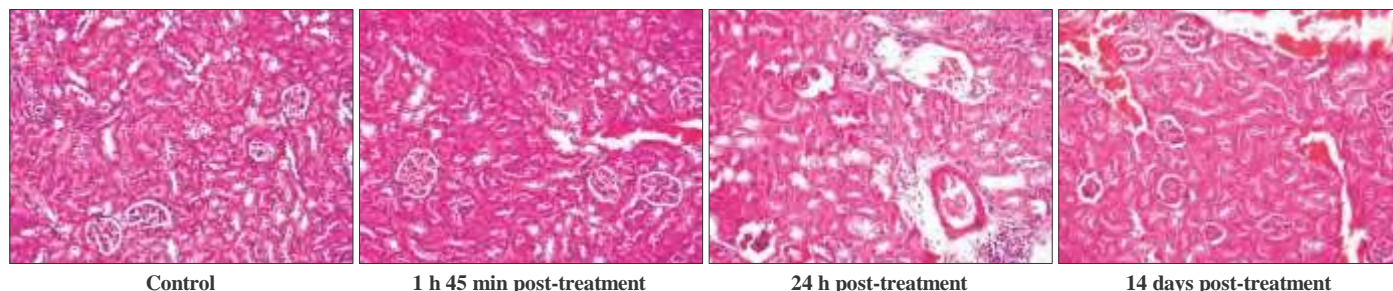


Fig. 2. Representative images (H&E stain 200 × magnification) of kidney of mice of control and treatment groups exposed to single dose of MTD (15 mg/kg) of QNP at 1 h 45 min, 24 h and 14 days post-treatment

Table 7. Effect of oral exposure of mice to single MTD (15 mg/kg) of quinalphos on haematological parameters at 1 h 45 min, 24 h and 14 days post-treatment

Time of exposure	Treatment (p.o.)	Hb (g/dl)	TEC ($10^6/\text{mm}^3$)	TLC ($10^3/\text{mm}^3$)
1 h 45 min	Control (1ml/100g)	13.00 ± 0.45	7.43 ± 0.27	4.80 ± 0.44
	QNP (15 mg/kg b.wt.)	12.12 ± 0.55	6.34 ± 0.42	6.08 ± 0.40
24 h	Control (1ml/100g)	13.00 ± 0.45	7.43 ± 0.27	4.80 ± 0.44
	QNP (15 mg/kg b.wt.)	13.72 ± 0.46	6.32 ± 1.14	6.44 ± 0.63
14 days	Control (1ml/100g)	13.92 ± 0.26	8.55 ± 0.16	5.12 ± 0.58
	QNP (15 mg/kg b.wt.)	10.96 ± 0.28 ***	6.06 ± 0.46 ***	8.20 ± 0.72 *

Hb: haemoglobin; TEC: total erythrocyte count; TLC: total leukocyte count. Data are presented as mean ± SEM (n= 5 mice/group). The values were compared using unpaired Student's t-test. *P ≤ 0.05, ***P ≤ 0.001, in comparison to control.

Table 8. Effect of oral exposure of single MTD (15 mg/kg) of quinalphos on differential leukocyte count (DLC) of mice at 1 h 45 min, 24 h and 14 days post-treatment

Time of exposure and treatment (p.o.)		Relative DLC (%)				
		Lymphocyte	Neutrophil	Monocyte	Basophil	Eosinophil
1 h 45 min	Control (1ml/100g)	85.20 ± 1.93	13.80 ± 1.91	1.00 ± 0.45	0.00 ± 0.00	0.00 ± 0.00
	QNP (15 mg/kg b.wt.)	71.00 ± 2.47 **	27.80 ± 2.76	1.20 ± 0.37	0.00 ± 0.00	0.00 ± 0.00
24 h	Control (1ml/100g)	85.20 ± 1.93	13.80 ± 1.91	1.00 ± 0.45	0.00 ± 0.00	0.00 ± 0.00
	QNP (15 mg/kg b.wt.)	75.80 ± 3.54	23.20 ± 3.46	1.00 ± 0.32	0.00 ± 0.00	0.00 ± 0.00
14 days	Control (1ml/100g)	80.40 ± 1.63	18.80 ± 1.28	0.80 ± 0.37	0.00 ± 0.00	0.00 ± 0.00
	QNP (15 mg/kg b.wt.)	70.00 ± 2.86 *	29.00 ± 3.08 *	1.00 ± 0.45	0.00 ± 0.00	0.00 ± 0.00

DLC: differential leukocyte count. Data are presented as mean ± SEM (n= 5 mice/group). The values were compared using unpaired Student's t-test. *P ≤ 0.05, **P ≤ 0.01 in comparison to control.

damage testis of male mice. However, further studies are needed to understand the quinalphos-induced reproductive toxicity.

A significant decrease was observed in relative organ weight of thymus after 14 days as compared with control group, which indicated that QNP may be toxic to

immune system. In the rest of treatment groups, no significant differences were observed in relative weight of any organ at 1 h 45 min, 24 h and 14 days post-treatment as compared with control group.

Effect of QNP on hematological parameters

The effect of QNP on hematological parameters is

given in table 7 and 8. Hb and TEC values were decreased significantly at 14 days post-treatment as compared with their respective control. A significant increase was observed in TLC after 14 days post-treatment as compared with control. Neutrophil counts significantly increased after 14 days and lymphocyte counts significantly decreased at 1 h 45 min and 14 days post administration in comparison to control. Hematological parameters such as Hb, TEC, TLC and DLC can be used as indicators of toxicity and have a broad potential application in environmental and occupational monitoring (Sancho *et al.*, 2000). Significant reduction in Hb and TEC suggested effect of QNP on suppression of hematopoietic system and increase in rate of the breakdown of RBC. Change in TLC and DLC count may be due to stress and sensitivity to inflammatory response ON QNP administration (Singh and Srivastava, 2010).

Effect of QNP on histopathological examination of liver and kidneys

Histopathological findings of liver and kidneys are shown in fig. 1 and 2. Histopathological lesions in liver of control group mice showed normal histological structure. Histopathological investigations of QNP-treated group at 1 h 45 min showed degenerative changes in hepatocytes with swollen eosinophilic cytoplasm, portal hepatitis characterized by infiltration of leucocytes in portal triad area and focal necrotic hepatitis with pyknotic hepatic nuclei encircled by leucocytes. Liver after 24 h of QNP treatment in mice showed similar lesions with more severe vascular changes such as congestion, hemorrhages and portal reactions along with multiple foci of focal hepatitis. At 14 days post-treatment, mice showed mild vascular changes in the liver parenchyma along with few areas of focal hepatitis in liver parenchyma.

Histopathological lesions in kidneys of control group mice at any interval did not reveal abnormal histological structure. Histopathological investigations at 1 h 45 min post-treatment in mice showed mild glomerular congestion, mild cellular swelling of tubular epithelium with eosinophilic cytoplasm. At 24 h post-treatment the kidney of mice showed moderate vascular changes with congestion and hemorrhages, hypertrophy of tubular epithelial cells and areas of perivascular reactions and focal nephritis characterized by pyknotic nuclei of tubular epithelial cells and focal infiltration of leucocytes. At 14 days post-treatment mice showed milder vascular, degenerative and necrotic changes in parenchyma. These findings indicated that QNP showed milder to moderate toxic effect on kidney at different time intervals which might be due to circulatory disturbance.

Histopathology gives a fast flowing method to detect effects of pesticides in various organs. Since liver is the target organ for biotransformation and excretion of many xenobiotic, histopathological findings in it suggested hepatotoxic effects of QNP at different time intervals. Histopathological findings in kidney indicated that QNP showing milder to moderate toxic effect on kidney at different time interval that might be due to circulatory disturbance.

It may be concluded that the MTD of QNP in mice through oral route was determined first time. The present toxicity study concluded that acute oral exposure of QNP produces hematological and histopathological changes and alteration in relative organ weights of male Swiss Albino mice with delayed toxic effects. Therefore, precautions should be taken when QNP will be used in the agricultural fields and veterinary practices.

REFERENCES

- Bagri, P. and Kumar, V. (2020). Acute oral toxicity study of anilofos in Swiss albino male mice. *The Haryana Veterinarian* **59**(1): 10-12.
- Bagri, P., Kumar, V., Sikka, A.K. and Punia, J.S. (2013). Preliminary acute toxicity study on imidacloprid in Swiss albino mice. *Vet. World*. **6**(12): 955-959.
- Chitra, K.C., Nikhila, P. and Asifa, K.P. (2013). Short-term exposure to quinalphos induced biochemical and hematological changes in freshwater fish, *Oreochromis mossambicus*. *J. Adv. Lab. Res. Biol.* **3**(1): 1-6.
- Hoffman, W.P., Ness, D.K. and Lier, B.N. (2002). Analysis of rodent growth data in toxicological studies. *Toxicol. Sci.* **66**(2): 313-319.
- Muttappa, K., Reddy, H.R.V., Rajesh, M. and Padmanabha, A. (2014). Quinalphos induced alteration in respiratory rate and food consumption of freshwater fish *Cyprinus carpio*. *J. Environ. Biol.* **35**(2): 395-398.
- Ramakrishnan, B., Megharaj, M., Venkateswarlu, K., Naidu, R. and Sethunathan, N. (2010). The impacts of environmental pollutants on microalgae and cyanobacteria. *Critic. Rev. Environ. Sci. Technol.* **40**(8): 699-821.
- Sanchez-Pena, L.C., Reyes B.E., Lopez-Carrillo, L., Recio, R., Morán-Martínez, J., Cebrian, M.E. and Quintanilla-Vega, B. (2004). Organophosphorous pesticide exposure alters sperm chromatin structure in Mexican agricultural workers. *Toxicol. Appl. Pharmacol.* **196**(1): 108-13.
- Sancho, E., Cerón, J.J. and Ferrando, M.D. (2000). Cholinesterase activity and hematological parameters as biomarkers of sublethal molinate exposure in *Anguilla anguilla*. *Ecotoxicol. Environ. Saf.* **46**(1): 81-86.
- Shahid, A., Zaidi, S., Akbar, H. and Saeed S. (2019). An investigation on some toxic effects of pyriproxyfen in adult male mice. *Iran J. Basic Med. Sci.* **22**(9): 997-1003.
- Singh, N.N. and Srivastava, A.K. (2010). Haematological parameters as bioindicators of insecticide exposure in teleosts. *Ecotoxicol.* **19**(5): 838-854.
- Weiss, D.J. and Wardrop, K.J. (2010). Schalm's Veterinary Haematology (6th Edn.), Blackwell Publishing Ltd., Iowa, USA. pp. 73-75.