

## ECG AND HAEMATOBIOCHEMICAL ALTERATIONS IN A DACHSHUND BITCH INFECTED WITH LARGE FORM OF *BABESIA*: A CASE REPORT

DEEPA RATHORE\* and TARUNPREET

Department of Veterinary Medicine, College of Veterinary and Animal Science,  
RAJUVAS, Navania, Udaipur-313601, Rajasthan

Received: 28.10.2023; Accepted: 12.12.2023

### SUMMARY

A 9 year old female Dachshund was presented with a complaint of fever, vomiting and a distended abdomen. Microscopic examination revealed presence of large form of *Babesia* spp. The haematological examination revealed anemia, thrombocytopenia and increase in number of circulating reticulocytes-biochemical examination revealed elevations in the levels of ALT (291.7 IU/L), AST (249.2 IU/L), BUN (76.6 mg/dL) and glucose (389.57). The study was also conducted to observe ECG changes associated with Canine babesiosis due to cardiac, hepatic and renal dysfunctions. The bitch was treated with diminazene aceturate but the patient showed no signs of recovery and passed on the following day.

**Keywords:** Blood protozoan parasite, ECG, Haemato-biochemical changes

**How to cite:** Rathore, D. and Tarunpreet (2024). ECG and haematobiochemical alterations in a Dachshund bitch infected with large form of *Babesia* : A case report. *Haryana Vet.* 63(2): 288-289.

Babesiosis is a tick-borne disease in dogs caused by haemoprotozoan parasite (Yadav *et al.*, 2021; Sangeetha *et al.*, 2022; Gowtham *et al.*, 2022). *Babesia vogeli* (large form) and *Babesia gibsoni* (small form) are the most commonly reported species in dogs from India (Reddy *et al.*, 2022). During the course of the disease, anaemia produces hypoxia and the resulting myocarditis can induce arrhythmias and abnormalities in electrocardiography (Reddy *et al.*, 2022). Hence in the present case a thorough investigation was aimed at observing various clinico-haemato-biochemical and ECG alterations of *Babesia* infection in canines.

A Dachshund female (Fig. 2) of 9 years of age was presented to VCC, Navania, Udaipur for treatment. Both peripheral blood and whole blood were drawn for blood smear examinations and different blood parameters respectively. Blood samples were taken using EDTA vials so that plasma could be extracted for biochemical analysis. Plasma concentrations of aspartate amino transferase (AST), alanine aminotransferase (ALT), blood urea nitrogen (BUN) and glucose were determined by biochemistry auto-analyzers (BIO-CHEMISTRY AUTO ANALYZER CAT No. BGS-246). ECG was recorded with a paper speed of 50 mm/sec. Tilley's (1992) guidelines were followed for the interpretation of electrocardiograms. The bitch was already dewormed.

On clinical examination, congested mucous membrane with elevated temperature (105 °F), pulse rate (108 bpm) and respiration rate (27 breaths/min). Pupillary light reflex and menace reflex were sluggish. Babesiosis was confirmed as a diagnosis by showing the parasites within the infected erythrocytes in thin blood smears stained with

Giemsa (Fig. 1). Their morphology is pyriform. The serum haematological parameters showed neutrophilia (91%), leukocytosis ( $39.7 \times 10^3/\mu\text{L}$ ) and lymphocytopenia (7%). The haematological findings were in accordance with Bilwal *et al.*, 2017. Serum biochemistry revealed elevations in the levels of ALT (291.7 IU/L), AST (249.2 IU/L), BUN (76.6 mg/dL) and glucose (389.57). These findings were similar to the previous finding of study by Mittal *et al.* (2019) and Sahu *et al.* (2020) found that the affected dogs had increases in ALT, AST and BUN. On faecal examination no parasitic ova were seen.

Electrocardiographic studies revealed (Fig. 3) prolonged P wave duration (P mitrale or 0.06 sec) which was in contrast to normal P wave duration which is 0.04 sec, T wave amplitude was greater than 25% of R wave amplitude (0.45 mV), absence of Q wave and ST coving (Sahoo *et al.*, 2022).

Bitch was treated with Inj. Diminazene aceturate @ 5mg/kg b.wt. deep intramuscularly along with Tablet furosemide+spironolactone, Tablet Lisybin (S-adenosyl methionine and Silybin A+ B), Tablet Nefrotec + Powder Nefrotec and losartas, at 25 mg. Cardiac dysfunction in canine babesiosis is considered a rare complication (Gowtham *et al.*, 2022). Prolong P wave (P-mitral) was seen due to following of haemodynamic disturbances to the left atrium that damaged the cells (Shahoo *et al.*, 2021; Reddy *et al.*, 2022). After the formation of the P wave a flat base line indicated the absence of the Q wave on ECG graph. The tall T wave was recognized by amplitude of T wave more than R/4 amplitude and it was associated with hyperkalemia (more than 5.5 mEq/L) (Chaudhuri *et al.*, 2017). ST coving was diagnosed as a delayed return to

\*Corresponding author: tarunpreetsran@gmail.com

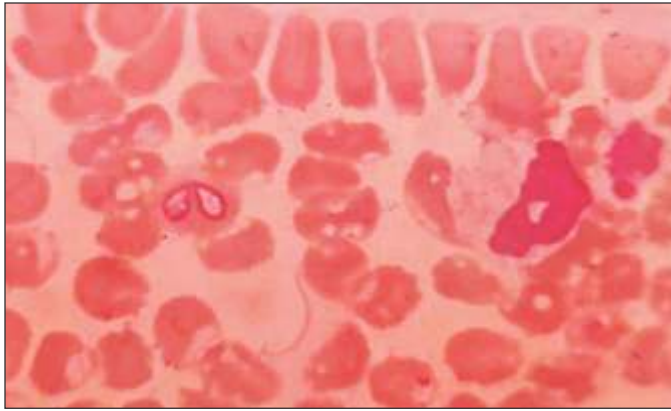


Fig. 1. Babesiosis in thin blood smear

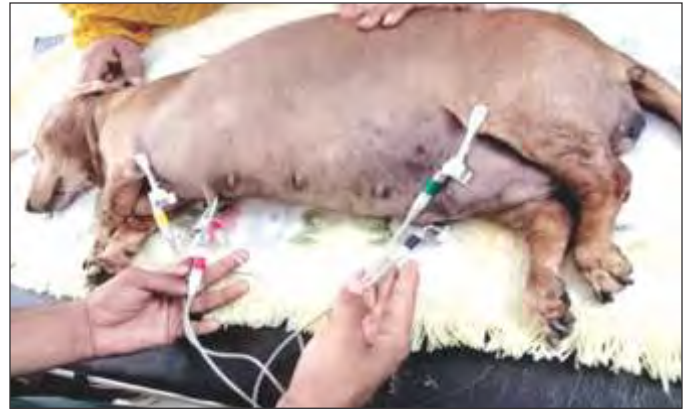

Fig. 2. Babesiosis in Dachshund female dog

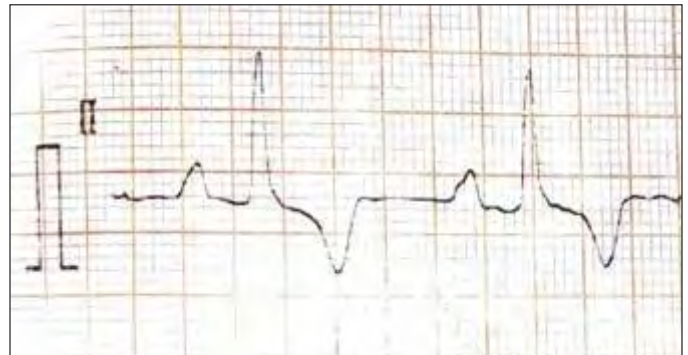

Fig. 3. Electrocardiographic image of infected dog

baseline in the ST segment or curved terminal upstroke of S wave or displacement of the ST segment in the opposite direction of QRS deflection, ST coving associated with endocardial ischaemic changes (Sahoo *et al.*, 2021; Gowtham *et al.*, 2022). The present data of the study indicates that canine babesiosis can affect the cardiac tissues resulting in ECG changes.

Canine babesiosis infection which is commonly observed in dogs may affect vital organs including heart and the early diagnosis will be helpful to prevent multi organ failure due to this infection. The cardiac dysfunction due to canine babesiosis is considered as a rare complication, but it was visible in this case. In current investigation we could not save the life of animal as there was a delay in the treatment of disease and the case was not timely reported by the owner. This paper will be useful for early diagnosis of cardiac dysfunction associated with canine babesiosis infection and this will help in saving the lives of dogs.

## REFERENCES

- Chaudhuri, S., Varshney, J. and Changkija, B. (2017). Electrocardiographic changes in canine babesiosis. *Arch. Palliat. Care.* **2**(2): 1014.
- Ghosh, C.K., Banerjee, A., Mridha, F., Sarkar, P. and Sarkar, S. (2020). Ascites in a Doberman pinscher pup due to *Babesia* infection: A case report. *Pharma Innov. J.* **9**(7): 253-255.
- Gowtham, R.M., Gowri, B., Kavitha, S. and Leela, V. (2022). Myocardial dysfunction due to babesiosis in a dog. *Indian J. Vet. Anim. Sci.* **51**(4): 84-90.
- Pandey, P., Rani, P. and Kumar, M.K.B. (2022). Peritoneal effusion due to babesiosis and its therapeutic management in dog- A rare case report. *Indian J. Vet. Med.* **42**(1): 54-56.
- Reddy, B.S., Sivajothi, S. and Swetha, K. (2022). Electrocardiographic findings and alterations of cardiac troponin in dogs with *Babesia gibsoni*. *Pharma Innov.* **11**(11): 2376-2378.
- Sahoo, K. K., Gupta, D., Tiwari, A., Rai, S., Sawhney, A., Sharma, P. and Bhatt, S. (2022). Morphological variation of electrocardiogram: A boon in diagnosis of canine cardiac disorders. *Pharma Innov. J.* **11**(1199-1202): 4.
- Sangeetha S.G. and Raguvaran R. (2022). SIRS, MODS and IMHA associated with *Babesia canis* infection in a German Shepherd pup and its therapeutic management. *J. Indian Vet. Assoc.* **20**(1).
- Shivani, S., Maurya, P.S., Sudhakar, N.R. and Jeny, K.J. (2020). Clinico-haematological alteration in a Labrador dog affected with babesiosis and its therapeutic management. *Haryana Vet.* **59**(1): 146-147.
- Bilwal, A.K., Mandali, G.C. and Tandel, F.B. (2017). Clinicopathological alterations in naturally occurring *Babesia gibsoni* infection in dogs of Middle-South Gujarat, India. *Vet. World.* **10**(10): 1227-1232.
- Mittal, M., Kundu, K., Chakravarti, S., Mohapatra, J.K., Singh, V.K., Kumar, B.R. and Kumar, A. (2019). Canine babesiosis among working dogs of organised kennels in India: A comprehensive haematological, biochemical, clinic-pathological and molecular epidemiological multiregional study. *Prev. Vet. Med.* **169**: 104696.
- Yadav, N., Mondal, D.B., Raguvaran, R., Sharma, D.K., Das, A.K., Kumar, N. and Verma, M.R. (2021). Evaluation of oxidative stress indices and disseminated intravascular coagulation in *Babesia gibsoni* infected dogs with respect to different therapeutic modalities. *Haryana Vet.* **60**(2): 188-190.