

## MANAGEMENT OF INGUINAL HYSTEROCELE OF UNILATERAL PYOMETRA IN A SPITZ BITCH

J. UMAMAGESWARI\*, DIVYA CHAVAN, S. RANGASAMY, M. NAVEENA,  
M.G. MOHAMED ALI<sup>1</sup> and K. KRISHNAKUMARDepartment of Veterinary Gynaecology and Obstetrics, <sup>1</sup>Department of Veterinary Surgery and Radiology,  
Madras Veterinary College, Tamil Nadu Veterinary and Animal Sciences University, Chennai-600007

Received: 27.07.2023; Accepted: 16.09.2023

## SUMMARY

An 11-year-old, sexually intact Spitz bitch was brought to the Small Animal Obstetrics and Gynaecology unit of Madras Veterinary College Teaching Hospital, Chennai with the history of blood-tinged vaginal discharge and anorexia for the past one month. On clinical examination, a soft swelling in the inguinal region was noticed and no pain evinced on palpation. Vaginal mucosa was hyperemic with blood-tinged vaginal discharge noticed. A lateral radiographic view of the abdomen demonstrates radiopaque content of herniated mass. Ultrasonographic imaging of the abdomen revealed hypoechoic thickened uterine horn while examination of inguinal mass showed anechoic sacculization of tubular structure which could be other side of uterine horn. Hence, based on clinical, ultrasound and radiographic examinations, unilateral pyometra with hysterocele was confirmed. A successful ovariohysterectomy and herniorrhaphy was performed and the bitch recovered uneventfully.

**Keywords:** Hysterocele, Inguinal hernia, Pyometra

**How to cite:** Umamageswari, J., Chavan, D., Rangasamy, S., Naveena, M., Mohamed Ali, M.G. and Krishnakumar, K. (2024). Management of inguinal hysterocele of unilateral pyometra in a Spitz bitch. *Haryana Vet.* 63(2): 279-282.

Canine pyometra has been studied for several decades to identify the disease pathogenesis and its incidence. Many researchers have reported that 15-20% of bitches develop pyometra at the age of 6-10 years. However, reports also indicate that this disease condition may occur 4 weeks to 4 months after estrus and believed to be linked to hormonal influence (Byers *et al.*, 2007). Several theories have proposed that pyometra develops by the influence of estrogen and progesterone on the uterus by stimulating endometrial glands secretion and suppressing both leukocyte response and uterine contractions (De Bosschere *et al.*, 2002). Other factors like bacterial, hematogenous and ascending urinary tract infections have been studied repeatedly which indicates that pyometra is possibly a multifactorial disorder and the pathogenesis of which is not completely understood (Clark Xavier *et al.*, 2023). At the same time, in intact bitch apart from pyometra, inguinal hernia is also considered to be commonly described conditions of which uterine inguinal hernia are frequent and remains unnoticed until there is distension of uterus by pregnancy or uterine infection especially pyometra. The present report describes the clinical presentation, diagnosis, and treatment of case of inguinal hysterocele with unilateral pyometra in a 11-year-old, sexually intact Spitz bitch.

## Case report

An 11-year-old, Spitz bitch weighing 8 kg was presented with a history of intermittent blood-tinged vaginal discharge and inappetence for past one month. The owner also reported that the animal was not bred so far and

the last heat was observed one year back. On clinical examination, the bitch appeared dull with body temperature found to be 39.2° C. On abdominal examination, a soft tissue mass was noticed in the left inguinal region (Fig. 1a) and on palpation no pain was evident. Several attempts were made to reduce the swelling manually, but it went in vain. Vaginal examination revealed hyperemic vaginal mucosa with blood-tinged discharge noticed within the vaginal lumen. Vaginal exfoliative cytology (Fig. 1b) revealed predominance of intermediate cells (around 80%) and neutrophils indicating animal was in diestrus. Lateral radiographic view of the abdomen demonstrates radiopaque content of herniated mass (Fig. 2). Ultrasonographic imaging of the abdomen revealed hypoechoic thickened uterine horn while examination of inguinal mass showed anechoic sacculization of tubular structure which could be the other side of uterine horn (Fig. 3). Hematology and serum biochemistry results showed relative neutrophilia.

Hb	16.4 g/dl	Glucose	67 mg/dl
PCV	47.2%	Cholesterol	127 mg/dl
RBC	7.08 m/cmm	Total protein	5.1 g/dl
WBC	18,600/cmm	Albumin	3.3 g/dl
Platelets	3,53,000/cmm	BUN	17.67 mg/dl
Neutrophils	92%	Creatinine	1.06 mg/dl
Lymphocytes	6%		
Monocytes	2%		

Based on the clinical examination and diagnostic findings, unilateral pyometra with hysterocele was confirmed. Animal was stabilized using Inj. Ringer's lactate (@10ml/kg body weight, IV), Inj. Ceftriaxone (Intacef @20mg/kg BW, IV) and Inj. Pantaprazole

\*Corresponding author: drjumamageswari@gmail.com

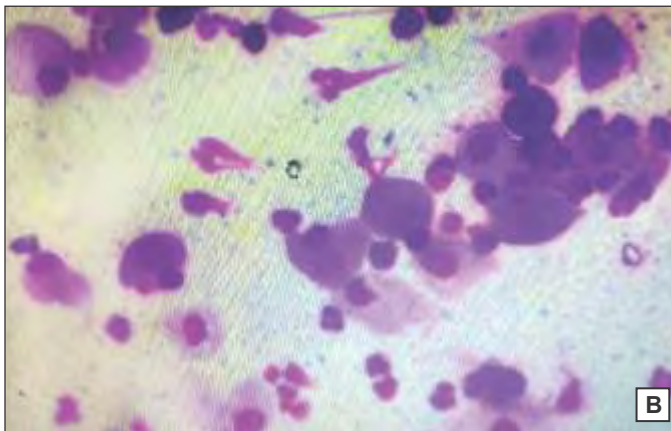


Fig. 1. (a) Soft tissue mass noticed in the left inguinal region; (b) VEC showed predominant of intermediate cells and neutrophils

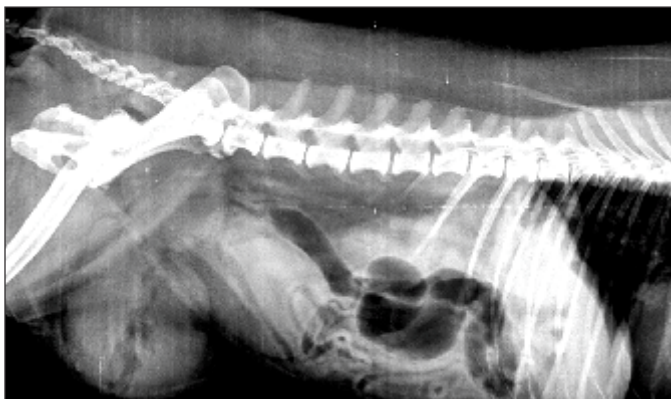

Fig. 2. Lateral radiographic view of the abdomen demonstrates radiopaque content of herniated mass

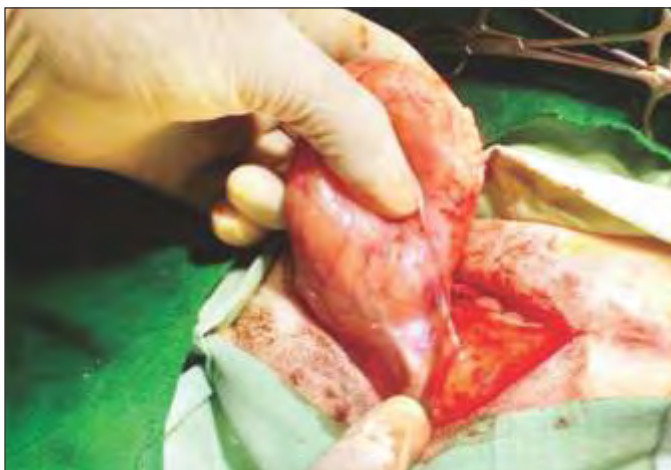

Fig. 4. Herniated sac in left inguinal region of spitz bitch

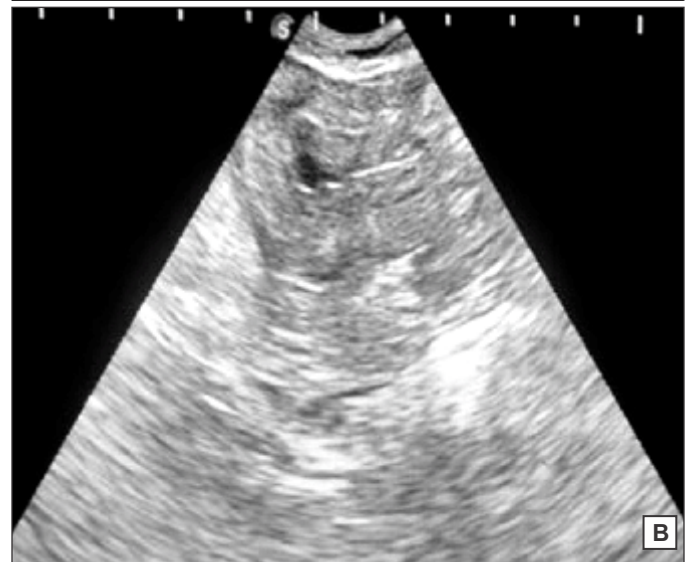
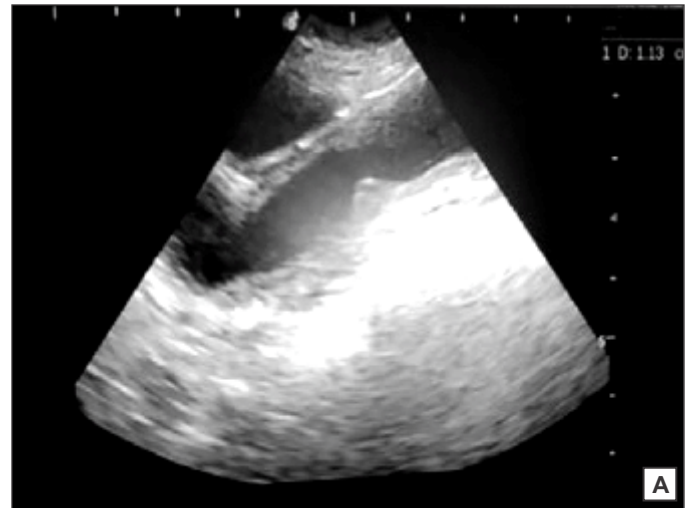
Fig. 3. Ultrasonographic Examination (a) Inguinal region showing anechoic sacculation of tubular structure (b) Abdomen revealing hypoechoic thickened uterine horn

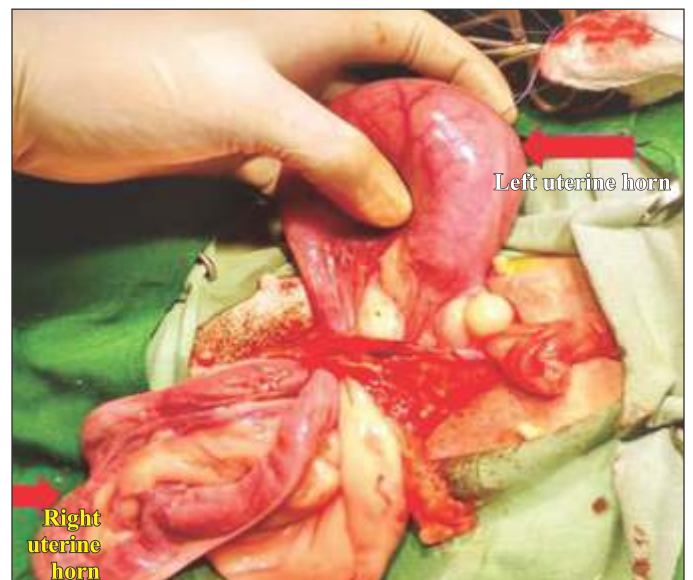

Fig. 5. Dissection of hernial sac showed left uterine horn distended with fluid while right uterine horn appeared normal in the abdomen of Spitz bitch

(Pantotas @ 1mg/kg BW, IV) after which the bitch was prepared for surgery and premedicated with atropine (@ 0.04 mg/kg BW, SC) and xylazine (@1mg/kg BW, IM). Induction of anaesthesia with Ketamine @ 10 mg/kg BW and Diazepam @ 0.3 mg/kg BW and maintained with Propofol @ 3-5 mg/kg BW, after preparing the surgical site a midline incision was made exposing the hernial sac on the left inguinal region (Fig. 4). Blunt dissection of hernial sac exposed left uterine horns distended with fluid filled lumen (Fig. 5). The herniated uterus was reduced manually followed by ovariohysterectomy. The hernial sac neck was amputated and the inguinal ring edges were sutured with interlocking sutures with Polyglycolic Acid Suture (PGA) 1-0 suture material. The right-side inguinal ring was found to be normal. The linea alba and subcutaneous tissue were sutured with PGA 2-0 followed by skin closure with polyamide 1/0. The bitch was treated postoperatively using Inj. Ringer's lactate (@10 ml/kg BW, IV), Inj. Ceftriaxone (@ 20 mg/kg BW, IV), Inj. Metronidazole (@15 mg/kg BW, IV) for 7 days and Inj. Meloxicam (@0.2 mg/kg BW, S/C) for 3 days. No postoperative complication was observed and bitch recovered uneventfully.

In female dog, inguinal hernia may likely to occur when the uterus enlarges in pregnancy or disease condition like pyometra, mucometra or haematometra as the round ligament pulling a part of the uterus into the hernial sac. Although, congenital inguinal hernia is less common in dogs, some breeds like Cocker spaniel, Chihuahua, Basset hound, Basenji, Poodle, Dachshund, Cairn terrier, Cavalier King, Pekingese, Pomeranian, Charles spaniel and Maltese are mostly predisposed (Hayes *et al.*, 1974). While acquired inguinal hernia may affect any breed of dog. Factors which increase intra-abdominal pressure like pregnancy or obesity and steroid hormones especially estrogen and other factors like trauma, abdominal wall weakening due to altered nutritional status increases the chance of occurrence of acquired inguinal hernia (Smeak *et al.*, 2012). This was based on fact that changes in steroid hormone during estrus, pregnant/non-pregnant diestrus weakens the connective tissue and due to continuous exposure of animal to steroid hormone like estrogen during each estrus cycle may bring about protrusion of uterus into the inguinal region and results in inguinal herniation. However, in the present case, rise in steroid hormone like progesterone during diestrus leads to increased endometrial gland secretion, increased endometrial proliferation, reduced contraction of myometrium together with bacterial infection will favor the accumulation of purulent substance in the uterus. Added to this, increase in abdominal pressure due to uterine infection may lead to hysterocele involving only the half of the pyometra uterus.

Further, advanced diagnostic technique like ultrasonographic imaging will be helpful to differentiate the inguinal mass from mammary gland tumour, hypertrophy of lymph node, inguinal herniation, hematoma, abscessation, and granuloma. In the present case, anechoic sacculations with hypoechoic tubular structure was noticed on ultrasonographic examination which indicates that the incarcerated structure in the herniated sac was pyometra uterus. At the same time, there may be chance for protrusion of other abdominal organs like omentum (Sharma *et al.*, 2021) spleen, intestine, ovary and urinary bladder through the inguinal canal which can better be differentiated by detailed ultrasound examination. Wright *et al.* (1963) reported that broad ligament and uterus are the most common herniated content in bitches although other organs like omentum, intestine, spleen and urinary bladder may be rarely found in inguinal hernia (Strande *et al.*, 1989).

In conclusion, uterine herniation should be included as differential diagnosis in any intact bitch presenting with an inguinal mass. With relating to the clinical signs of pyometra as mentioned earlier if vaginal exfoliative cytology shows predominance of neutrophils in diestrus phase, pyometra should be suspected and confirmatory diagnosis should be done by ultrasonographic examinations. Hence, for aged dogs and also in those breeds which are more prone to inguinal hernia at the same time not intended for breeding purpose, ovariohysterectomy could be recommended treatment of choice in order to eliminate the risk of hysterocele. However, in this case herniated content was found to be pyometra uterus, such development is considered to be more dangerous than normal abdominal position of pyometra uterus.

## REFERENCES

- Byers, C.G., Williams, J.E. and Saylor, D.K. (2007). Pyometra with inguinal herniation of the left uterine horn and omentum in a Beagle dog. *J. Vet. Emerg. Crit. Car.* **17**: 86-92.
- Clark Xavier, R.G., Santana, C.H., Gonçalves de Castro, Viana de Souza, T.G., Santos do Amarante, V., Lima Santos, R. and Silveira Silva, R.O. (2023). Canine Pyometra: A short review of current advances. *Animals (Basel)*. **13**(21): 3310-3318.
- De Bosschere, H., Ducatelle, R. and Vermeirsch, H. (2002). Estrogen – alpha and progesterone receptor expression in cystic endometrial hyperplasia and pyometra in the bitch. *Anim. Reprod. Sci.* **70**(3-4): 251-259.
- Dean, P.W., Bojrab, M.J. and Constantinescu, G.M. (1998). Inguinal hernia repair in the dog. In: Bojrab MJ, ed. *Current techniques in small animal surgery*. (4<sup>th</sup> Edn.) Philadelphia, Pennsylvania: Lea & Febiger. **4**: 552-554.
- Dhaliwal, G.K., Wray, C. and Noakes, D.E. (1998). Uterine bacterial flora and uterine lesions in bitches with cystic endometrial hyperplasia (pyometra). *Vet. Rec.* **143**(24): 659-661.
- Dhaliwal, G.K., England, C.W. and Noakes, D.E. (1999). Oestrogen

- and progesterone receptors in the uterine wall of bitches with cystic endometrial hyperplasia/pyometra. *Vet. Rec.* **145(16)**: 455-457.
- Gogny, A., Bruyas, J.F. and Fieni, F. (2010). Pyometra in an inguinal hernia in bitch. *Reprod Dom Anim.* **45**: 461-464.
- Gupta, A.K., Dhami, A.J., Patil, D.B., Kumar, D. and Darr, M. (2013). Clinical and ultrasonographic evaluation of bitches affected with pyometra. *Indian J. Field Vet.* **8(3)**: 1-4.
- Hardie, E.M. (1995). Life-threatening bacterial infection. The compendium on continuing education for the practicing veterinarian (USA).
- Munro, E. and Stead, C. (1993). Ultrasonographic diagnosis of uterine entrapment in an inguinal hernia. *J. Small Anim. Pract.* **34**: 139-141.
- Park, C.H., Kim, B.S. and Lee, J.H. (2008). Pyometra with inguinal herniation in a Dachshund dog. Proc. The 15<sup>th</sup> Congress of FAVA, 27-30 October 2008, Bangkok, Thailand. pp. 331-332.
- Patil, A.R., Swamy, M., Chandra, A. and Jawre, S. (2013). Clinico-haematological and serum biochemical alterations in pyometra affected bitches. *Afr. J. Biotechnol.* **12(13)**: 1564-1570.
- Sharma, S., Chaudhary, R.N., Tiwari, D.K., Arora, N., Niwas, R. and Bhardwaj, V. (2021). Ventral epiplo-hysterocoele in a pug. *Haryana Vet.* **60(SI)**: 97-98.
- Smeak, D.D. (2012). Inguinal hernias. In: Tobias KM, Johnston SA, eds. *Veterinary Surgery: Small Animal*. (1<sup>st</sup> Edn.), St. Louis, Missouri: Elsevier Saunders: 1358-1361.
- Strande, A. (1989). Pyometra in basset bitch. *Vet. Rec.* **99**: 344.
- Waters, D.J., Roy, R.G. and Stone, E.A. (1993). A retrospective study of inguinal hernia in 35 dogs. *Vet. Surg.* **22**: 44-49.
- Wright, J.R. (1963). The surgery of inguinal canal in animals. *Vet. Rec.* **75**: 1352-1363.

## CONTRIBUTORS MAY NOTE

- Research/Clinical articles are invited for next issue from the Scientists/Veterinarians engaged in Veterinary Profession.
- Please follow strictly the format of 'The Haryana Veterinarian' for manuscript writing/submission.
- Please pay processing fee of Rs. 1200/- online in the account of Dean, College of Veterinary Sciences, along with each article.
- After revision, please return the revised manuscript and rebuttal at the earliest.
- Please mention your article reference number in all correspondence for a quick response.
- We solicit your co-operation.
- All correspondence should be addressed to 'The Editor', Haryana Veterinarian, Department of Veterinary Parasitology, College of Veterinary Sciences, LUVAS, Hisar-125004.

Editors