

GROSS ANATOMICAL STUDY ON MIDDLE EAR OSSICLES IN INDIGENOUS GOATS (*CAPRA HIRCUS*)

S.A.V. MANIKANTA SARMA, DEVENDRA PATHAK*, VARINDER UPPAL and OPINDER SINGH

Department of Veterinary Anatomy, College of Veterinary Science (Ludhiana)
Guru Angad Dev Veterinary and Animal Sciences University, Ludhiana, India

Received: 12.11.2023; Accepted: 22.01.2024

ABSTRACT

The present study was conducted on the middle ear ossicles of six adult Beetal goats (*Capra hircus*). The goat heads were collected from a municipal slaughterhouse in Ludhiana. Access to the ossicular assembly was made from the base of the tympanic bulla by cutting the occipital bone with a bone saw blade at the level of condyles and para mastoid processes at an angle parallel to the ventral surface of the tympanic bulla without damaging the bony part of the middle ear canal. It was observed that the ossicular assembly of Beetal goats was formed by three ear ossicles named malleus (hammer), incus (anvil), and stapes (stirrup). The malleus was the most peripheral and was composed of a head, neck, and manubrium. The head of the malleus possessed an oval articular facet on its medial surface. The neck of the malleus was comprised of three processes viz., lateral, rostral, and muscular. The manubrium of the malleus was the longest, with a length of $0.46 \text{ cm} \pm 0.009$, and appeared slightly curved. The shape of the incus was like a biradicular molar and it presented a body and two processes, the short and long crura, of which the lenticular process was present only on the long crus. The stapes was the smallest and consisted of a head, an anterior, a posterior arm, and a footplate.

Keywords: Middle ear, Goat, Gross anatomy, Ossicles

How to cite: Manikanta Sarma, S.A.V., Pathak, D., Uppal, V. and Singh, O. (2024). Gross anatomical study on middle ear ossicles in indigenous goats (*Capra hircus*). *Haryana Vet.* 63(2): 206-209.

In ways that humans cannot, animal models of middle ear surgery enable us to investigate disease mechanisms. According to the authors, the ear underwent a protracted evolutionary process lasting more than 300 million years. Mammals have been known to have three ossicle assemblies (Amin and Tucker, 2006); Takechi and Kuratani, (2010), while birds have a unique circumstance where just one ossicle-the *Columella auris*-is known to exist (Anthwal *et al.*, 2013; Besoluk *et al.*, 2019; Claes *et al.*, 2016; Mills, 1994; Takechi and Kuratani, 2010). It has been claimed that stapes is the name given to the same bony structure in reptiles and proposed that the articular and quadrate bone in non-mammals serve as analogues of the malleus and incus described in mammals (Anthwal *et al.*, 2012). Goats are known as excellent models for experimental scientific studies, reconstructive surgical procedures of the ossicular chain, and training in human ear surgery due to the size of the middle ear and anatomical similarities with human ossicles.

The Malleus, Incus, and Stapes have all evolved from the jawbones of mammals and the *Columella auris* of reptiles, respectively. These three tiny bones are irregularly shaped and laterally located in the tympanic cavity. This articulated chain of ossicles connects the tympanic membrane and medial wall of the tympanic cavity which transfers sound from the tympanic membrane to the cochlea through an oval window (Ludman and Wright, 2006); Strandring (2008). As a transformer of air acoustic energy's impedance towards the fluids of the inner ear, this

ossicular assembly's primary job was to mediate the transmission of vibrations from the tympanic membrane through the handle of the malleus (*Manubrium mallei*) and send them over toward the components of the internal ear (Wilson, 1987; Keefe, 2015).

In middle ear surgical research, rats and mice are the most frequently utilized small vertebrate animals. However, other small vertebrate animals are being used, including rodents (such as gerbils, chinchillas, and guinea pigs), rabbits, and cats. The findings can vary greatly since small animals are morphologically and physiologically different from humans and show differing middle ear shapes and sizes (Hemilä *et al.*, 1995). Large animal models have also been examined to better represent the human ear's anatomy. For instance, the pig has been considered a potential animal model; however, experimental methods are challenging because of the soft and fatty tissues covering the mastoid process (Schnabl *et al.*, 2012). In the present day, due to the widespread trans-canal endoscopic surgery in humans, especially in the middle ear, goats can be used as an animal model for studying the middle ear ossicles due to its advantageous size. The anatomical features and parameters of the middle ear are frequently utilized to predict the species' hearing sensitivity (Hadžiomeroviae *et al.*, 2023). Therefore, the current study was planned to record various anatomical and morphometrical data regarding the middle ear ossicles in native Beetal goats which may help researchers and clinicians in various interventions.

*Corresponding author: drdevendra@gmail.com

MATERIALS AND METHODS

Six freshly slaughtered adult goat heads were collected from a municipal slaughter house in Ludhiana, India. The tissues surrounding the tympanic bulla were removed and the ventral surface of the bulla was cut open. Access to the ossicular assembly was made from the base/ventral surface of the tympanic bulla by cutting through the occipital bone with a bone saw blade at the level of occipital condyles, and para mastoid processes at an angle parallel to the ventral surface of the tympanic bulla without damaging the bony part of the middle ear canal (Fig. 1). Examination of middle ear structures was done by using a magnifying lens and stereo zoom microscope. The images of ear ossicles were captured using an iPhone camera in macro mode, 12 megapixels. The terminology of all the anatomical structures was adopted in accordance to *Nomina Anatomica Veterinaria* (2017).

Morphometrical data recording

Measurements were recorded by using vernier calipers (Fig. 2). The parameters for the measurements were the length and width of ear ossicles, the width of the malleus at the broadest point, vertical diameter, the thickness of the malleus' narrow, concave neck, length of malleus' manubrium, length of long crus and short crus of the incus, and length of rostral and caudal crus of Stapes (Fig. 3). The mean and standard errors of respective data were calculated using the MS Excel programme. The data for the length and width at the broadest point were analysed and presented as graphs with GraphPad Prism 8.0.2. Normality tests were done on all three data sets and subjected to one-way analysis of variance (ANOVA) and Tukey's multiple comparisons test to find statistical differences in the length and width of the three ear ossicles.

RESULTS AND DISCUSSION

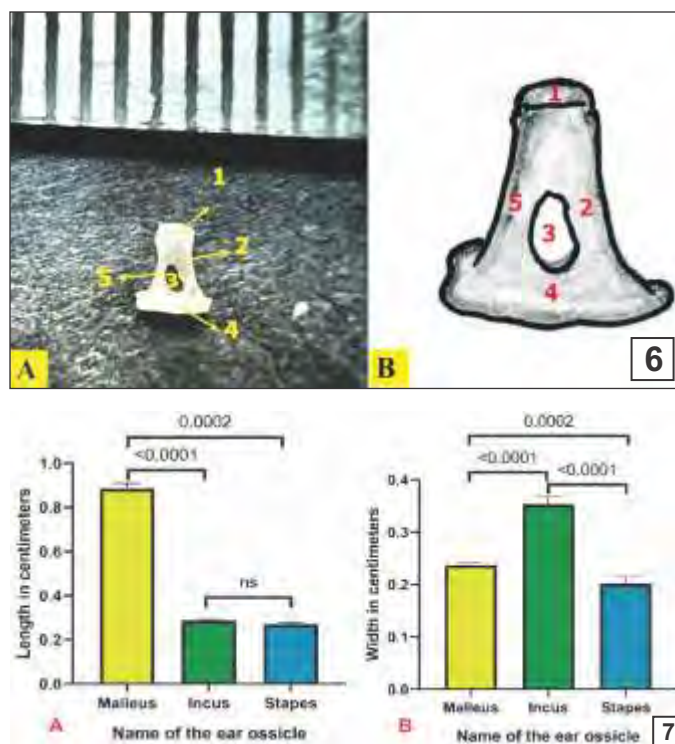
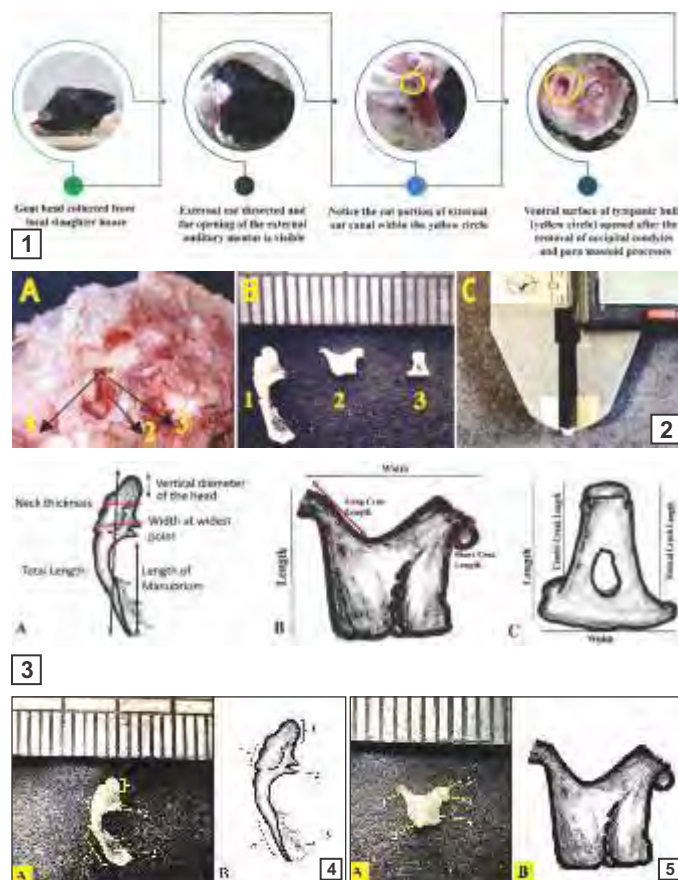
The assembly of the three ossicles was disclosed when the occipital condyles and para mastoid processes were removed properly. The lateral component was the malleus, followed by the connection with the incus, and the most medial one being the stapes. The finding of the presence of three ossicles' assembly at the level of the tympanic cavity was in consonance with the findings in non-human primates (Borin *et al.*, 2008), sheep (Simaei *et al.*, 2017), wolves (Gürbüz *et al.*, 2019) and rabbits (Guan *et al.*, 2019). However, Nazih (2017) reported fourth ear ossicle in donkey.

The malleus or drumstick bone consisted of the malleus head (*Caput mallei*), a slightly narrowed neck (*Collum mallei*) with three separate processes (lateral, rostral and muscular) (Processus lateralis, Processus rostralis and Processus muscularis), and a handle (*Manubrium mallei*) (Fig. 4A, B). When viewed from the

lateral side, the head of the malleus (*Caput mallei*) had an overall oval form with a dorso-caudal disposition. Its medial surface had an articular surface for the incus (*Facies articularis*). The neck was tuberos and nearly flattened near the head. As approached the handle, it was more cylindrical, and its diameter reduced significantly. Tensor tympanic muscle insertion was provided by the muscular process (*P. muscularis*) on the neck of malleus. The morphometrical data of Malleus has been presented in Table 1. The malleus, or drumstick bone, in goats was 0.885 ± 0.009 cm long. It was the longest ear ossicle. The average width of the malleus at the broadest point was 0.24 ± 0.002 cm. The oval-shaped malleus head had an average vertical diameter of 0.33 ± 0.009 cm. The malleus' narrow, concave neck was 0.21 ± 0.005 cm in thickness. The malleus' manubrium, or handle, was the longest part and measured 0.46 ± 0.009 cm in length and had a concave rostral edge. It was firmly connected to the eardrum and dragged the center inwards to the tympanic cavity. The handle of the goat's malleus bone accounted for roughly 70% of the entire malleus length (Hadžiomerović *et al.*, 2023). The same observations were reported in goats (Martonos *et al.*, 2020). But contrast to this, neck of malleus with only 2 processes, the lateral and rostral, was reported in *Capra aegagrus hircus*, a subspecies of goat domesticated from Southwest Asia and Eastern Europe (Tolba, 2016).

The body of Incus (*Corpus incudes*) housed two processes: a short process and a lengthy process (*Crus breve* and *Crus longum*, respectively) (Figs. 5A, B). The incus was a biradicular molar in shape. The body of incus had an articular process for malleus on rostral extremity. Similar observations were reported in camel (Osman and Arnautovic, 1987) and rabbit (Arnautovic and Osman, 1985). Contrarily, Martonos *et al.* (2020) reported that the short and long crura in *Capra hircus* were nearly of the same length, with the long crus projecting obliquely. In addition, the long root of the incus showed one tiny bone, known as the lenticular process in rabbits (Kurtul *et al.*, 2003), which could not be seen in the Beetal goats. The morphometrical data of Incus has been presented in Table 2. It was a short, broad bone that was 0.29 ± 0.002 cm long, and 0.35 ± 0.006 cm wide. The cuboidal body of incus was located in the tympanic cavity caudal to the malleus' head. The long crus fall caudoventrally, to make an acute angle with the body, measuring 0.37 ± 0.006 cm in length and possessed lenticular process. The short root, which was 0.23 ± 0.005 cm in length, directed rostro-dorsally, to articulate with the body of the stapes via its terminal facet to form the incudostapedial joint.

Stapes was the smallest of the three ear ossicles. Topographically, it was located in between the terminal



Figs. 1 to 7. (1) Steps in reaching the middle ear to locate ear ossicles. (2) (A) Ossicular chain visible inside the middle ear cavity showing 1. Head of malleus 2. Chorda tympani nerve, 3. Long crus of incus; Arrow pointing to the malleoincudal joint. Yellow dotted area showing cut opened ventral surface of tympanic bulla; (B) Ear ossicles taken out of the middle ear, 1. Malleus, 2. Incus, and 3. Stapes; (C) method of taking morphometrical measurements by using verniercallipers. (3) Drawing of ear ossicles showing the landmarks for morphometrical parameters of A) Malleus, B) Incus, and C) Stapes. (4) Malleus of goat showing Malleus head showing the articular process (1), Rostral process (2), Tympanic membrane attached to manubrium of the malleus (3), Neck (4) and Manubrium/ handle of the malleus (5). (5) Incus of goat showing long process of incus (1), body of incus (2), short process of incus (3), articular facet for stapes (4), and medial depression (5). (6) Stapes of goat showing head (1), rostral crus (2), Obturator foramen (3), Footplate (4) and Caudal crus (5). (7) Graphical representation of average length (A) and width at the broadest point (B) of three ear ossicles and their statistical analysis.

Table 1. Morphometrical data on the malleus of beetal goat (in cms)

Parameter	Total length (cm)	Width at widest point (cm)	Vertical diameter (cm) of head	Thickness (cm) of the neck	Manubrium length (cm)
Mean \pm SE	0.885 \pm 0.009	0.24 \pm 0.002	0.33 \pm 0.009	0.21 \pm 0.005	0.46 \pm 0.009

Table 2. Morphometrical data on incus of beetal goat (in cms)

Parameter	length	Width	Length of long crus	Length of short crus
Mean \pm SE	0.29 \pm 0.002	0.35 \pm 0.006	0.37 \pm 0.006	0.23 \pm 0.005

Table 3. Morphometrical data on stapes of beetal goat (in cms)

Parameter	length	Width	Length of rostral crus	Length of caudal crus
Mean \pm SE	0.27 \pm 0.004	0.2 \pm 0.005	0.26 \pm 0.008	0.2 \pm 0.006

facet on the short crus of the incus and the vestibular or oval window connecting the middle ear to the inner ear (Figs. 6A, B). It was deeply excavated and could be found below the chorda tympani nerve branch of the facial nerve. It was placed in dorso-medially oblique orientation. The shape of stapes was like a triangle with a head (*Caput stapedis*), a rostral arm (*Crus rostralis*), a caudal arm (*Crus*

caudale) and a foot plate (*Basis stapedis*). The head of stapes contained an articular facet for incus. The caudal margin of the stapes showed a process for insertion of the stapedius muscle (*Membrana stapedius*). Between the two arms of stapes, it enclosed an oval space known as obturator/intercrural space. The base or footplate of the stapes was ellipsoid in shape, and its medial surface was

attached to an oval or vestibular window by means of an annular ligament (*Annularestapedis*). The Stapes in Beetal goats under present study had a similar shape to those in guinea pigs (Albuquerque *et al.*, 2009), degu and paca, hamsters (Mohammadpour, 2010), Chinese bamboo rats (Pleštilová *et al.*, 2016), and wolves (Gürbüz *et al.*, 2019). The morphometrical data of Stapes has been presented in Table 3. It measured 0.27 ± 0.004 cm in length and 0.2 ± 0.005 cm in width. The rostral crus measured 0.26 ± 0.008 cm in length and was concave, curved and longer than the caudal one. The caudal crus were convex and 0.2 ± 0.006 cm in length.

The data analysis of the length of the three ear ossicles (Fig. 7A) showed that Malleus was significantly longer than the other two ear ossicles ($P < 0.0001$). No significant difference in the length of Incus and Stapes was observed. The Incus was the widest ear ossicle and Stapes was the narrowest of the three (Fig. 7B). Our results regarding the length of the rostral crus being larger than the caudal crus correlated with earlier findings in goats (Tolba, 2016). On the contrary, the two roots were equal in length, according to (Osman & Arnautovic, 1987) in camel and donkey, in deer (Ragab and Osman, 1987), and in pig (Gurr *et al.*, 2010). An earlier study in goats (Martonos *et al.*, 2020) recorded the presence of a spicule on the caudal crus of stapes crossing onto the obturator/intercrural space, which was not found in our study.

CONCLUSION

This study's major goal was to present a detailed morphological description and some morphometrical information about the auditory ossicles in Beetal goats. Combining all the data in this way could be a great educational tool for studying the comparative morphology of the middle ear and suggest some fresh research areas.

REFERENCES

- Albuquerque, A.A., Rossato, M., Oliveira, J.A. and Hyppolito, M.A. (2009). Understanding the anatomy of ears from guinea pigs and rats and its use in basic otologic research. *Braz. J. Otorhinolaryngol.* **75**(1): 43-49.
- Amin, S. and Tucker, A.S. (2006). Joint formation in the middle ear : Lessons from the mouse and guinea pig. *Dev. Dyn.* **235**(5): 1326-1333.
- Anthwal, N., Joshi, L. and Tucker, A.S. (2013). Evolution of the mammalian middle ear and jaw: adaptations and novel structures. *J. Anat.* **222**(1): 147-160.
- Arnautovic, I. and Osman, F. (1985). Anatomical studies on the auditory ossicles of the cat and rabbit. *Assiut Vet. Med. J.* **15**: 51-56.
- Be°oluk, K., Dayan, M.O., Eken, E., Turgut, N. and Aydo°du, S. (2019). Macroanatomic structure and morphometric analysis of middle ear in Ostrich (*Struthio camelus*). *Arch. Vet. Sci. Med.* **2**(2): 8-16.
- Borin, A., Covolan, L., Eugênio, L., Okada, D.M., Laércio, O., Cruz, M., Ricardo, J. and Testa, G. (2008). Anatomical study of a temporal bone from a non-human primate (*Callithrix* sp). *Braz. J. Otorhinolaryngol.* **74**(3): 370-373.
- Claes, R., Muyshondt, P.G., Van Hoorebeke, L., Dhaene, J., Dirckx, J.J. and Aerts, P. (2017). The effect of craniokinesis on the middle ear of domestic chickens (*Gallus gallus domesticus*). *J. Anat.* **230**(3): 414-23.
- Guan, M., Zhang, J., Jia, Y., Cao, X., Lou, X., Li, Y. and Gao, X. (2019). Middle ear structure and transcanal approach appropriate for middle ear surgery in rabbits. *Exp. Ther. Med.* **17**(2): 1248-1255.
- Gürbüz, I., Demiraslan, Y., Dayan, M.O. and Aslan, K. (2019). Morphometric and macroanatomic examination of auditory ossicles in male wolves (*Canis lupus*). *Folia Morphol.* **78**(3): 600-605.
- Gurr, A., Stark, K.K.T. and Dazert, M.P.S. (2010). The common pig: a possible model for teaching ear surgery. *Eur. Arch. Oto-Rhino-Laryngol.* **267**: 213-217.
- Hadžiomerović, N., Gundemir, O., Tandir, F., Avdić, R. and Katica, M. (2023). Geometric and morphometric analysis of the auditory ossicles in the Red Fox (*Vulpes vulpes*). *Animals.* **13**(7): 1230.
- Hemilä, S., Nummela, S. and Reuter, T. (1995). What middle ear parameters tell about impedance matching and high frequency hearing. *Hear. Res.* **85**(1-2): 31-44.
- Keefe, D.H. (2015). Human middle-ear model with compound eardrum and airway branching in mastoid air cells. *J. Acoust. Soc. Am.* **137**(5): 2698-2725.
- Kurtul, I., Cevik, A., Bozkurt, E.U. and Dursun, N. (2003). A detailed subgross morphometric study on the auditory ossicles of the New Zealand rabbit. *Anat. Histol. Embryol.* **32**(4): 249-252.
- Ludman, H. and Wright, T. (2006). Diseases of the ear. (6th Edn.). Jaypee Brothers.
- Mills, R. (1994). Applied comparative anatomy of the avian middle ear. *J. R. Soc. Med.* **87**(3): 155-156.
- Mohammadpour, A.A. (2010). Morphological study of auditory ossicles in the mouse. *J. Appl. Anim. Res.* **37**(2): 269-271.
- Nazih, A.M. (2017). Anatomical study on the middle ear of donkey (*Equus asinus*). *Int. J. Adv. Res. Biol. Sci.* **4**(8): 110-121.
- Martonos, C.O., Gudea, A., Damian, A., Lăcătu', R., Purdoi, R., Cocan, D. and Stan, F.G. (2021). Morphological and morphometrical aspects of the auditory ossicles in goat (*Capra hircus*). *Anat. Histol. Embryol.* **50**(1): 184-191.
- Osman, F.A. and Arnautovic, I. (1987). Anatomical studies on the tympanic cavity and external acoustic meatus of one humped camel (*Camelus dromedarius*). *Assiut. Vet. Med. J.* **18**(36): 15-21.
- Pleštilová, L., Hrouzková, E., Burda, H. and Šumbera, R. (2016). Does the morphology of the ear of the Chinese bamboo rat (*Rhizomys sinensis*) show "Subterranean" characteristics? *J. Morphol.* **277**(5): 575-584.
- Ragab, S.A. and Osman, F. (1987) Anatomical study on the tympanic cavity of the buffalo (*Bos bulbalis* L.) Egypt. *J. Anat.* **10**(1): 29-41.
- Schnabl, J., Glueckert, R., Feuchtnet, G., Recheis, W., Potrusil, T., Kuhn, V., Wolf-Magele, A., Riechelmann, H. and Sprinzl, G.M. (2012). Sheep as a large animal model for middle and inner ear implantable hearing devices: a feasibility study in cadavers. *Otol. Neurotol.* **33**(3): 481-489.
- Simaei, N., Soltanilinejad, F., Najafi, G. and Shalazar Jalali, A. (2017). Anatomical and morphometrical study of middle ear ossicles in 2 to 3-month-old Makouei sheep fetuses. *Vet. Res. Forum.* **8**(3): 237.
- Standring, S. (2008). Gray's Anatomy (40th Edn.). Elsevier Churchill Livingstone. 623-652.
- Takechi, M. and Kuratani, S. (2010). History of studies on mammalian middle ear evolution: a comparative morphological and developmental biology perspective. *J. Exp. Zool. B: Mol. Dev. Evol.* **314**(6): 417-433.
- Tolba, A. (2016). Some anatomical studies on the tympanic cavity of the goat (*Capra aegagrus hircus*) with special reference to their ossicles. *Adv. Biol. Res.* **10**(6): 398-403.
- Wilson, J.P. (1987). Mechanics of middle and inner ear. *Br. Med. Bull.* **43**(4): 821-837.