

INCIDENCE OF CARDIAC DISEASES IN DOGS OF HILLY STATE OF HIMACHAL PRADESH

PARDEEP SHARMA*, ASHISH PALAHANIA, S.P. TYAGI¹ and DEEPTI BODH¹

Department of Veterinary Medicine, ¹Department of Veterinary Surgery & Radiology,

Dr. G.C. Negi College of Veterinary and Animal Sciences

CSK Himachal Pradesh Krishi Vishwavidyalaya Palampur, Himachal Pradesh-176062, India

Received: 10.02.2024; Accepted: 13.04.2024

ABSTRACT

Cardiac disease is the term used to describe any irregularity in the mechanical, electrical, functional, or anatomical aspects of the heart. Description of several canine cardiac diseases in details in hilly state of Himachal Pradesh, India has been least studied. Out of total 3166 dogs presented in campus of DGCN, COVAS, Palampur, H.P., fifteen dogs were diagnosed with cardiac disorders. These disorders were confirmed and categorized by electrocardiography, radiography, echocardiography, and cardiac biomarkers. Instat from Graphpad software, 2008 was used for the data analyses. The study inferred occurrence of Dilated Cardiomyopathy (DCM)-53.33%, Hypertrophic Cardiomyopathy (HCM)-13.33%, valvular diseases- 20% and Pericardial disease-13.30% with overall occurrence of cardiac disorders accounted to 0.47%. Breed wise occurrence of cardiac disease is as follows: Labrador (40%), German Shepard and Shih tzu (13.33% each), and Beagle, Pomeranian, Pug, Pointer, and Spitz (6.67% each). Geriatric (>8 years) and males (86.67%) were predominantly affected than females (13.33%). Mean cardiac troponin (cTnI) values were found significantly increased ($p < 0.05$) in overall cardiac diseases (0.21 ± 0.02 ng/dL). Thus, the study is concluded with the remark that cardiac diseases are mainly seen in the geriatric dogs presented in the referral veterinary clinic of Palampur and periodic screening of aged dogs is advised to provide better management.

Keywords: Cardiac troponin, Dilated cardiomyopathy, Echocardiography, Hypertrophic cardiomyopathy, Valvular diseases

How to cite: Sharma, P., Palahania, A., Tyagi, S.P. and Bodh, D. (2024). Incidence of cardiac diseases in dogs of hilly state of Himachal Pradesh. *The Haryana Veterinarian* 63(2): 172-177.

Canine cardiac diseases, a silent killer, are the most common cause of morbidity and mortality in dogs. According to American Veterinary Medical Association (AVMA), one in every 10 dogs suffers from cardiac disorders (Dove, 2001). Endocardiosis, pericardial diseases, cardiac neoplasia and dilated cardiomyopathy (DCM) are commonly acquired heart diseases of dogs which develop secondary to cardiac remodeling and are a common cause of mortality. Cardiac diseases are manifested by any of the following symptoms, including exercise intolerance, coughing, syncope, weight loss, and lethargy (Devi *et al.*, 2009).

Therefore, regular cardiac function testing is necessary for the early detection and treatment of cardiac irregularities, as any delay may result in a potentially fatal situation. Auscultation, electrocardiography, radiography, echocardiography and cardiac biomarkers tests are routinely used in the diagnosis of cardiac diseases. Extensive research on canine cardiac diseases has been carried out in the developed countries, few researchers in India have contributed to this area of study (Kumar *et al.*, 2016 and Deepti *et al.*, 2016), however, detailed research pertaining to dogs' heart problems is lacking in the hilly state of Himachal Pradesh. Due to increase in pet population, owner awareness and availability of advanced infrastructure facilities at the institutions, the current study was conducted to identify and describe various canine

cardiac conditions prevalent in the referral hospital of hilly state of Himachal Pradesh.

MATERIALS AND METHODS

The current investigation was carried out on dogs referred to the Department of Veterinary Medicine, DGCN COVAS, CSKHPKV, Palampur (H.P.) during the period of 17 months w.e.f. May 2021 to September 2022. Fifteen dogs out of the total 3166 cases presented were found to have cardiac problems. Preliminary screening showed coughing, exercise intolerance, respiratory distress, cyanosis, lethargy and ascites as main clinical signs. These ailing dogs underwent to a comprehensive investigative regimen that included physical examinations, auscultatory evaluations, electrocardiographic, radiographic and echocardiography assessment for disease confirmation. The electrocardiography was done using RMS Vista 301i®. ECG was recorded @ 50 mm/s and 25 mm/s speed in all six leads and measurements were recorded using lead II. Thoracic radiographs were taken using a Siemens 80mA mobile X-ray machine® for the radiographic parameters and images were analyzed through a computed radiography system. For echocardiography Siemens Accustom X 300® ultrasound machine with multifrequency (3.5-7MHz) P-8 phase array probe was used. For performing echo, all dogs were clipped over the area between 2nd to 6th intercostal space on both right and left sides. The patients were placed in right and left lateral recumbency on a specially designed table that had a “V-shaped” cut on the tabletop. Systolic

*Corresponding author: docpradeepsharma@gmail.com

blood pressure measurement was carried out using JNR DS-100 Doppler Blood Pressure Meter® and for the cardiac biomarker estimation the quantitative measurement of cardiac troponin-I levels was measured using iChroma II scanning instrument® and iChroma cTnI immunoassay kits, respectively. The computer software Instat from Graphpad, 2008 was used for the data analyses.

RESULTS AND DISCUSSION

The trend of cardiac disorders in dogs from May 2021 to September 2022 in the campus of DGCN, COVAS, CSKHPKV, Palampur (H.P.) observed that heart problems affected 0.47% of the reported cases which was ruled out based on electrocardiography, radiography and echocardiography. The occurrence of cardiac diseases was as follows- Group-I- Dilated Cardiomyopathy (n=8, 53.33%), Group-II- Hypertrophic Cardiomyopathy (n=2, 13.33%), Group-III- valvular diseases (n=3, 20.00%) and Group-IV- pericardial disease (n=2, 13.33%). These results were in line with a study conducted by Deepti (2016), in which 78 dogs suffering with congestive heart failure (CHF) had mitral valve disease in 24% (n=19) and dilated cardiomyopathy in 76% (n=59). Rush (2002) in their study has also reported DCM as the most common type of acquired heart disease in dogs.

Breed wise distribution revealed that Labrador Retrievers was the most predisposed (n=6, 40.00%) followed by German Shepherds (n=2, 13.33%), Shih Tzus (n=2, 13.33%), and then Beagles, Pomeranians, Pugs, Pointers, and Spitz (6.67% each). Calvert and Wall (2001) also reported similar breeds as Labradors, Pugs and Spitz are affected with cardiac problems in their study. Given that just a tiny percentage of the cases of cardiac disease in our study were confirmed, it's possible that some breeds are disproportionately represented. To confirm these findings, larger sample sizes should be examined in the next research. In the present study, out of eight dogs with DCM, six were Labradors, and one each was Beagle and Pug. One German Shepherd and one Shih Tzu were diagnosed with HCM, whereas MMVD was diagnosed in a Pomeranian, a Pointer, and a Spitz. Pericardial disease was reported in one German Shepherd and one Shih Tzu dog in our study. Similarly, Borgarelli *et al.* (2004) and Haggstrom *et al.* (2004) also stated that small breeds were more predisposed to mitral valve disease. Labrador retriever predominance for cardiac problems in this study could be because it was owned by most of the people in current study area, and inbreeding of susceptible breed lines could be the other reason.

Age wise occurrence of cardiac disease was divided into three age groups i.e., <2 years (n=3, 20%), 2-8 years

age (n=6, 40%) and >8 years age (n=6, 40%). Out of eight dogs suffering from DCM, three were < 2 years, three were between 2-8 years age and two dogs were > 8 years age. According to Sisson and Thomas (1995) juvenile DCM may be caused by autosomal recessive pattern of inheritance. In the present study, one case of HCM was in the group of 2-8 years and the other one was > 8 years age. Kumar *et al.* (2010) reported 10-13 years age group was the most presented for HCM and was in accordance with our findings. Out of three dogs diagnosed with valvular disease in our study, one was in the 2-8 years age group and two were more than 8 years of age. Sisson and Thomas (1995) also found an increased prevalence of MMVD in elderly dogs. In pericardial disease group, one dog was in the 2-8 years age group and one was > 8 years age. Petric *et al.* (2002) reported 3-12 years of age dogs are commonly prone for pericardial effusions.

Gender wise occurrence of canine cardiac diseases revealed that males were predominantly affected with cardiac diseases (n=13, 86.67 %) than females (n=2, 13.33%). Similar gender ratio and male predominance was also stated by Serfass *et al.* (2006). In DCM cases, six were males and two were females, DCM affected more males than females which was similar with the findings of Schober *et al.* (2010). Kumar (2010) reported that males are more affected by HCM than females. Atkin *et al.* (2009) stated males were 1.5 times more affected with chronic valvular heart disease than female dogs. These events of cardiac disorders are more likely due to over-presentation of male dog by the owners which could be because pet owners tend to keep more male dogs than female dogs.

Electrocardiographic waveform parameters of overall cardiac diseases did not show significant changes (Table 1). The mean values of all the ECG parameters of healthy group were within normal range as per standard range described by Tilley and Smith (2015). The ECG findings revealed that in DCM cases, P (sec) (P mitrale- Left atrial enlargement) was significantly increased ($p<0.01$) with respect to control groups. In DCM, the atrium is frequently dilated, which has been linked to elevated filling pressures or valve anomalies. Dogs with bilateral DCM showed taller P wave indicating right atrial enlargement. The dogs affected with rigorous left atrial dilatation in dilated cardiomyopathy led to atrial fibrillation (Saikrishna *et al.*, 2022). Fig. 1 shows atrial fibrillation with electrical alternans in a dog diagnosed with dilated cardiomyopathy.

In HCM cases, P (mV) (P pulmonale- right atrial abnormality) was significantly increased ($p<0.01$) with

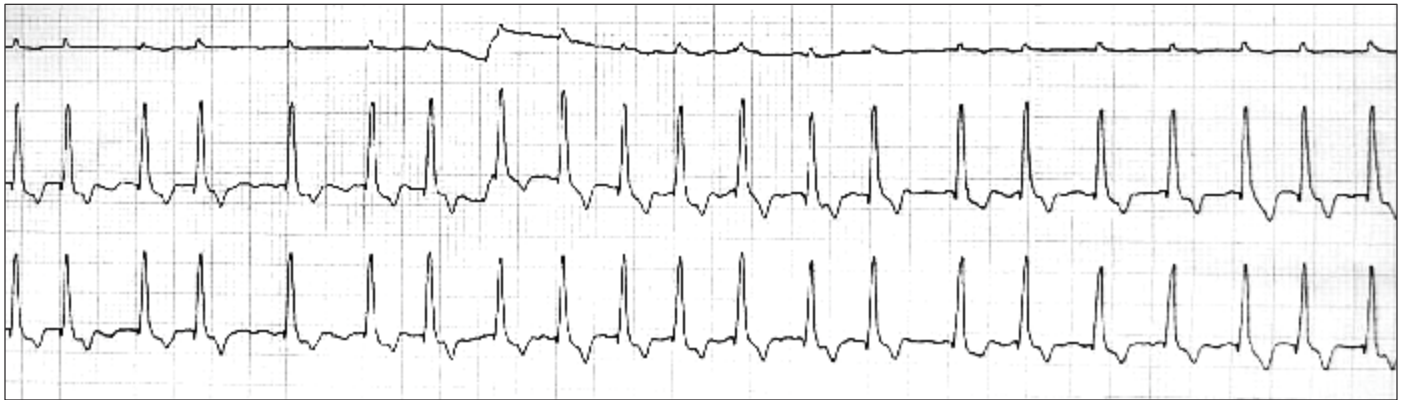

Fig. 1. ECG showing Atrial fibrillation with electrical alternans in a dog with DCM

Radiographic findings in various cardiac diseases

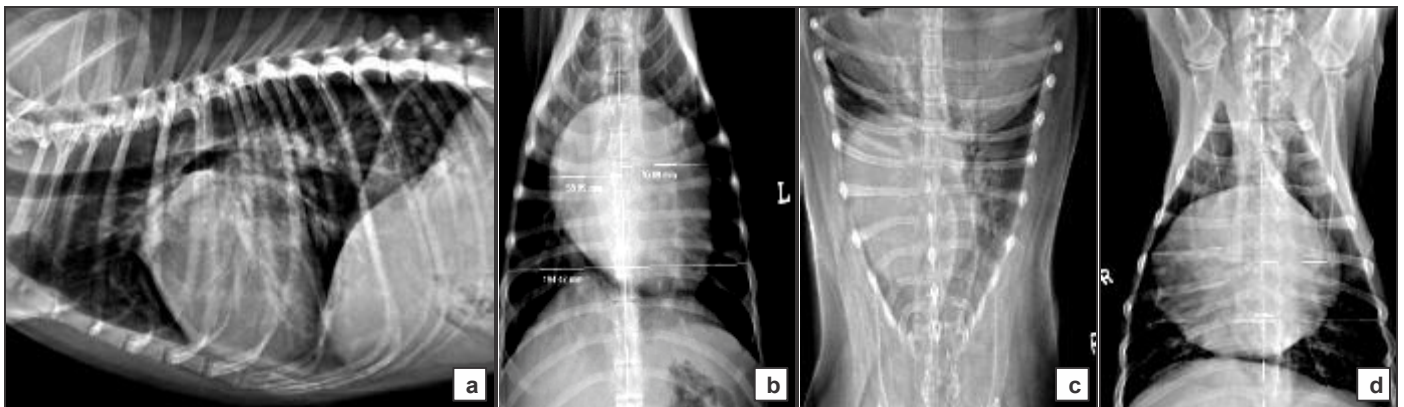


Fig. 1. (a) CXR- Lateral showing tracheal elevation and left atrial enlargement causing main bronchus compression. (b) CXR- VD showing bulging at 2 O'clock and 10 O'clock indicating left sided cardiomegaly; (c) CXR- VD showing left sided enlargement and alveolar signs (Pulmonary edema) on right side in a dog with MMVD; (d) CXR-VD showing demarcated generalized cardiomegaly (Globoid heart) appearance due to PE in GSD.

Echocardiographic findings in various cardiac diseases

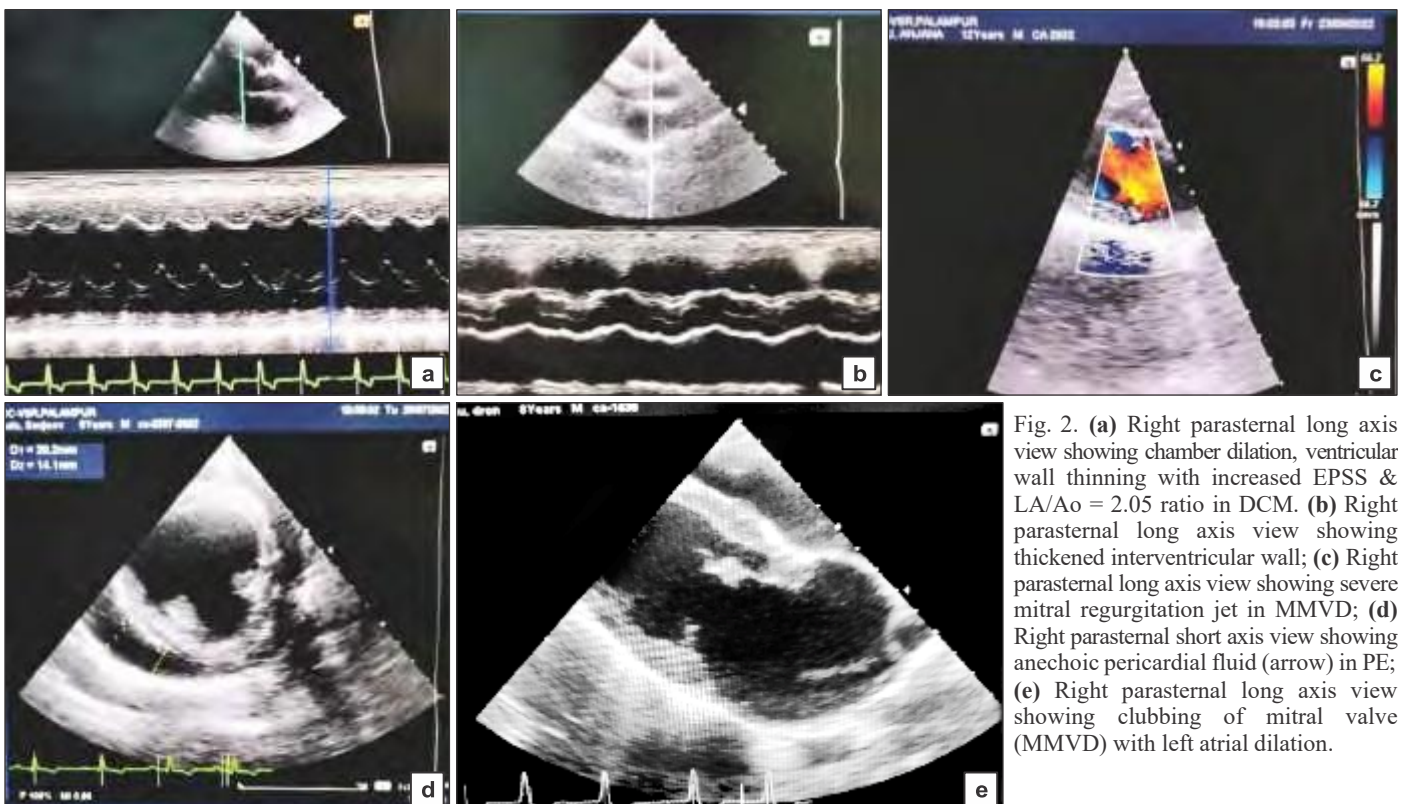


Fig. 2. (a) Right parasternal long axis view showing chamber dilation, ventricular wall thinning with increased EPSS & LA/Ao = 2.05 ratio in DCM. (b) Right parasternal long axis view showing thickened interventricular wall; (c) Right parasternal long axis view showing severe mitral regurgitation jet in MMVD; (d) Right parasternal short axis view showing anechoic pericardial fluid (arrow) in PE; (e) Right parasternal long axis view showing clubbing of mitral valve (MMVD) with left atrial dilation.

Table 1. Electrocardiographic findings in cardiac diseases

Arrhythmias	Cardiac Disease									
	DCM (n=8)		HCM (n=2)		Valvular disease (n=3)		Pericardiac effusion (n=2)		Total (n=15)	
	Cases	%	Cases	%	Cases	%	Cases	%	Cases	%
ST depression	2	25.00%	0	0.00%	0	0.00%	1	50.00%	3	20.00%
Atrial fibrillation	3	37.50%	0	0.00%	0	0.00%	0	0.00%	3	20.00%
P mitrale	2	25.00%	1	50.00%	0	0.00%	0	0.00%	3	20.00%
↑QRS amplitude	2	25.00%	1	50.00%	0	0.00%	0	0.00%	3	20.00%
↑QRS duration	5	62.50%	1	50.00%	1	33.33%	0	0.00%	7	46.67%
Low QRS complexes	0	0.00%	0	0.00%	0	0.00%	2	100.00%	2	13.33%
VPCs	2	25.00%	0	0.00%	0	0.00%	0	0.00%	2	13.33%
Electrical alternans	3	37.50%	0	0.00%	0	0.00%	2	100%	5	33.33%
Deep Q wave	1	12.50%	1	50.00%	0	0.00%	0	0.00%	2	13.33%
AV blocks	2	25.00%	0	0.00%	0	0.00%	0	0.00%	2	13.33%
RBBB	1	12.50%	0	0.00%	0	0.00%	0	0.00%	1	6.66%

Table 2. Radiographic findings in cardiac diseases

Radiographic Findings	Cardiac Disease									
			Hypertrophic Cardiomyopathy (N=2)		Valvular Disease (N=3)		Pericardial Effusion (N=2)		Total (N=15)	
	Cases	%	Cases	%	Cases	%	Cases	%	Cases	%
Tracheal elevation	6	75 %	1	50 %	2	66.67%	2	100 %	11	73.33%
Pulmonary edema	5	62.50%	1	50 %	1	33.33%	-	-	7	46.67%
Pleural effusion	-	-	2	100%	-	-	-	-	2	13.33%
Main bronchus compression	6	75 %	-	-	3	100 %	2	100 %	11	73.33%
Left atrial enlargement	7	87.50%	-	-	2	66.67%	1	50 %	10	66.67%
Pulmonary vessels dilation	4	50 %	2	100 %	1	33.33%	-	-	7	46.67%
Cardiomegaly	8	100 %	-	-	3	100 %	2	100 %	13	86.67%

respect to control group. Increased QRS duration, electrical alternans, atrial fibrillation, ST depression, P mitrale, VPCs and right bundle branch block and deep Q wave was other statistical nonsignificant ECG findings seen in cardiac disorders cases. The expanded width and rise in amplitude of QRS complexes - implied left ventricular enlargement. The two primary functional problems in individuals with hypertrophic cardiomyopathy are left ventricular outflow tract (LVOT) blockage and poor diastolic filling (Maron *et al.*, 1987). Low QRS complexes, ST depression and electrical alternans were the ECG findings seen in pericardial effusion cases. Electrical alternance, which is commonly observed in malignant reasons such as metastatic lung cancer is induced by the mechanical anterior-posterior movement of the heart in the significant fluid.

The systolic blood pressure values increased non-significantly in all four groups as compared to control groups as the following in mmHg: DCM 144 ± 12.6 , HCM

154 ± 21.5 , valvular disease 126 ± 17.5 and pericardial effusion 103 ± 24.6 mm of Hg. Bodey and Michell (1996) stated that systolic blood pressure was the most variable metric; and is influenced by age, breed, sex, temperament, disease severity, exercise routine and to a slight extent on the eating habits.

Radiographic findings in dogs suffering from cardiac diseases are presented in Table 2. In cases of DCM, radiographic cardiomegaly, main bronchus compression, tracheal elevation and pulmonary edema was observed (Fig. 1a) and was similar to the findings of various researchers (Dunn *et al.*, 1999 and Vollmar (2000). Main bronchus compression and radiographic cardiomegaly were the most common findings in valvular disease and were followed by tracheal elevation and left atrial enlargement (Fig. 1b & 1c). The dogs with valvular disease had elevated VHS, which might be due to dilation of all chambers in valvular disease. These findings coincide with the observations of Lister and Buchanan (2000). In pericardial effusion (PE) like

earlier report (Vollmar, 2000) bronchus compression, radiographic cardiomegaly (globoid heart) and tracheal elevation were seen (Fig. 1d). The enlarged and globoid cardiac silhouette was a result of fluid-filled pericardial sac distention (Shaw and Rush 2007).

The cardiac biomarker (cTnI) value significantly increased ($p < 0.05$) in overall cardiac diseases (0.21 ± 0.02 ng/mL) and in the valvular disease group (0.21 ± 0.04 ng/mL) in comparison to the control group. However, the value of cTnI increased non-significantly in DCM (0.20 ± 0.03 ng/mL), HCM (0.20 ± 0.04 ng/mL) and pericardial effusion (0.19 ± 0.03 ng/mL). The most sensitive and specific marker of myocardial cell necrosis is cardiac troponin I, which has been shown to have a greater degree of specificity than the cardiac isoenzyme creatine kinase (CK-MB) and greater sensitivity and specificity to cardiac troponin T (Adams *et al.*, 1993).

Echocardiographic findings in DCM cases revealed increased left ventricular and left atrial chamber dilation with thinning of left ventricular posterior wall, which were confirmed by B-mode examination. Fig. 2a represents a right parasternal long axis view indicating chamber dilation, ventricular wall thinning with increased E point-septal separation (EPSS) & left atrial to aortic root ratio (LA/Ao) in DCM affected dog. Two dogs with HCM showed thickened interventricular septum and thickened left ventricular posterior wall (Fig. 2b) which could be because of an excess of pressure and larger heart chambers. All three dogs with valvular disease showed an abnormally thickened mitral valve morphology with mitral regurgitation jet in color doppler (Fig. 2c and 2d). According to Tidholm *et al.* (2001) echocardiography can determine a patient with MVD if they have mitral regurgitation and enlarged left atrium and ventricle. According to Belanger (2010), the mitral valve does not reach the septum in dilated hearts when there is decreased contractility such as in DCM. The most prevalent form of acquired cardiac illness in small dogs is mitral valve disease, which is marked by valvular degeneration ultimately resulting in systolic mitral regurgitation (Praveen *et al.*, 2012). All dogs suffering from pericardial effusion showed echo free space separating parietal pericardium and epicardium, both had cardiac tamponade with right atrial collapse or diastolic compression (Fig. 2e). Odeja (2015) also observed diastolic collapse of the ventricles and right atrium, as well as cardiac tamponade, in cases of pericardial effusion.

In conclusion echocardiography is one of the most vital diagnostic tools in Veterinary cardiology, it is noninvasive and gives the operator a clear understanding of the cardiac picture for further diagnosis and categorization. Our findings

indicated that older dogs (over 8 years) were more susceptible to developing various cardiac abnormalities. As a result, it is recommended to screen older dogs on a periodic basis for indication of any cardiac modalities. This will enable early diagnosis, intervention and treatment, as well as better management of canine cardiac disorders that enhances quality of life.

REFERENCES

- Adams, J.E., Bodor, G.S., Davila-Roman, V.G., Delmez, J.A., Apple, F.S., Ladenson, J.H. and Jaffe, A.S. (1993). Cardiac troponin I: A marker with high specificity for cardiac injury. *Circulation*. **88**: 101-106.
- Atkin, C., Bonagura, J., Ettinger, S., Fox, P., Gordon, S., Haggstrom, J., Hamlin, R., Keene, B., Luis-Fuentes, V. and Stepien, R. (2009). Guidelines for the diagnosis and treatment of canine chronic valvular heart disease. *J. Vet. Intern. Med.* **23**: 1142-1150.
- Belanger, M. (2010). Echocardiography. In: Textbook of Veterinary Internal Medicine. (7th Edn.) Ettinger, S.E. and Feldman, F.C. (Edts.). W.B. Saunders Co., Philadelphia, PA, USA, 297-310.
- Bodey, A.R. and Michell, A.R. (1996). Epidemiological study of blood pressure in domestic dogs. *J. Small Anim. Pract.* **37**(3): 116-25.
- Borgarelli, M., Zini, E., Agnolo, G.D., Tarducci, A., Santilli, R.A., David, C., Turducci, M., Prunotto, M. and Haggstrom, J. (2004). Comparison of primary mitral valve disease in German shepherd dogs and in small bird. *J. Vet. Cardiol.* **6**: 27-34.
- Calvert, C.A. and Wall, M. (2001). Effect of severity of myocardial failure on heart rate variability in Doberman Pinschers with and without echocardiographic evidence of dilated cardiomyopathy. *J. Am. Vet. Med. Assoc.* **219**(8): 1084-1088.
- Deepti, B.R., Yathiraj, S., Ramesh, P.T., Ranganath, L. and Narayanaswamy, H.D. (2016). Diagnosis and treatment of congestive heart failure in canines. *Intas Polivet.* **17**(1): 129-31.
- Devi, S., Jani, R.G., Karlette, A.F. and Singh, R.D. (2009). Study on clinical symptoms in canine cardiac diseases. *Vet. World.* **1**: 2(8).
- Dove, R.S. (2001). Nutritional therapy in the treatment of heart disease in dogs. *Altern. Med. Rev.* **6**: S38-45.
- Dunn, J.K., Elliott, J. and Heritage, M.E. (1999). Diseases of the cardiovascular system. In: Textbook of Small Animal Medicine. Dunn, J.K. (Edt.). W.B. Saunders Philadelphia pp. 256- 288.
- Haggstrom, J., Pedersen, H.D. and Kvart, C. (2004). New insights into degenerative mitral valve disease in dogs. *Vet. Clin. North Am.* **34**: 1209-1226.
- Kumar, K.S., Nagaraj, P., Kumar, V.V.A. and Rao, D.S.T. (2010). Hypertrophic cardiomyopathy in 12 dogs (2004-2008): First report in India. *Vet. Arh.* **80**: 491-498.
- Kumar, K.S., Srikala, D., Ayodhya, S. and Kumar, V.V. (2016). Diagnosis and management of heart failure in dogs- a clinical study. *Intas Polivet.* **17**(1): 121-8.
- Lister, A.L. and Buchanan, J.W. (2000). Vertebral scale system to measure heart size in radiographs of cats. *J. Am. Vet. Med. Assoc.* **216**(2): 210-4.
- Maron, B.J., Bonow, R.O., Cannon, R.O., Leon, M.B. and Epstein, S.E. (1987). Hypertrophic cardiomyopathy. Interrelations of clinical manifestations, pathophysiology and therapy (1). *N. Engl. J. Med.* **316**: 780-789.

- Odeja, J., Mieres, M., Durnier, C. and Bustamante, H. (2015). Pericardial effusion and cardiac tamponade in a dog with hypothyroidism. *Arch. Med. Vet.* **47**(3): 391-394.
- Petric, A.D., Stabej, P. and Zemva, A. (2002). Dilated cardiomyopathy in Doberman Pinschers: Survival, causes of death and a pedigree review in a related line. *J. Vet. Cardiol.* **4**: 17-24.
- Praveen, K, Chandolia, R.K., Chawla, S.K. and Sandeep, K. (2012). Chronic valvular heart disease in geriatric dogs: an echocardiographic study. *Indian J. Vet. Surg.* **33**: 143-145.
- Rush, J.E. (2002). Chronic valvular heart disease in dogs. Paper published in proceedings of 26th Annual Waltham Diets/Symposium for the Treatment of Small Animal Cardiology held at The Ohio State University. pp. 1-7.
- Saikrishna, K.S., Jeyaraja, K., Vairamuthu, S., Shafiuzama, Md. and Selvaraj, P. (2022). Electrocardiographic abnormalities in canine dilated cardiomyopathy and their management. *Indian J. Vet. Sci. Biotechnol.* **18**(5): 63-67.
- Schober, K.E., Hart, T.M., Stern, J.A., Li.X., Samii, V.F., Zekas, L.J., Scansen, B.A. and Bonagura, J.D. (2010). Detection of congestive heart failure in dogs by doppler echocardiography. *J. Vet. Intern. Med.* **24**: 1358-1368.
- Serfass, P., Chetbul, V., Sampedrano, C.C., Nicolle, A., Benalloul, T., Laforge, H., Gau, T., Herbt, C., Pouchelon, J. and Tissier, R. (2006). Retrospective study of 942 small sized dogs: Prevalence of left apical systolic heart murmur and left sided heart failure, critical effects of breed and sex. *J. Vet. Cardiol.* **8**: 11-18.
- Shaw, S.P. and Rush, J.E. (2007). Canine pericardial effusion: Pathophysiology and cause. *Compendium continuing education for practicing veterinarian.* **29**: 400-403.
- Sisson, D.D. and Thomas, W.P. (1995). Myocardial diseases, the prevalence of dilated cardiomyopathy. In: *Textbook of Veterinary Internal Medicine.* (4th Edn.) Ettinger, S.J. and Feldman, E.C. (Edts.). W.B. Saunders Co., Philadelphia, PA, USA, p. 995.
- Tidholm, A., Haggstrom, J., Borgarelli, M. and Tarducci, A. (2001). Canine idiopathic dilated cardiomyopathy. Part I: Aetiology, clinical characteristics, epidemiology and pathology. *Vet. J.* **62**: 92-107.
- Tilley, L.P., and Smith, Jr. F.W.K., (2015). Electrocardiography. In: *Manual of Canine and Feline Cardiology.* (5th Edn.) Tilley L.P., Smith F.W.K., Jr., Oyama M.O. and Sleeper M.M. (Edts.) Saunders, Saunders (Elsevier) Saint Louis, Missouri. USA, pp. 49-77.
- Vollmar, A.C. (2000). The prevalence of cardiomyopathy in the Irish Wolfhound: A clinical study of 500 dogs. *J. Am. Anim. Hosp. Assoc.* **36**: 125-132.

CONTRIBUTORS MAY NOTE

- Research/Clinical articles are invited for next issue from the Scientists/Veterinarians engaged in Veterinary Profession.
- Please follow strictly the format of 'The Haryana Veterinarian' for manuscript writing/submission.
- Please pay processing fee of Rs. 1200/- online in the account of Dean, College of Veterinary Sciences, along with each article.
- After revision, please return the revised manuscript and rebuttal at the earliest.
- Please mention your article reference number in all correspondence for a quick response.
- We solicit your co-operation.
- All correspondence should be addressed to 'The Editor', Haryana Veterinarian, Department of Veterinary Parasitology, College of Veterinary Sciences, LUVAS, Hisar-125004.

Editors