

AZOOSPERMIA DUE TO RETROGRADE EJACULATION IN A PUG AND ITS MANAGEMENTS. SATHISHKUMAR, N. ARUNMOZHI¹*, T. SARATH² and P. SRIDEVI

Department of Veterinary Gynaecology and Obstetrics, Madras Veterinary College, TANUVAS, Chennai-600007

¹Veterinary Clinical Complex, Veterinary College and Research Institute, Orathanadu, Thanjavur-614 625²Veterinary Clinical Complex, Veterinary College and Research Institute, Thalaivasal V. Koot Road, Salem-636 112

Received: 27.08.2023; Accepted: 17.11.2023

SUMMARY

A 5-year-old pug was presented to Madras Veterinary College Teaching Hospital with a history of having failed to sire litters following mating with different females. Semen collection attempted thrice by digital palpation at weekly intervals resulted in oligospermic ejaculates. Physical examination carried out to localize the cause for oligospermia appeared to be normal. Post semen collection, urine sample on microscopic examination revealed the presence of high concentration of sperm, confirming retrograde ejaculation as the cause for aspermia.

Keywords: Retrograde ejaculation, Aspermia, Phenylpropanolamine

How to cite: Sathishkumar, S., Arunmozhi, N., Sarath, T. and Sridevi, P. (2024). Azoospermia due to retrograde ejaculation in a pug and its management. *The Haryana Veterinarian* 63(2): 285-287.

Retrograde ejaculation is an ejaculatory mechanism dysfunction wherein there is retrograde flow of the majority of or all the semen into the bladder, resulting in no semen (aspermia) or minute quantities of semen (oligospermia) ejaculated antegrade (Collins, 1982; Yavetz *et al.*, 1994). A retrograde flow of small quantities of spermatozoa into the bladder is a normal event. This may occur during ejaculation or sexual rest and has been documented in many species, including the bull, ram, cat, dog, and human. However, fertility may be affected when this amount becomes too high. A variety of drugs have been used to treat retrograde ejaculation. Phenylpropanolamine (PPA), often known as norephedrine, is a regularly used medication (Dooley *et al.*, 1990).

A 5-year-old pug was presented to Madras Veterinary College Teaching Hospital with the history of having failed to sire litters following mating with different females. The male dog had no history of illness or trauma or drug therapy. On clinical examination, the animal was active and alert, temperature, H/R, R/R and CRT were within the normal range. On external genitalia examination, both the testes were descended with normal size and consistency. Haematological and biochemistry values were found to be normal. Semen collection by digital manipulation was carried out thrice at weekly intervals. In all the attempts, the erection and pelvic thrusting were good but only an oligospermic ejaculate (< 0.2 to 0.3 ml total volume) could be obtained. Based on the observations and laboratory findings the case was suspected for retrograde ejaculation.

In retrograde ejaculation, the back flow of semen into the bladder occurs during ejaculation and hence urine in the bladder may contain large quantities of spermatozoa.

Spermatozoa may also be present in the bladder of dogs, after a period of sexual rest (Dooley *et al.*, 1990). Hence, the bladder was catheterized (Fig. 1) before semen collection to rule out the presence of spermatozoa in the bladder due to sexual rest. Urine collected before semen collection was straw yellow in colour and no sperm were present. Post semen collection, the urine sample collected by catheterization appeared to be cloudy which on microscopic examination revealed the presence of sperm (Fig. 2), confirming retrograde ejaculation.

The dog was treated with the sympathomimetic drug phenylpropanolamine (PRION chewable tablet Virbac) 4-8 mg/kg PO once daily for seven days. Semen samples collected two days after the treatment schedule appeared normospermic (Fig. 3) confirming successful treatment.

Retrograde ejaculation may be due to congenital or acquired abnormalities of the bladder neck (Crich and Jequier, 1978) resulting in partial or total expulsion of semen into the bladder leading to oligospermia and aspermia, respectively. This may be due to insufficiency of the bladder sphincter caused by malfunction of sympathetic innervation to the bladder or posterior urethra which might be idiopathic or due to trauma, inflammation, or senescence (Sandler, 1979).

Normally ejaculation (Antegrade ejaculation) happens in three sequential events *viz.*, seminal emission, bladder neck closure, and seminal expulsion through the penile urethra. During emission, the sympathetic stimulation causes active contractions of the epididymis and ductus deferens, leading to the pumping of sperm cells from the epididymis and seminal fluid into the prostatic urethra. (Lipshultz *et al.*, 1981; Dyce *et al.*, 1987). Sympathetic stimulation also will lead to contraction of the

*Corresponding author: drarunmozhi@gmail.com

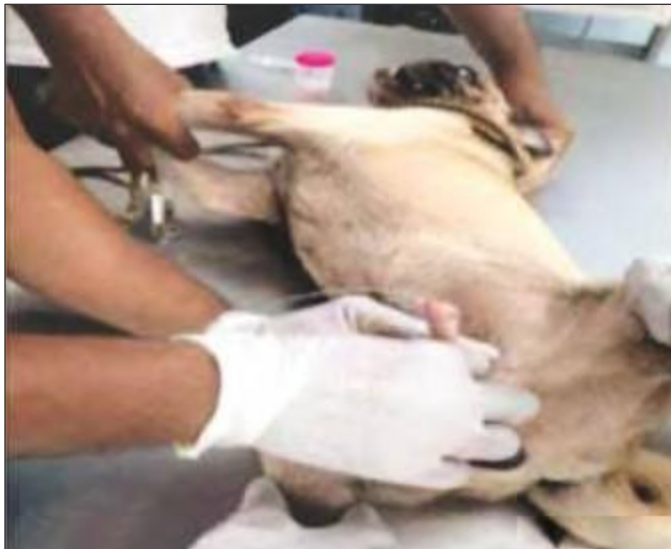

Fig. 1. Catheterisation of the bladder to collect urine

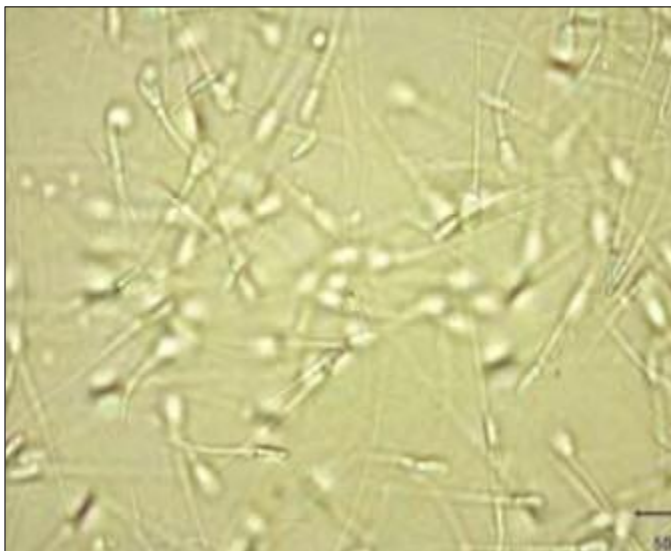


Fig. 3. Normospermic semen picture after treatment

internal sphincter muscle, resulting in partial closure of the bladder neck (Stabenfeldt *et al.*, 1984). A pressure chamber within the urethra is formed favouring the firing of parasympathetic fibers to stimulate complete closure of the bladder neck, and contractions of the prostate.

At last, somatic nerves will get stimulated and cause clonic contractions of the striated muscles of the penis. This somatic innervation by the pudendal nerve controls the contraction of the striated bulbocavernosus and ischiocavernosus muscles which encircle the entire length of the penile urethra and the musculature of the pelvic floor, leading to seminal expulsion (Newman *et al.*, 1982).

Retrograde ejaculation will result if denervation or damage to the nerves or muscle in this system prevents this sequence of events. As the pressure chamber forms within the prostatic urethra during emission, if inadequate closure of the bladder neck exists, it will lead to the flow of semen

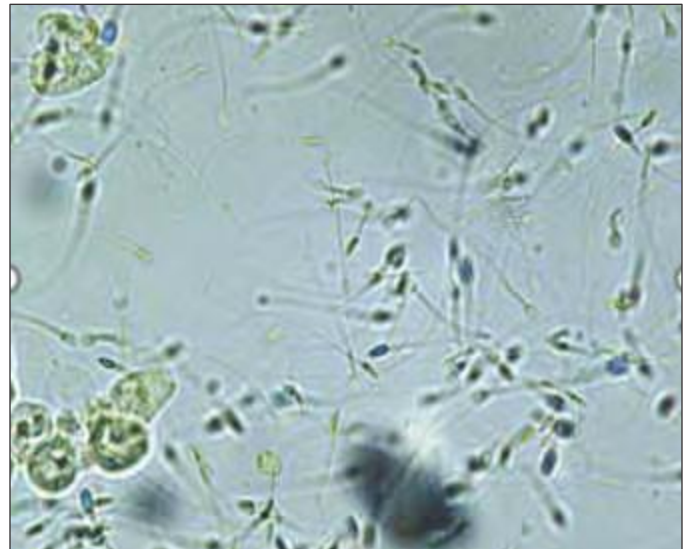


Fig. 2. Urine with presence of sperms

into the urinary bladder which is the path of least resistance. In the present case, the dog has been treated with phenylpropanolamine which is a sympathomimetic agent that stimulates the alpha 1 receptor and increases the urethral tone promoting closure of the bladder sphincter by stimulation of sympathetic fibers in the hypogastric nerves. This allows a normal sequence of events resulting in antegrade ejaculation.

This result is in agreement with Carofifiglio *et al.* (2006) and Beaufays *et al.* (2008), who have also reported that phenylpropanolamine, when administered orally, has increased maximum urethral closure pressure and reduced the number of sperms voided into the bladder during ejaculation. Post *et al.* (1992) have reported that phenylpropanolamine treatment was not effective in promoting retrograde ejaculation in dogs and this might be due to the owner's reluctance in continuing the drug therapy due to drug-induced bradycardia. The drug-induced bradycardia is to compensate for the increase in arterial pressure and has no adverse effect in dogs when used at the recommended dose (Noel *et al.*, 2012).

To conclude, phenylpropanolamine (sympathomimetic agent) @ 4-8 mg/kg PO once daily for seven days can be used successfully to treat retrograde ejaculation in dogs without any adverse effects.

REFERENCES

- Beaufays, F., Onclin, K. and Verstegen, J. (2008). Retrograde ejaculation occurs in the dog, but can be prevented by pre-treatment with phenylpropanolamine: A urodynamic study. *Theriogenology*. **70**(7): 1057-1064.
- Carofifiglio, F., Hamaide, A., Farnir, F., Balligand, M. and Verstegen, J.P. (2006). Evaluation of the urodynamic and hemodynamic effects of orally administered phenylpropanolamine and ephedrine in female dogs. *Am. J. Vet. Res.* **67**: 723-30.
- Collins, J.P. (1982). Retrograde ejaculation. In: Treatment of male

- infertility. Bain, J., Schill, W.B., Schwartzstein, L. (Edt.). New York: Springer Verlag. pp. 179-89.
- Crich, J.P. and Jequier, A.M. (1978). Infertility in men with retrograde ejaculation: the action of urine on sperm motility, and a simple method for achieving antegrade ejaculation. *Fertil. Steril.* **30**: 572-576.
- Dooley, M.P., Pineda, M.H., Hopper, J.G. and Hsu, W.H. (1990). Retrograde flow of spermatozoa into the urinary bladder of dogs during ejaculation or after sedation with xylazine. *Am. J. Vet. Res.* **51**: 1574-9.
- Dyce, K.M., Sack, W.O. and Wensing, C.J.G. (1987). Textbook of Veterinary Anatomy, WB Saunders. **192**: 322-327.
- Lipshultz, L.I., McConnell, J. and Benson, G.S. (1981). Current concepts of the mechanisms of ejaculation. Normal and abnormal states. *J. Reprod. Med.* **26(10)**: 499-507.
- Newman, H.F., Reiss, H. and Northup, J.D. (1982). Physical basis of emission, ejaculation, and orgasm in the male. *Urology.* **19(4)**: 341-350.
- Noel, S., Laurent, M., Hamaide, A. (2012). Urodynamic and haemodynamic effects of a single oral administration of ephedrine or phenylpropanolamine in continent female dogs. *Vet. J.* **192(1)**: 89-95.
- Post, K., Barth, A.D., Kiefer, U.T. and Mapletoft, R.J. (1992). Retrograde ejaculation in a Shetland sheepdog. *Canadian Vet. J.* **33(1)**: 53.
- Sandler, B. (1979). Idiopathic retrograde ejaculation. *Fertil. Steril.* **32**: 474-475.
- Stabenfeldt, G.H., Edqvist, L.E. (1984). Male reproductive processes. In: Duke's Physiology of Domestic Animals. Swenson, M.J. (Edt.), Cornell University Press, Ithaca, NY. pp. 833-846.
- Yavetz, H., Yogeve, L., Lessing, J.B., Paz, G. and Hommonnai, Z.T. (1994). Retrograde ejaculation. *Hum. Reprod.* **9**: 381-6.

THE HARYANA VETERINARIAN

Editors/Editorial Board Members are highly thankful to all the distinguished referees who helped us in the evaluation of articles. We request them to continue to extend their co-operation and be prompt in future to give their valuable comments on the articles for timely publication of the journal.