

HISTO- ARCHITECTURAL CHANGES IN THE JEJUNUM OF GUINEA PIG IN POSTNATAL AGE GROUPS

K. RAJA*, S. USHAKUMARY¹, S. RAJATHI², GEETHA RAMESH¹, S. RAMESH³, K. KUMAR¹ and N. HEMAVATHI¹

Department of Veterinary Anatomy, College of Veterinary Science, Tirupati, SVVU (A.P.)

¹Department of Veterinary Anatomy, ³Department of Veterinary Pharmacology and Toxicology, Madras Veterinary College, Chennai, TANUVAS, Tamil Nadu

²Department of Veterinary Anatomy, Veterinary College and Research Institute, Tirunelveli, TANUVAS, Tamil Nadu

Received: 13.02.2023; Accepted: 23.06.2023

SUMMARY

The present histological study was conducted on different postnatal age groups of guinea pig. The wall of the jejunum microscopically composed of the four layers namely *viz.*, tunica mucosa, tunica sub mucosa, tunica muscularis and tunica serosa. The shape of the villi in the epithelium was slender and finger like in 0-2 week-old guinea pig where as tongue shaped in remaining age groups. Lamina propria composed of the loose connective tissue with Crypts of the Lieberkuhn. Tunica submucosa was made up of more number of collagen and reticular fibres and few elastic fibres in the wall of the blood vessels. Tunica muscularis was lined by the inner circular and outer longitudinal muscular layer. The mean height and width of the villi and height of the columnar cells and thickness of the tunica muscularis was increased as the age advanced in all the age groups studied.

Keywords: Guinea pig, Histology, Jejunum, Postnatal age, Villi

How to cite: Raja, K., Ushakumary, S., Rajathi, S., Ramesh, G., Ramesh, S., Kumar, K. and Hemavathi, N. (2023). Histo- architectural changes in the jejunum of guinea pig in postnatal age groups. *Haryana Vet.* 62(2): 140-142.

Guinea pigs are descendent of the wild cavy which is considered one of the common rodents lived in the South America. They are characterized by the sticky body, short neck, limbs and tiny are more closely related to the porcupines than mice and rats (Kunzl and Sachser 1999). This species commonly used as experimental model in biomedical research since the immunological genes of the guinea pigs were similar to the humans than those mouse (Guo *et al.*, 2012). There is limited literature on the jejunum of the guinea pig of various postnatal age groups. Hence, the present study was done with the aim to explore the histo-architectural features of the jejunum of the guinea pigs in postnatal age groups.

Histological studies on the jejunum of the guinea pig (*Cavia porcellus*) in postnatal age groups *viz.*, Prewaning (0-2 weeks), weaning (2-8 weeks), young (8-16 weeks) and adult (16-32 weeks) were conducted at the Department of Veterinary Anatomy, Madras Veterinary College, Chennai. Animals were procured from the Department of laboratory animal medicine, Madhavaram milk colony, Chennai. Approval from the institutional animal ethics committee (IAEC) TANUVAS, approval No. 1487/DFBC/IAEC/2018 dated 13.07.2018 was taken. They were euthanized by the standard operating procedure by using carbon dioxide asphyxiation as per CPCSEA norms.

From the guinea pigs of postnatal age groups, samples from the mid part of the jejunum were collected. They were washed in the normal saline and fixed in 10% neutral buffered formalin and tissues were dehydrated in the ascending grades of the alcohol, cleared in xylene and

embedded in paraffin (58-60°C). Sections of 4-5 µm thickness were cut and used for the routine and special histological staining techniques. The various histological techniques *viz.*, Haemotoxylin and Eosin (H & E) method for the histological study (Bancroft and Gamble, 2003), Van Gieson's for collagen fibres, Masson's Trichrome for connective tissue fibres Gomori's silver method for reticulum (1968), Weigert's method for elastic fibres (Humason, 1979) and Fontana Masson's Silver method for enterochromaffin cells were done. Microscopic images of stained tissue sections of the jejunum of postnatal age groups were captured. The various parameters *viz.*, height and width of the jejunum, height of the columnar cells lining the villi and thickness of the tunica muscularis were measured group wise and they were subjected for one-way ANOVA with arithmetic mean and standard error (Mean ± SE) calculated as per Snedecor and Cochran (1994).

The wall of the jejunum of the guinea pig was composed of the four layers namely tunica mucosa, tunica submucosa, tunica muscularis and tunica serosa from inner to outer side. Histologically, in jejunum most of the villi had slender and finger like appearance in 0-2 week-old guinea pigs (Fig. 1). In other age groups jejunal villi were tongue shaped along with few short pyramidal villi (Fig. 2). This is in contrary to the statement of Bansal *et al.* (2000) since they reported the presence of finger like shaped villi in buffalo calves whereas in gaddi goat longer and slender (Andleeb *et al.*, 2016).

Jejunal villi of the guinea pigs were lined by the simple columnar epithelium along with tall columnar cells, goblet cells were also found in the surface epithelium (Fig.

*Corresponding author: raja.vet04@gmail.com

3) as observed by Bacha and Bacha (2000) in mammals and Andleeb *et al.* (2016) in Gaddi goat. Tall columnar cells had narrow base and broad apex with distinct cell boundaries. In addition to this few globular leukocytes, Intra epithelial lymphocytes and enterochromaffin cells were also observed in the surface epithelium (Fig. 4) which is agreeable with the findings of Vithya (2005) in sheep and Andleeb *et al.* (2016) in Gaddi goat.

Goblet cells in the surface epithelium of jejunum possessed round or globular shape. Nucleus was basal, flattened and basophilic with vacuolated cytoplasm. The goblet cells were interspersed among the columnar cells lining the villi and the crypts in jejunum which concurred with the findings of Trautmann and Fiebiger (1957) in domestic animals. The occurrence of the goblet cells was found to be less in the surface epithelium and crypts of Lieberkuhn in 0-2 week old guinea pigs and increased in number as the age advanced. Intra epithelial lymphocytes were present either in the apical or basal parts of the columnar cells of the villi, folds and crypts of Lieberkuhn as intra epithelial lymphocytes (Fig. 4).

Lamina propria of jejunum of guinea pig was made up of loose connective tissue which in turn had highly cellular components along with connective tissue fibres as observed by Abbas *et al.* (1989) in jejunum of mouse. Intestinal glands or crypts of Lieberkuhn were noticed in the lamina propria of jejunum (Fig. 5) in all the postnatal age groups studied and this is in accordance with the findings of Menaha (2003) in guinea fowl, Vithya (2005) in sheep, Gulbinowicz *et al.* (2004) in mice and Andleeb *et al.* (2016) in Gaddi goat.

Reticular fibers were predominated in the lamina propria of jejunum (Fig. 6). Collagen fibres were less in their occurrence (Fig. 7 and 8). Elastic fibers were few and could be seen around the blood vessels of jejunum as reported by Valsala *et al.* (1985) in ducks. The number of intestinal glands in jejunum appeared to be increased from 0-2 week-old to 16-32 week-old postnatal age groups studied as noted by of Menaha (2003) in guinea fowl, Vithya

(2005) in sheep and Andleeb *et al.* (2016) in Gaddi goats.

The submucosa was distinct in the jejunum of the guinea pig in all the age groups studied. However, the submucosal layer of was very thin in 0-2 week-old guinea pigs it was made up of the collagen and reticular fibres in all the postnatal age groups studied. Submuosa demarcated by the presence of the single layer of the smooth muscle fibres muscularis mucosa. Some places the meissner's plexus were noticed in the submucosa as stated by Lundgren, (2000) in human beings. In some of the sections of the submucosa of the jejunum showed the presence of lymphoid aggregations as nodules this finding is similar with the finding of Stinson and Calhoun (1993) since they stated the presence of Peyer's patches in all the segments of small intestine.

The tunica muscularis was composed of the inner circular and outer longitudinal smooth muscle layers which were agreeable with the findings of the Vithya (2005) in goat and Andleeb *et al.* (2016) in gaddi goat. Large blood vessels and well developed Auerbach's plexues or myenteric plexues were noticed in the intermuscular connective tissue (Fig.10). Tunica serosa distinct in jejunum. It was lined by the mesothelium. Appreciable amount of the loose connective tissue was found between the tunica muscularis and tunica serosa as reported by the Vithya (2005) in sheep and Menaha (2003) in guinea fowl. Micrometrically, the mean height and width of the villi and height of the columnar cells and thickness of the tunica muscularis were found to be increased from 0-2 week-old to 16-32 week-old guinea pigs studied (Table.1).

REFERENCES

- Abbas, B., Hayes, T.L., Wilson, D.J. and Carr, K.E. (1989). Internal structure of the intestinal villus. Morphological and morphometric observations at different levels of the mouse villus. *J. Anat.* **162**: 263-273.
- Andleeb, R., Rajesh, R., Massarat, K., Baba, M.A., Masuood, J. and Dar, F.A. (2016). Histomorphological study of the Paneth cells and enterochromaffin cells of the small intestine in Gaddi Goat. *SKUAST J. Res.* **18**(1): 54-67.
- Bacha, W.J. and Bacha, L.M. (2000). Colour atlas of histology, Chapter

Table 1. Micrometry of the height and width of the villi, height of the columnar cells and tunica muscularis of the jejunum different age groups of guinea pigs (Mean \pm S.E in μ m).

S. No.	Age groups	Height of the villi of the Jejunum		Width of the villi of Jejunum		Height of the columnar cells of the Jejunum		Mean thickness Tunica muscularis of Jejunum	
		Free border	Attached border	Free border	Attached border	Free border	Attached border	Free border	Attached border
1.	0-2 week	292.3 \pm 27.8	228.3 \pm 51.4	52.7 \pm 3.4	28.3 \pm 1.36	29.60 \pm 1.28	27.1 \pm 1.04	30.8 \pm 2.29	95.6 \pm 12.6
2.	2-8 week	346.5 \pm 21.7	365.6 \pm 1.8	68.9 \pm 6.5	50.52 \pm 6.97	31.05 \pm .037	28.1 \pm 1.22	35.9 \pm .75	100.0 \pm 21.9
3.	8-16 week	362.5 \pm 18.0	403.2 \pm 17.7	65.3 \pm 0.24	83.9 \pm 0.50	32.6 \pm 4.56	29.4 \pm 1.57	100.8 \pm 1.22	142.4 \pm 22.7
4.	16-32 week	410.7 \pm 6.8	387.3 \pm 22.3	62.5 \pm 1.06	85.4 \pm 3.00	33.6 \pm 1.1	33.7 \pm 0.55	112.2 \pm 35.9	145.7 \pm 1.71
	F-Value	9.30**	28.91**	3.41*	5.42**	67.026**	6.250**	5.555**	2.467*

Mean bearing different superscript differs significantly

* - Significant difference among groups (P = 0.05), ** - Highly significant difference among groups (P = 0.01)

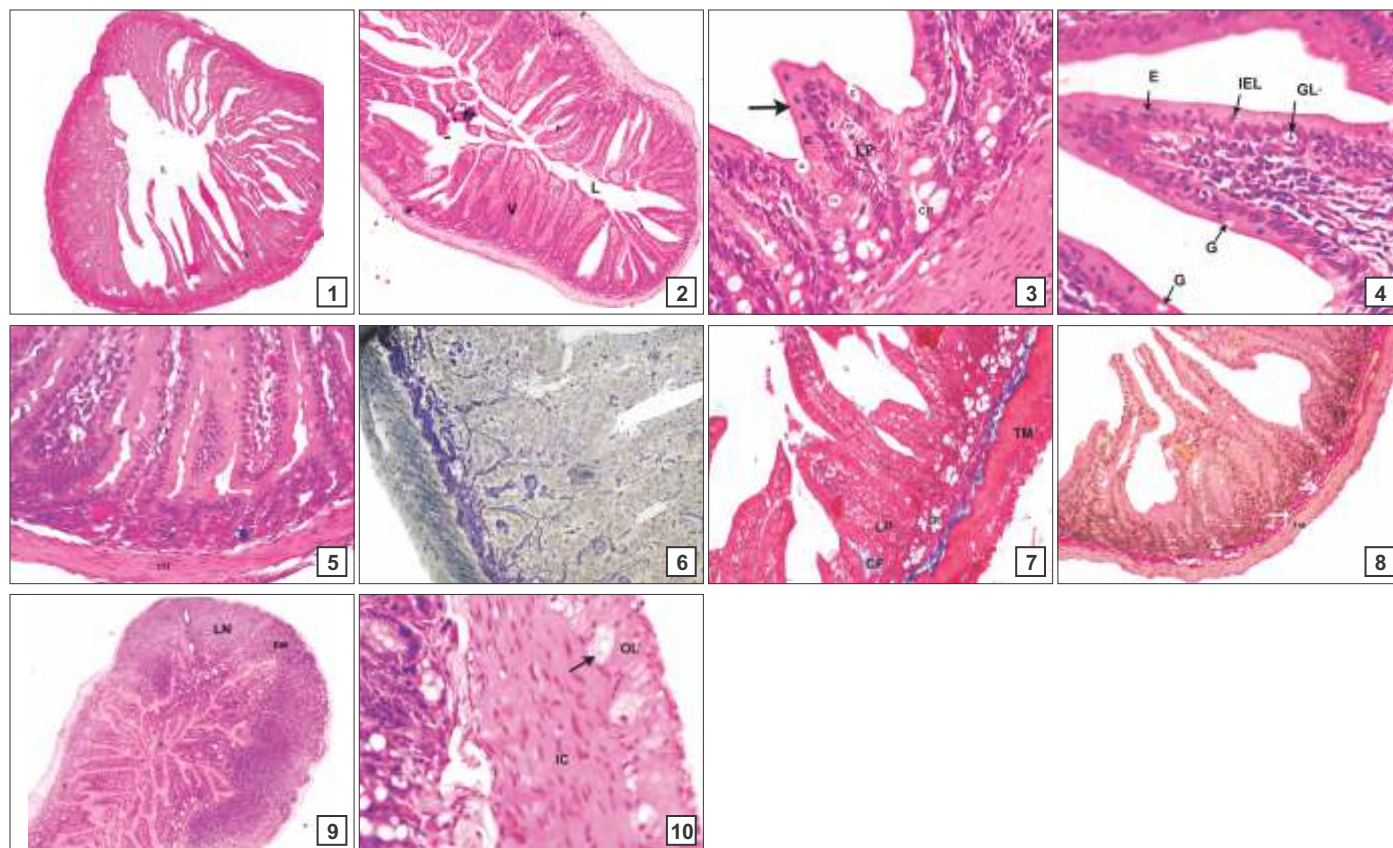


Fig.1-10. (1) Photomicrograph of jejunum of one week old guinea pig showing the finger/slender shaped villi. V-Villi, L-Lumen. H&E X 40; (2) Photomicrograph of jejunum of 28 week-old guinea pig showing the tongue shaped villi. V-Villi, L-Lumen. H&E X 40; (3) Photomicrograph of jejunum of four week-old guinea pig showing the cells of the surface epithelium and crypts of Lieberkuhn (CR), E-Enterocyte, Arrow- Striated border LP-Lamina propria, G-Goblet cells. (4) Photomicrograph of jejunum of twelve week old guinea pig showing the cells of the surface epithelium E-Enterocytes, GL-Globular Leukocytes, G-Goblet cells, IEL-Intra epithelial Lymphocytes. (5) Photomicrograph of the jejunum of the twelve week old guinea pig showing the presence of the crypts (CR) in the lamina propria (LP). H&E X 100; (6) Photomicrograph of the jejunum of the eight week-old guinea pig showing the presence of Reticular fibres (white arrows) CR-Crypts of Lieberkuhn TM-Tunic muscularis. Gomori's Reticulum method X 100; (7) Photomicrograph of lamina propria of jejunum of 12 week-old guinea pig showing the Crypts of Lieberkuhn (CR) V-Villi, CF-Collagen fibres, TM-Tunic muscularis. Masson's Trichrome X 100; (8) Photomicrograph of the jejunum of the two week old guinea pig showing the presence of collagen fibres (white arrows) lamina propri. V-villi, CR-Crypts of Lieberkuhn, TM-Tunic muscularis. Van Gieson's X 100; (9) Photomicrograph of the jejunum of the two week-old guinea pig showing the lymphoid nodules in the submucosa (SM) LN-Lymph node. H &E X 40; (10) Photomicrograph of the jejunum of twelve week-old guinea pig showing the well developed Auerbach's plexus (Arrow) in the intramuscular tissue. IC-Inner circular muscle layer OL-Outer longitudinal muscle layer. H &E X 400

- XIII, "Digestive system", (2nd Edn.), Lipincott William and Wilkins, Philadelphia. pp.119-47.
- Bancroft, J.D. and Gamble, M. (2003). Theory and practice of histological techniques. (5th Edn.), Newyork. pp. 121-134.
- Bansal, N., Khatra, G.S. and Sigal, R.P. (2000). Age-correlated histomorphological changes in the tunica mucosa of small intestine in buffalo. *Buff. J.* **16**(3): 31-347
- Gulbinowicz, M., Bozena, B., Slawomir, W., Jerzy, D., Seija, O., Marja, M., Velimatti, K., Hannu, M. and Janusz, M. (2004). Morphometrical analysis of the small intestine in wild type mice. A developmental study. *Folia. Morpholo.* **63**: 423-430.
- Guo, Y., Bao, Y., Meng, Q., Hu, X., Ren, L., Li, N. and Zhao, Y. (2012). Immunoglobulin genomics in the guinea pig (*Cavia porcellus*). *Plos One.* **7**(6): 392-398.
- Humason, G.L. (1979). Animal tissue techniques. (2nd Edn.), W.H. Freeman Co., London. pp. 56-76.
- Kunzl, C. and Sachser, N. (1999). The behavioural endocrinology of domestication: a comparison between the domestic guinea pig (*Cavia porcellus*) and its wild ancestor. *Horm. Behav.* **35**: 28-37.
- Luna (1968). Manual of histological staining methods of the armed forces of institute of Pathology, (3rd Edn.), The Blackistone Div. McGraw-Hill Book Co., New York. pp. 87-89.
- Lundgren, O. (2000). Sympathetic input into the enteric nervous system. *Gut.* **47**(4): 33-35.
- Menaha, P. (2003). Gross and microanatomical studies of the small intestine in the Guinea fowl (*Numida melagris*). M.V.Sc. thesis submitted to the Tamilnadu Veterinary and Animal Sciences University, Chennai.
- Raja, K., Ushakumary, S., Ramesh, G., Ramesh, S., Rao, G.V.S. and Rajathi, S. (2022). Gross anatomical studies on the small intestine in the postnatal age groups of guinea pig. *Haryana Vet.* **60**(1): 1-4.
- Snedecor, G.W. and W.G. Cochran, (1994). Statistical method. (6th Edn.), Oxford and IBH publishing Co, Calcutta, India. pp. 67-157.
- Stinson, A.W. and M.L. Calhoun, (1993). Digestive system. In: Textbook of Veterinary Histology. (4th Edn.), Dellmann, Ed. Lea and Febiger, Philadelphia. 153-193.
- Trautmann, A. and Fiebiger, J. (1957). Fundamentals of the histology of domestic animals. Comstock Publishing Associates, Ithaca, New York. pp. 153-229.
- Valsala K.V., Jarplid, B. and H.J. Hansen. (1985). Distribution and ultrastructure of mast cells in the duck. *Avian Dis.* **30**(4): 653-657.
- Vithya, M. (2005). Microanatomical studies on the small intestine of Sheep (*Ovis aries*). M.V.Sc thesis submitted to Tamilnadu Veterinary and Animal Sciences University, Chennai, India.