

COMPARATIVE EVALUATION OF BONE LESIONS BY COMPUTED TOMOGRAPHY AND RADIOGRAPHY IN DOGS

SATYAVEER SINGH*, SAKAR PALECHA and P. BISHNOI

Department of Veterinary Surgery and Radiology,
Rajasthan University of Veterinary and Animal Sciences, Bikaner-334001, Rajasthan, INDIA

Received: 01.05.2023; Accepted: 08.06.2023

ABSTRACT

Eight dogs were included in the present study to evaluate the ability of computed tomography (CT) and radiography to diagnose the bony lesions. Radiography, signalment, CT appearance and location of bony lesions were used for the bone lesion diagnosis. Aggressive and non-aggressive nature of lesions was categorized based on independent assessment of both diagnostic modalities; CT and radiography. Bone lesions showing positive signs had characteristics that include the periosteal reaction and scale of osteolytic pattern which is related to the degree of aggression. Thoracic CT images were used for detection of pulmonary metastases and serum level of alkaline phosphatase was also recorded in all the cases. Sunburst appearance, new bone formation, cortical lysis and pathological fractures are the commonly observed clinical findings on radiographic and CT imaging. In conclusion, CT imaging is recommended over radiography for any abnormal bony changes, tumour staging and clinical relevant pathology which can be used as gold standard and tumour staging in dogs.

Keywords: Alkaline phosphatase, Bone lesions, Computed Tomography, Dog

How to cite: Singh, S., Palecha, S. and Bishnoi, P. (2023). Comparative evaluation of bone lesions by computed tomography and radiography in dogs. *Haryana Vet.* 62(2): 98-103.

Computerized tomography (CT) enables the improved understanding of the osseous changes at outer cortex, in and at the margins of the joints, density of the bones, intra-articular fracture and mineralization which enhances the successful diagnosis of bone lesions of appendicular skeleton in dogs (Singh *et al.*, 2021). Reaction of bone to any disease process or lesion is evident radiographically as; increased opacity (productive or sclerotic changes); decreased opacity (osteolysis or osteoporosis) and periosteal reaction (Borggreffe *et al.*, 2015; Sung *et al.*, 2017). The presence of bone production and/or bone destruction may be elicited as aggressive or non-aggressive response of the bone. Radiography has been considered as the mainstay of characterization of bone lesions. The role of CT is largely centered to provide the information of diagnostic relevance and the assessment of extent of bone lesions. Computed tomography (CT) is an imaging modality that offers precise anatomical localization and lesion description and origin of neoplastic masses due to its multiplanar reconstruction capability (Strohmayr and Anson, 2018). It can be employed for both evaluations of local disease and detection of distant metastasis by thoracic radiography and CT images (Ninama *et al.*, 2022). CT provides important information in terms of invasion of adjacent structures, extension and resectability of the masses. Computed tomography can identify subtle changes within the medullary cavity of bone, prior to visible radiographic bone lysis. Faint mineralization in a lesion is best assessed by using CT, being more sensitive than radiography for differences in

attenuation (Singh *et al.*, 2019a). The present study describes the comparative evaluation of computed tomography (CT) and radiography to visualize the bone lesions manifested as aggressive and non aggressive in dogs.

MATERIALS AND METHODS

Eight client-owned dogs were included in an observational study with a history and variable clinical signs of localized limb swelling and/or acute or chronic lameness usually progressive and sometimes refractory to treatment, neurological dysfunction with spontaneously occurring aggressive bone lesions. These lesions were diagnosed based on the signalment, radiographic and computed tomographic lesions and their consistent location for primary or secondary bone tumours or similar conditions. Skeletal computed radiography was done in these dogs for initial radiographic diagnosis. CT examination in dogs with the affected bone and of the thorax was performed in selected cases using 16 slice Machine (Supria, Hitachi) under general anaesthesia. Contiguous transverse CT images were acquired after positioning using a bone window and the pulmonary metastasis using a high resolution lung algorithm for the thorax. The raw data was reconstructed for 3D and multiplanar image reconstruction using different protocols. Serum alkaline phosphatase level was recorded in all the eight dogs. Assessment of both imaging modalities was done independently for lesions classification as either aggressive or non aggressive based on radiographic and CT characteristics and score was given as equivocal, negative or positive. Aggressive characteristics of positive bone lesions elicited by lytic changes and/or periosteal

*Corresponding: satyaveersingh4@gmail.com

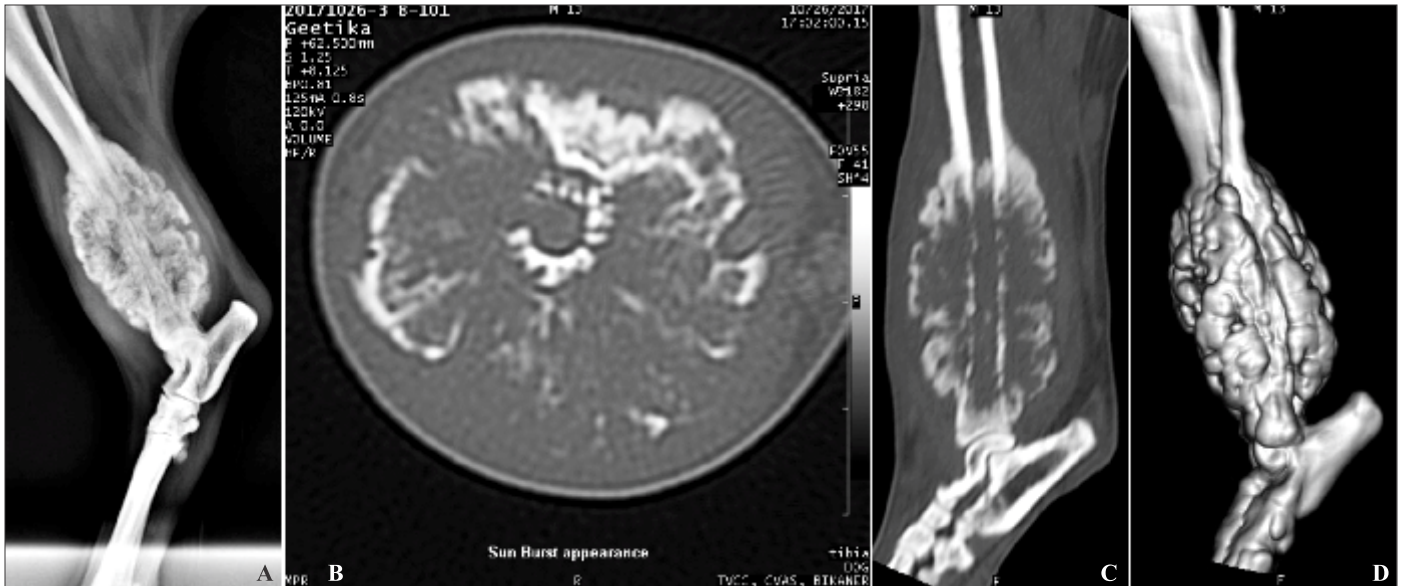


Fig. 1. Radiographic image (A) Showing mottled, irregular lysis of cortical bone with 'amorphous' periosteal reaction. Axial CT image (B) showing 'sunburst' appearance and osteolytic and proliferative changes. Sagittal plane (C) and 3D (D) reconstructed image showing mixed pattern osteolysis; reduced radiopacity of bone compared with soft tissues (ghostly bones).

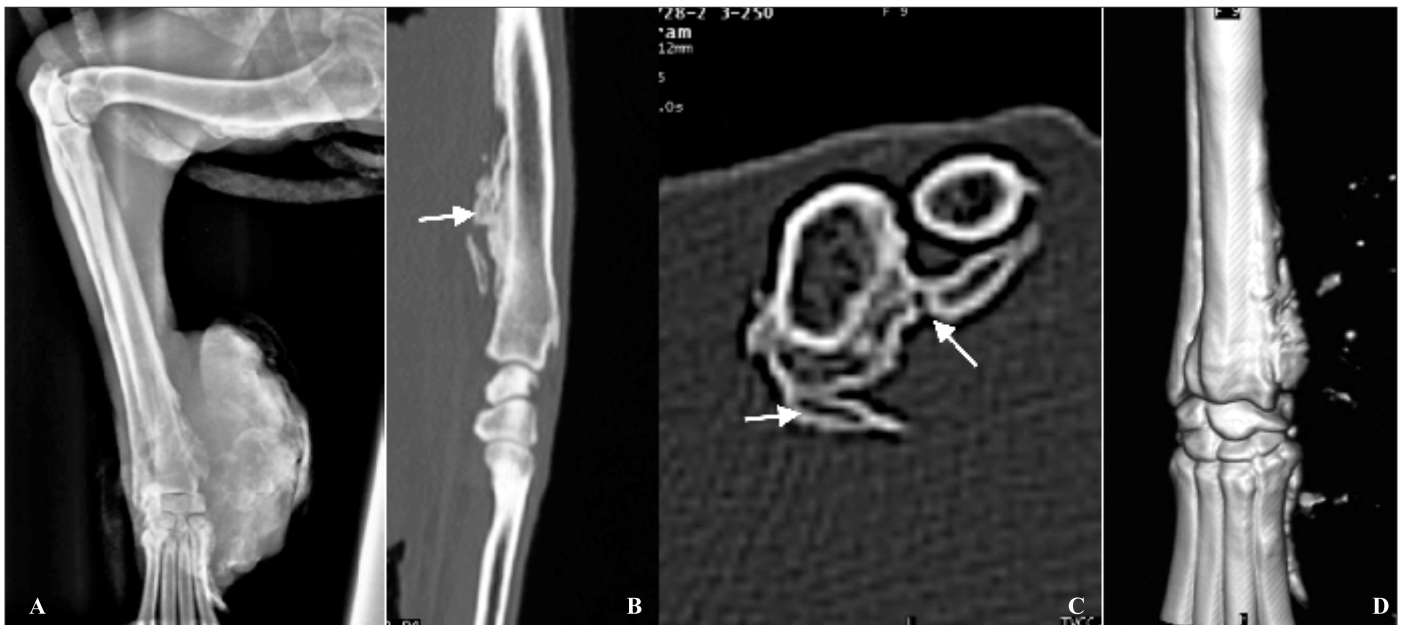


Fig. 2. (A). Radiograph - Soft tissue enlargement along with mineralization, cortical thinning and bony reactions at the distal radius ulna bones. (B, C, D). CT images; (MPR, Axial & 3-D) showing the irregular convoluting enlargement along the metaphyseal and diaphyseal region of distal radius (arrow) along with soft tissue enlargement. Aggressive lesions are represented by region of osteolysis of metaphyseal trabeculae and cortical bone with fairly distinct inner cortex.

reaction. Equivocal bone lesions have radiographic and CT characteristics that were suggestive but not definitive for an aggressive bone lesion. The pulmonary metastases lesions were identified on thoracic CT images as soft tissue nodule(s) or equivocal area of increased density/ground glass appearance in the lungs for tumour staging.

RESULTS AND DISCUSSION

The primary appendicular or axial (vertebral) bone lesions were diagnosed in all dogs based on the presence of an aggressive bone reaction using radiography and CT

imaging modalities. The data recorded for signalment and location of lesion are presented in Table 1. The pathologies of bones which included tumors of aggressive behaviour were identified as multiple myeloma (1 case) and osteosarcoma (5 cases) whereas, 2 cases of panosteitis showed the non-aggressive behaviour. Positive bone lesions with aggressive bone reaction included the scale of appearances of osteolytic changes and periosteal reactions, has been described for all the cases which relates to the degree of aggression. In most of the cases common findings were observed with both the diagnostic

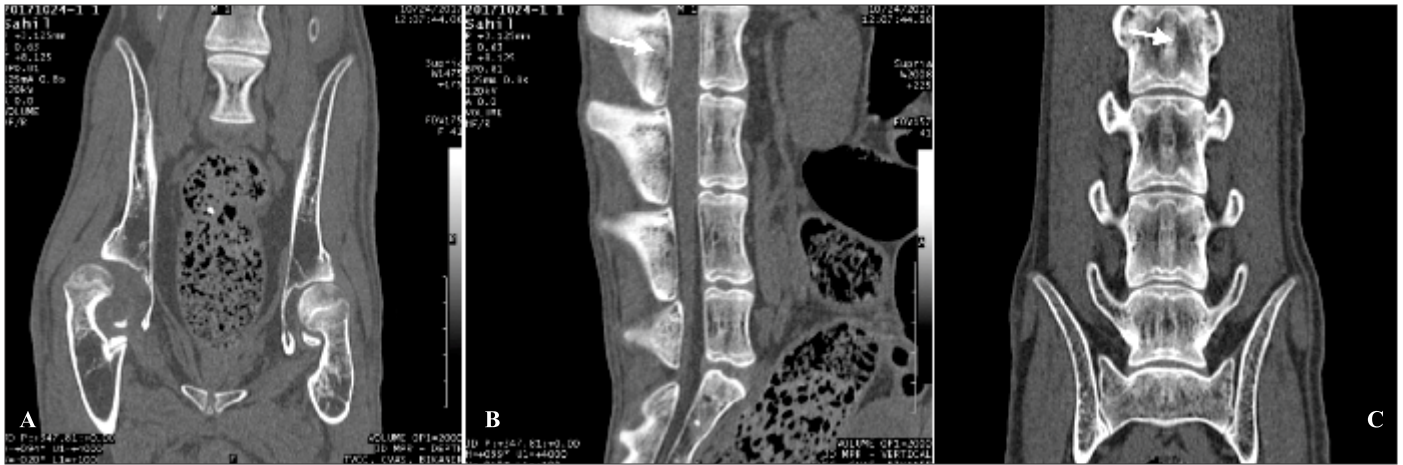

Fig. 3. MPR CT images showing radiolucency of pelvis, vertebral bodies, spinous processes (arrow) and femur; multiple poorly margined to well defined foci of osteolysis accompanied with hip dysplasia.

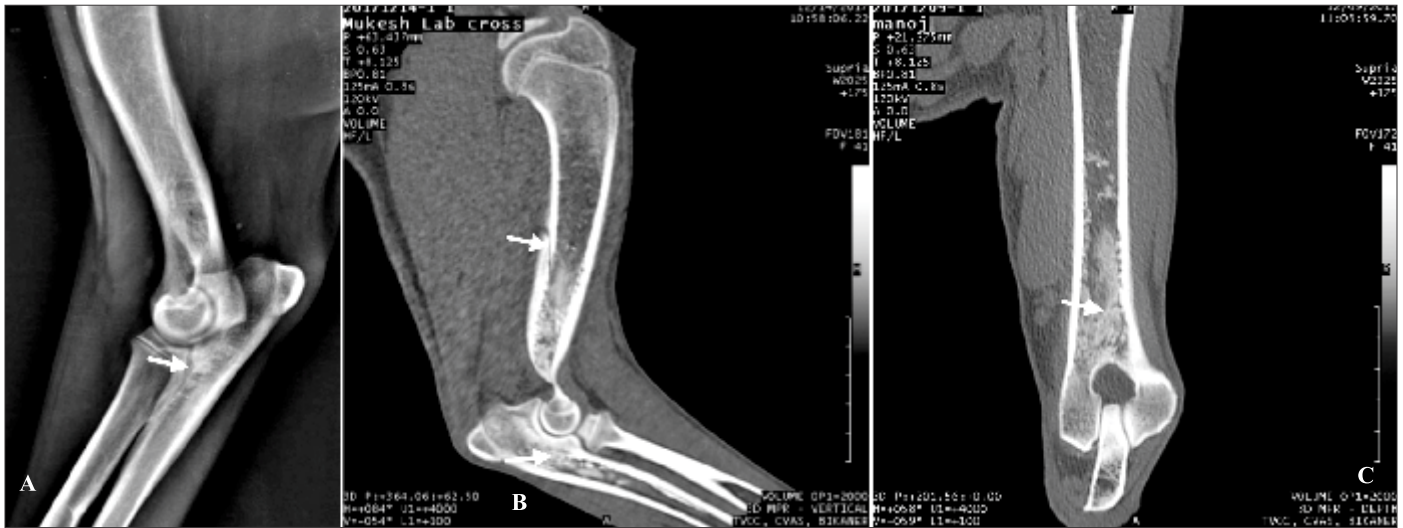

Fig. 4. (A) Radiograph & CT images (B & C) in different planes showing hyper dense medullary patches near nutrient foramen in the distal diaphyseal region of humerus and proximal part of ulna bone with evidence of coarse trabeculation and endosteal reaction in the distal humerus.

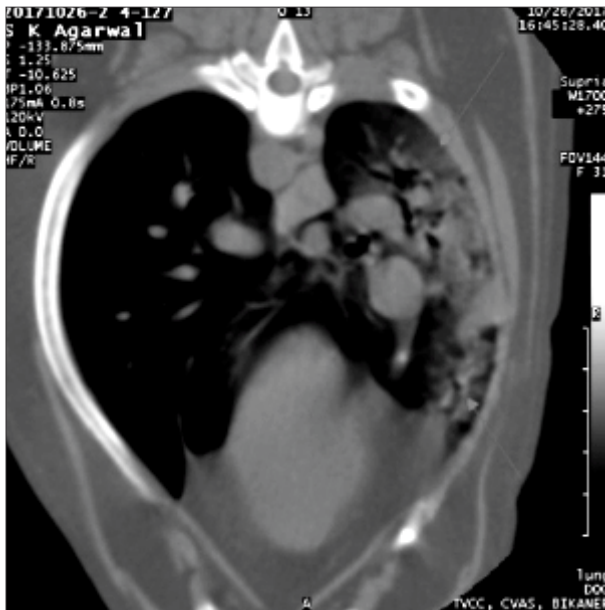

Fig. 5. CT images (Transverse plane) with soft tissue attenuating metastatic lesions in lung parenchyma in adog with osteosarcoma of tibia and fibula bone (Case 1).

modalities but detailed description, delineation of cortical margins and contrast resolution of the lesions were seen in computed tomographic (CT) images (Singh *et al.*, 2019b). Pulmonary metastases were also detected in 2 cases based on the presence of discrete soft tissue attenuating nodular densities in the lungs. Elevated alkaline phosphatase levels were recorded in all the cases and presented in Table 2. Histopathology confirmed the plasma cells tumor in the bone marrow with areas of bone infiltration and destruction. Detailed radiographic and computed tomographic (CT) findings of all the cases are presented.

In osteosarcoma cases; proliferative changes at cortex, sunburst' appearance of lesions (Fig. 1B), Mixed pattern osteolysis with reduced bone density compared to soft tissue (ghostly bones) (Fig. 1C) with thin shell like cortices were diagnosed by both the diagnostic modalities; radiography and CT scan but more appreciable by computed tomographic images. Pathological fracture with soft tissue swelling at the affected sites was also the

Table 1. Signalment and location of bone lesions in dogs

Case No.	Breed	Age (Yrs.)	Sex	Body wt (Kg)	Location of Bone lesion
1	Labrador	13	M	11	Distal 1/3 rd tibia –fibula
2	Labrador	1	M	15	Distal humerus and proximal radius -ulna
3	German Shepherd	1.4	F	27	Distal 1/3 rd of radius and ulna
4	German Shepherd	11 months	M	29	Distal 1/3 rd of humerus
5	German Shepherd	08	M	20	Proximal and distal humerus
6	Great Dane	6	M	50	Stifle, proximal tibia
7	German Shepherd	01	M	18	Vertebrae (lumbar region) and pelvis
8	Non-descript	9	F	21	Distal radius and deltoid tuberosity of humerus

Table 2. Definitive or equivocal bone lesions, ALP value and metastasis identified in the dogs

Case No.	Modality used	D/E	ALKP Level (U/L)	Pulmonary Metastasis	Radiological diagnosis
1	R	D	1116.3	M	Osteosarcoma tibia and fibula
	CT	D			
2	R	E	147.6	-	Panosteitis
	CT	D			
3	R	D	442.1	-	Osteosarcoma radius and ulna
	CT	D			
4	R	E	274.0	-	Panosteitis
	CT	D			
	CT	D			
5	R	D	763.22	-	Osteosarcoma of humerus and ulna
	CT	D			
6	R	D	1534.2	M	Osteosarcoma distal femur and proximal tibia
	CT	D			
7	R	-	610.7	-	Multiple myeloma involving pelvis and vertebrae
	CT	D			
8	R	E	222.38	-	Parosteal/periosteal osteosarcoma
	CT	D			

D= Definitive E= Equivocal

common findings in all the cases. Solid periosteal reactions at deltoid tuberosity and soft tissue mass also observed. Radiological lesions in one case affected with osteosarcoma at stifle joint also showed the secondary lesions of skull bones which were more appreciable on maxilla and mandible with osteolytic changes.

In case of the multiple myeloma, Digital radiography showed the radiolucency of femur, pelvic bones and lumbar vertebrae. Multiplanar reconstructive CT images of the pelvis demonstrated the poorly margined to well defined foci of osteolysis in the vertebral bodies, spinous process and pelvic bones (Fig. 3).

In panosteitis cases lateral digital radiograph of right humerus demonstrated area of increased opacity and in the medullary cavity of humerus and ulna bones but significantly patchy attenuating density by CT images was observed close to the nutrient foramen. Sagittal and frontal planes demonstrated the area with increased attenuating

densities in the medullary canal of distal humerus and close to the nutrient foramen. Endosteal proliferative activity was also evident in the distal third of humerus (Fig. 4).

The 3D reconstructed images showed irregular bony tumorous mass (1D), extensive osteolysis, pathological fracture and massive cortical destruction. Displaced patella bones, angular rotation of affected limb were well appreciated on 3-dimensional images.

Lesions of metastasis were also observed in lung parenchyma; small multiple nodular appearances observed in the lung parenchyma prominently at right side lobes. Transverse CT images of lung parenchyma (Fig. 5) revealed soft tissue nodular lesions of varying irregular shapes were dispersed within the lungs parenchyma.

The aggressive behaviour of a bone lesion is better visualized with advanced imaging modalities like CT compared to either conventional or digital radiography. Most information on aggressive behaviour corresponds to

the extent and location of the lesions within a bone, the bone response to tumor, cortical changes, periosteal reaction and the involvement of adjacent soft tissue. For the majority of primary bone tumors, sunburst appearance, new bone formation and cortical lysis, is commonly seen features in malignant tumors. However, non-aggressive lesions like panosteitis with increased intramedullary radiopacity within the bone can be differentially diagnosed with osteomyelitis using CT imaging. CT has always been preferred imaging technique for the evaluation of thoracic lesions and considered as gold Standard for tumor staging, because of its improved ability to detect pulmonary metastasis on initial staging of aggressive bone lesions in dogs. The CT provides high-quality bone images and has far superior sensitivity for the detection of metastasis than radiography.

In the presents study, aggressive behaviour of bone lesions were recorded in primary bone tumors of appendicular skeleton. Radiographic and computed tomographic (CT) findings in aggressive bone lesions were cortical bone destruction, eroded cortical margins, periosteal reactive bone production and sunburst appearance. Tendency of lytic tumors to infiltrate adjacent soft tissues and pathological fractures are related with the cortical bone erosion (Thompson, 2007). Radiographic characteristics of an aggressive bone lesion include a wide zone of transition between the tumor and the surrounding normal bone, cortical destruction and aggressive–appearing periosteal new bone formation (Stacy *et al.*, 2006).

Osteosarcoma is the main tumor of appendicular skeleton, and more prevalent as 3.5 times in the forelimbs than hindlimbs (Trost *et al.*, 2012). Sun-burst appearance is typically seen in these aggressive tumours, associated with cortical destruction. Clinical, radiographical and gross findings are consistent with the diagnosis of the malignant bone tumors. In the present study, both CT and computed radiography were conclusive to diagnose the osteosarcoms. Although, CT features of osteosarcoma and other primary bone tumors were similar to those of survey radiography but CT may also more clearly delineate internal and extra-cortical tumor margins compared to radiographs (Wisner and Zwingenberger, 2015). In the reported case of multiple myeloma in present study detailed findings were diagnosed with the CT images which could not seen by the radiography (Singh *et al.*, 2019b).

Multiple myeloma is a multifocal and polyostotic condition widely distributed within both axial and appendicular bones (Wisner and Zwingenberger, 2015). The principle sites of bone involvement in dogs and cats

are vertebrae, femur, pelvis, humerus and ribs. The typical radiographical lesions of multiple myeloma are discrete, punched out foci of osteolysis, varying in size, lacking sclerotic margins and periosteal reaction, and often involving multiple bones (Thompson and Dittmer, 2017). Generalized osteoporosis without obvious lytic foci has also been reported in some cases (Rusbridge and Wheeler, 1999). CT is more superior to survey radiography for determining the presence of subtle changes and detailed diagnosis (Singh *et al.*, 2019a) and size of vertebral plasma cell tumors (Healy *et al.*, 2011).

Panostitis condition was observed in 2 cases. The disease is described as a self-limiting idiopathic bone disorder that occurs predominantly in large breed dogs 5–18 months of age and German Shepherd Dogs have higher incidence (Demko and McLaughlin, 2005). Both CT and computed radiography had the similar characteristics of increased intramedullary radiopacity mainly at the level of nutrient foramen (Pollard and Wisner, 2013). Radiographic images are sufficient to diagnose the characteristics changes occurred in the medullary cavity and periosteal reactions but contrast resolution of the images were seen in the CT images. Similar findings of diagnosis of panosteitis by radiography in camels have been reported (Levine *et al.*, 2007).

Pulmonary metastasis was detected in 2 cases which were identified on CT images. Although radiographic images are not provide the good contrast as compare to CT images but this is the mostly used techniques for thoracic imaging and for pulmonary metastasis (Ninama *et al.*, 2022). CT image showed the ground glass appearance and discrete soft tissue attenuating nodules distributed in lung parenchyma (Oblak *et al.*, 2016).

CONCLUSION

It is concluded that CT and computed radiography were conclusive to diagnose the aggressive and non-aggressive bony lesions but CT imaging is superior to radiography for diagnosis, clinical relevance pathology and staging of aggressive bone lesions.

REFERENCES

- Borggreffe, J., Giravent, S., Campbell, G., Thomsen, F., Chang, D., Frankea, M., Gunther, A., Heller, M. and Wulff, A. (2015). Association of osteolytic lesions, bone mineral loss and trabecular sclerosis with prevalent vertebral fractures in patients with multiple myeloma. *Eur. J. Rad.* pp. 1-6. <http://dx.doi.org/10.1016/j.ejrad.2015.07.024>.
- Demko, J. and McLaughlin, R. (2005). Developmental orthopedic disease. *Vet. Clin. North Am. Small Anim. Pract.* **35**: 1111-1135.
- Healy, C.F., Murray, J.G., Eustace, S.J., Madewell, J., Gorman, P.J.O. and Sullivan, P.O. (2011). Multiple myeloma: A review of imaging features and radiological techniques. *Bone Marrow Res.* pp. 1-.

doi:10.1155/2011/583439.

- Levine, D.G., Smith, J.J., Richardson, D.W., Brown, V., Beech, Habecker, P. and Adam, E. (2007). Suspected panosteitis in a camel. *J. Am. Vet. Med. Assoc.* **231**: 437-441.
- Ninama, U.K., Singh, S., Singh, Y.P. and Parashar, M.C. (2022). Computed radiographic measurement of different thoracic parameters in healthy German Shepherd dogs. *Haryana Vet.* **61(SI)**: 56-59.
- Oblak, M.L., Boston, S.E., Woods, J.P. and Nykamp, S. (2016). Comparison of concurrent imaging modalities for staging of dogs with appendicular primary bone tumors. *Vet. Oncol.* pp. 1-12. doi: 10.1111/vco.12016.
- Pollard, R.E. and Wisner, E.R. (2013). Orthopaedic diseases of young and growing dogs and cats. In Textbook of Veterinary Diagnostic Radiology (6th Edn.), Thrall, D.E., Elsevier saunders publication St. Louis, Missouri. pp. 267-282.
- Rusbridge, C. and Wheeler, S.J. (1999). Vertebral plasma cell tumors in 8 dogs. *J. Vet. Internal Med.* **13**: 126-133.
- Singh, S., Palecha, S. and Bishnoi, P. (2019a). Computed radiographic and computed tomographic diagnosis of pectoral limb fracture in dogs. *Indian J. Vet. Surg.* **40(1)**: 16-19.
- Singh, S., Palecha, S. and Bishnoi, P. (2019b). Computed tomographic diagnosis of pelvic fractures in dogs: Report of 4 cases. *Vet. Pract.* **20(1)**: 53-55.
- Singh, S., Palecha, S., Bishnoi, P. and Gahlot, T.K. (2021). Evaluation of degenerative changes of elbow and coxofemoral joints in dogs using computed tomography. *Indian J. Vet. Surg.* **42(2)**: 84-90.
- Stacy, G.S., Mahal, R.S. and Peabody, T.D. (2006). Staging of bone tumors: A review with illustrative examples. *Am. J. Roentgenol.* **186**: 967-976.
- Strohmayr, C. and Anson, A. (2018). The role of computed tomography in the oncologic patient. *Clinica Vet. de Pequenos Anim.* **38(1)**: 7-14.
- Sung, S., Lim, S., Oh, H., Kim, K., Choi, Y. and Lee, L. (2017). Atypical radiographic features of multiple myeloma in a dog: a case report. *Vet. Medicina.* **62(09)**: 522-526.
- Thompson K. (2007). Bones and Joints. In: Maxxie M.G. (Ed.), Jubb, Kennedy and Palmer's Pathology of Domestic Animals. (5th Edn.), Mosby Elsevier, St Louis. pp. 1-184.
- Thompson, K.G. and Dittmer, K.E. (2017). Tumors of bone. In: Tumors in domestic animals. (5th Edn.), Meuten, D.J. (Ed.), John Wiley & Sons, Inc. publication.
- Trost, M.E., Kommers, G.D., Brown, C.C., Barros, C.S.L., Irigoyen, L.F., Figuera, R.A., Inkelmann, M.A. and da Silva, T.M. (2012). Primary bone neoplasms in dogs: 90 cases. *Pesq. Vet. Bras.* **32(12)**: 1329-1335.
- Wisner, E.R. and Zwingenberger, A.L. (2015). Atlas of small animal CT and MRI. (1st Edn.), John Wiley & Sons, Inc. Publication. p. 693.

CONTRIBUTORS MAY NOTE

- Research/Clinical articles are invited for next issue from the Scientists/Veterinarians engaged in Veterinary Profession.
- Please follow strictly the format of 'The Haryana Veterinarian' for manuscript writing/submission.
- Please pay processing fee of Rs. 1000/- online in the account of Dean, College of Veterinary Sciences, along with each article.
- After revision, please return the revised manuscript and rebuttal at the earliest.
- Please mention your article reference number in all correspondence for a quick response.
- We solicit your co-operation.
- All correspondence should be addressed to 'The Editor', Haryana Veterinarian, Department of Veterinary Parasitology, College of Veterinary Sciences, LUVAS, Hisar-125004.

Editors