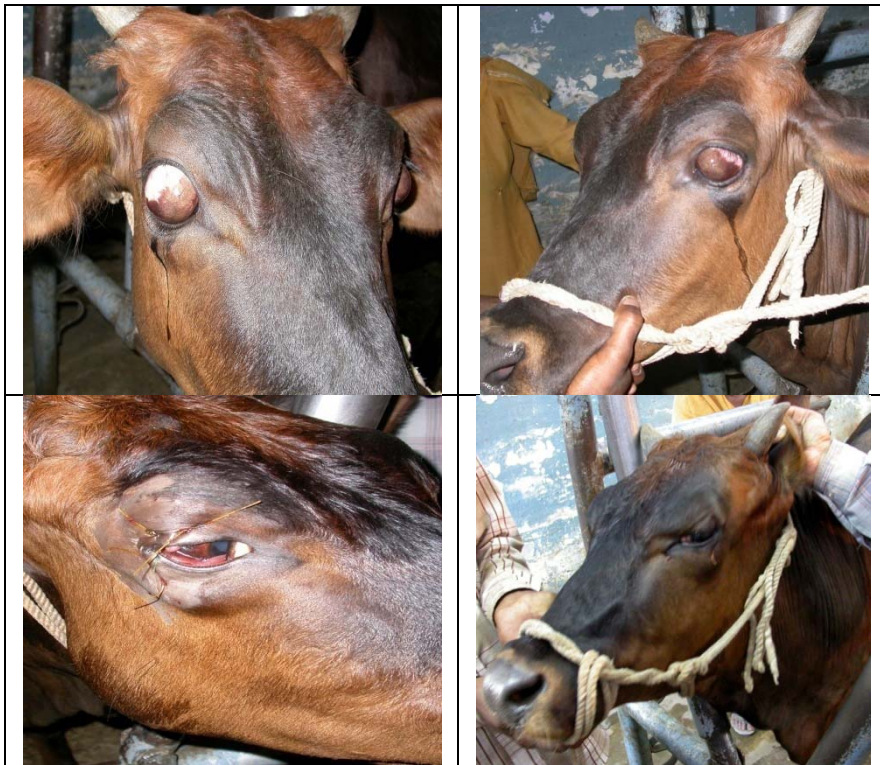

Important photographs of the TVCC Regional Centre, Uchani, Karnal

Surgical correction of bilateral Medial deviation of eyeball in a crossbred cow



Training of Internship students on Computed Radiography (CR)




CMT & Culture Sensitivity Test (CST) of Milk Samples



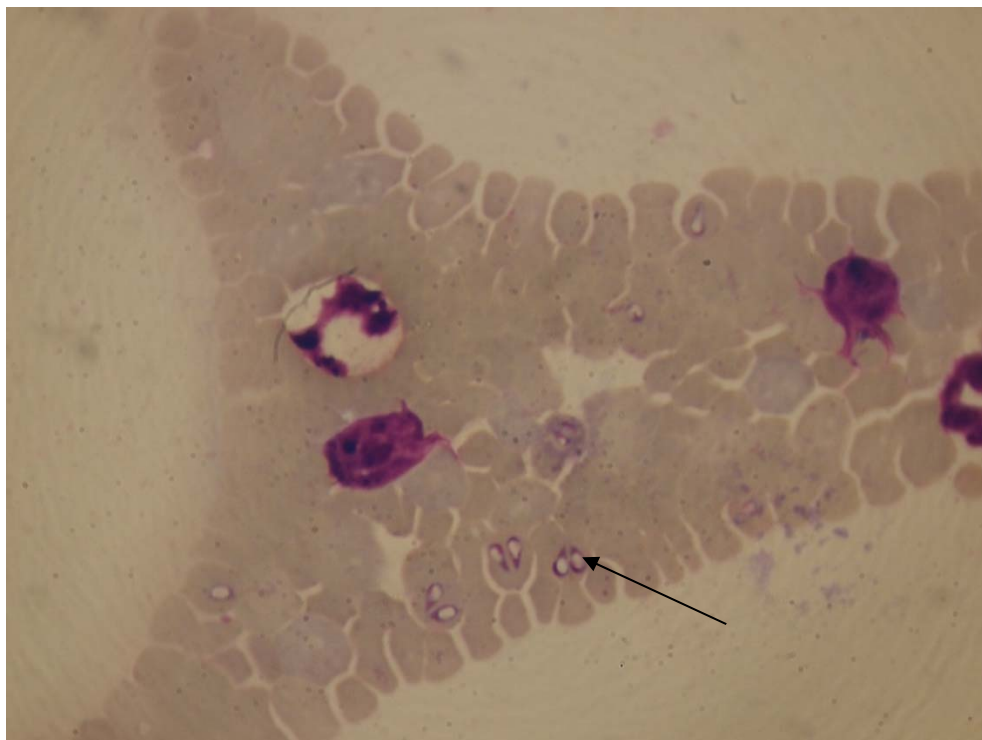
Biochemical, haematological and microscopic analysis of blood & Serum Samples



Diagnosis of Skin Diseases by Skin Scrapings



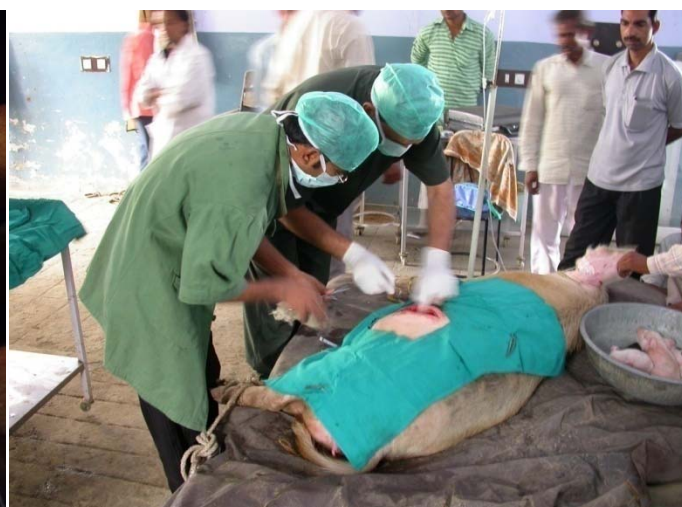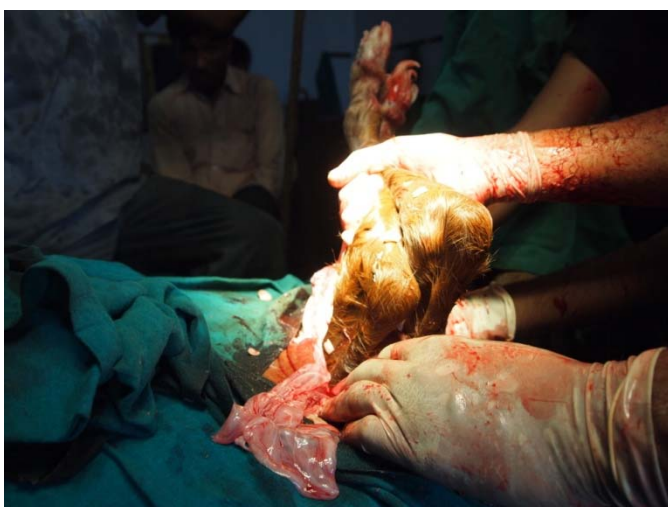Microscopic image of *Babesia Bigemina*



Examination of the animals during OPD at Veterinary Unit, Uchani, Karnal



Caesarean Section of mare in left and Sow in right



Surgical correction of Oesophageal Obstruction in buffalo

